



## Case Report



# Primary Mucosal Melanoma of the Penile Urethra: A Case Report of an Extremely Rare Disease with a Unique Molecular Profile

Suzanne J. Tintle<sup>1</sup>, Travis Vandergriff<sup>1,2</sup> and Liwei Jia<sup>1\*</sup>

<sup>1</sup>Department of Pathology, University of Texas Southwestern Medical Center, Dallas, TX, USA; <sup>2</sup>Department of Dermatology, University of Texas Southwestern Medical Center, Dallas, TX, USA

Received: January 15, 2023 | Revised: February 12, 2023 | Accepted: March 1, 2023 | Published online: March 16, 2023

### Abstract

Primary melanomas of the penis are extremely rare, accounting for 0.18% of all melanomas and less than 2% of all primary penile malignancies. We present a case of primary mucosal melanoma of the penile urethra in an 82-year-old man. His partial penectomy revealed sheets of spindling and epithelioid tumor cells with pale eosinophilic granular cytoplasm and indistinct cell borders, which invaded into the corpus spongiosum. Multi-foci of melanoma in situ were identified at the mucosal surface of the urethra meatus. Both positron emission tomography (PET) and magnetic resonance imaging (MRI) scan one month after the partial penectomy showed no evidence of metastatic disease. Five months later, an F18-fluorodeoxyglucose-PET/computed tomography scan demonstrated mildly increased F18-fluorodeoxyglucose avidity along the ventral penis and a marked avidity of a right inguinal lymph node. Subsequent excision confirmed an ulcerated melanoma and a metastatic melanoma in one inguinal lymph node, respectively. Molecular analysis revealed a unique *BRAF* c.1780G>A mutation, resulting in the D594N alteration, which is the first report in penile urethral melanoma. The patient was miserable from the first infusion of immunotherapy (Keytruda), and a PET scan showed that the tumor continued to grow, with extensive metastatic pulmonary disease leading to massive pleural effusion. Unfortunately, the patient died of disease 18 months after his first presentation.

**Citation of this article:** Tintle SJ, Vandergriff T, Jia L. Primary Mucosal Melanoma of the Penile Urethra: A Case Report of an Extremely Rare Disease with a Unique Molecular Profile. *J Clin Transl Pathol* 2023;3(1):43–48. doi: 10.14218/JCTP.2023.00001.

### Introduction

Primary melanomas of the penis are extremely rare, ac-

counting for an estimated 0.18% of all melanomas and less than 2% of all primary penile malignancies.<sup>1,2</sup> In the United Kingdom there were 58 patients with penile melanoma in a 10-year period compared with 3,193 penile squamous cell carcinomas, with an incidence of 2.4 cases per 10,000,000 men per year.<sup>3</sup> It mainly occurs in elderly men in their sixth and seventh decades of life.<sup>4</sup> Penile melanoma may arise from the epidermis (glans or shaft) or mucosa (meatus, distal urethra, or prepuce), more than half of which arise from the glans penis (55%), followed by the foreskin (28%), penile shaft (9%), and urethral meatus (8%).<sup>2,5</sup> Clinically, lesions typically present as pigmented, occasionally ulcerated, macules, papules, or plaques with an irregular border. Patients with melanoma of the distal urethra or meatus may present with hematuria. The disease at an advanced stage is commonly seen, which may be partly attributed to delayed recognition, and thus a late diagnosis.<sup>6</sup> The prognosis of penile melanoma is dismal, particularly in patients with ulcerated melanomas, a Breslow depth of 3.5 mm or greater, or a diameter greater than 15 mm. The stage is the most important prognostic factor impacting disease-free survival. The 2- and 5-year survival rates are reported as 61% and 20%, respectively.<sup>3</sup>

In contrast to cutaneous sun-exposed melanomas, the v-Raf murine sarcoma viral oncogene homolog B1 (*BRAF*) V600E being the most common pathogenic mutation, mucosal and anogenital melanomas usually lack *BRAF* mutations and harbor *KIT* alterations. However, to the best of our knowledge, neither *KIT* mutations nor the *BRAF* V600E mutation have been reported in primary penile melanomas.<sup>3,7</sup> Only one case of female urethral melanoma has shown a *BRAF* non-V600E mutation (D594G).<sup>8</sup> Here, we present a case of primary penile urethral melanoma in an 82-year-old man with early local recurrence and inguinal lymph node metastasis 6 months after his initial surgery. The melanoma harbored a unique *BRAF* c.1780G>A mutation, resulting in the D594N alteration, and was negative for *c-KIT* and neuroblastoma ras viral oncogene homolog (*NRAS*) mutations. He died of disease 18 months after his first presentation due to rapid tumor progression.

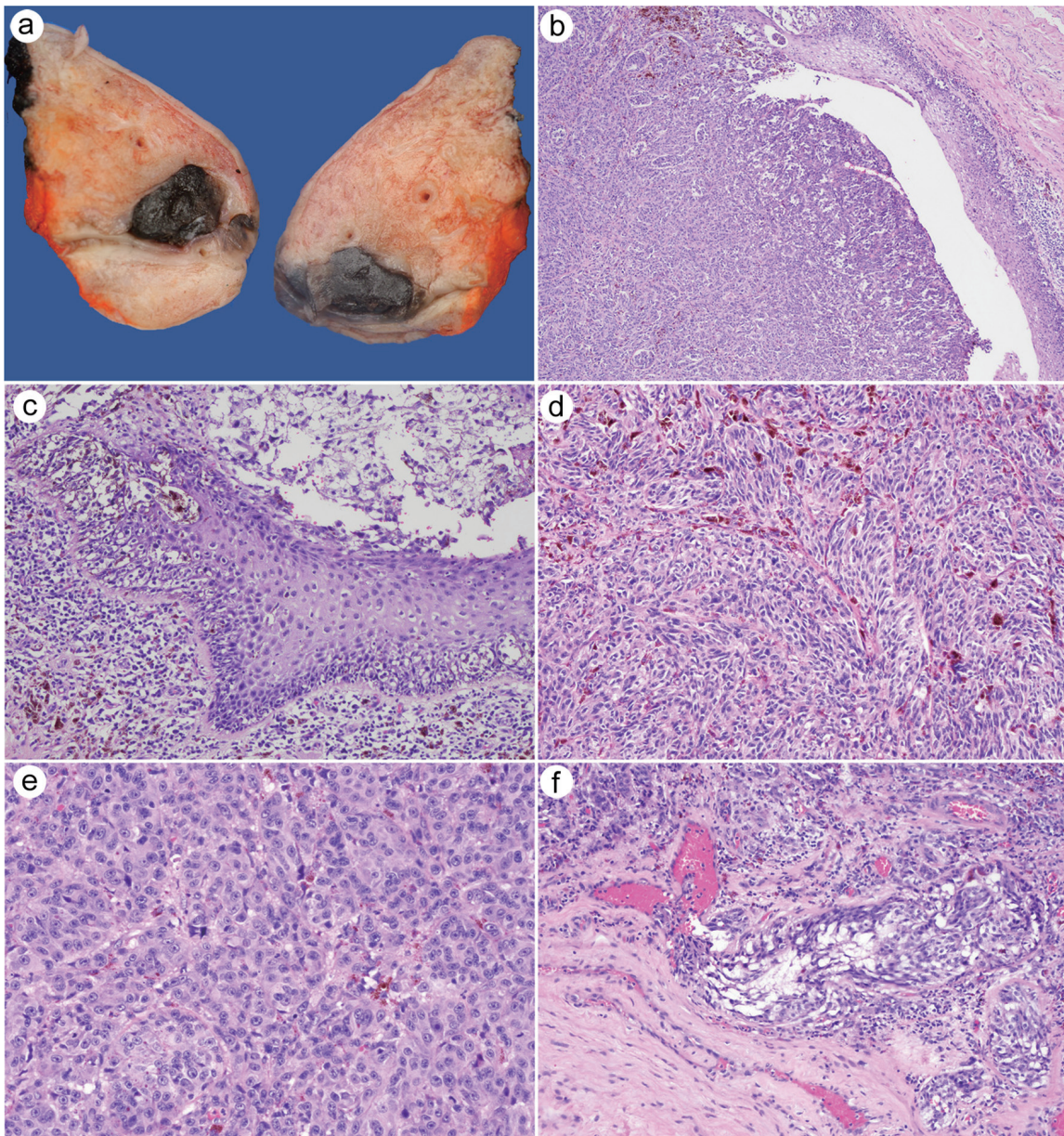
### Case report

An 82-year-old man with a history of coronary artery disease and noninvasive low-grade papillary urothelial carci-

**Keywords:** Mucosal melanoma; Penis, Urethra; *BRAF* mutation; Molecular.

**Abbreviations:** *BRAF*, v-raf murine sarcoma viral oncogene homolog B1; MRI, magnetic resonance imaging; *NRAS*, neuroblastoma RAS viral oncogene homolog; PET, positron emission tomography.

\***Correspondence to:** Liwei Jia, Department of Pathology, University of Texas Southwestern Medical Center, 6201 Harry Hines Blvd., Dallas, TX 75390. ORCID: <https://orcid.org/0000-0002-2118-6428>. Tel: +1 214-633-6355. E-mail: [Liwei.Jia@UTSouthwestern.edu](mailto:Liwei.Jia@UTSouthwestern.edu)

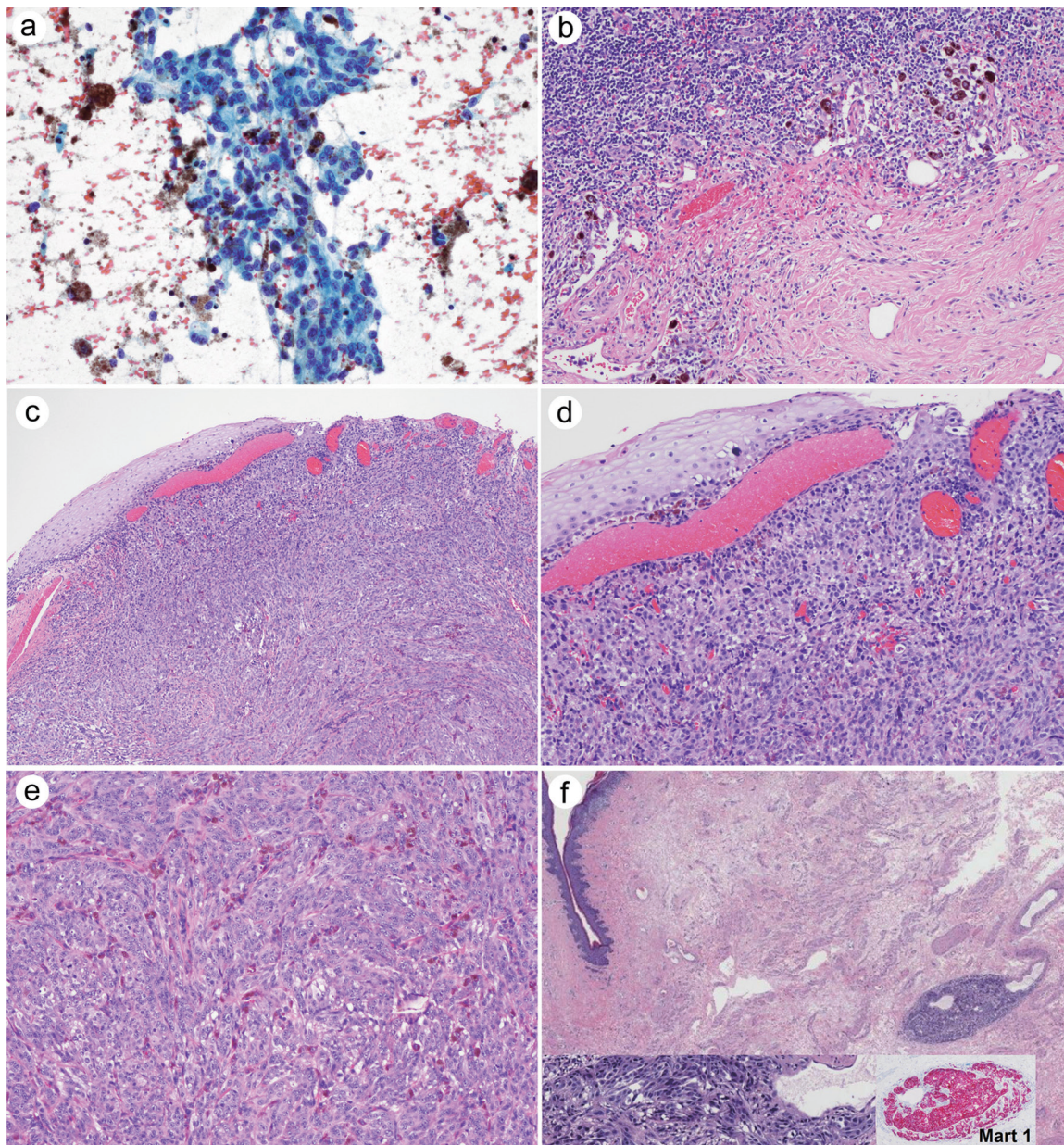


**Fig. 1. Images of the partial penectomy specimen.** The tumor grossly showed a dark, well-demarcated cut surface and was located at the penile urethral meatus (a), which was confirmed microscopically (b, 40× magnification). Melanoma in situ was identified (c, 100× magnification). A sheet or nests of tumor cells exhibited a spindled and epithelioid appearance and intermixed with deep brown pigmentation (d and e, 100× magnification). Lymphovascular invasion was seen (f, 100× magnification).

noma was evaluated for a slightly raised, well-demarcated, homogeneously dark-brown plaque with irregular borders at the penile urethral meatus. An excisional biopsy, which was performed at another hospital, showed a melanoma in situ, extending to the lateral margin. However, the dermatologist was concerned about an invasive disease and recommended a partial penectomy. His partial penectomy specimen grossly showed a dark mass located at the penile urethra, measuring 1.7 cm in the greatest dimension (Fig. 1a, b). Histological examination revealed sheets of spindling and epithelioid tumor cells with pale eosinophilic granular cytoplasm and indistinct cell borders (Fig. 1c–e) invading into the corpus spongiosum. Significant intra- and extracytoplasmic dark brown pigmentations were present. Multi-

ple foci of melanoma in situ were identified at the mucosal surface of the urethra meatus (Fig. 1c). Lymphovascular (Fig. 1f) and perineural invasion were obvious. Mitotic figures were readily observed, with a rate of 6 mitoses/mm<sup>2</sup>. Penectomy surgical margins were negative. Both positron emission tomography (PET) and magnetic resonance imaging scan one month after the partial penectomy showed no evidence of metastatic disease. However, another surveillance of an F18-fluorodeoxyglucose-PET/computed tomography scan five months later demonstrated mildly increased F18-fluorodeoxyglucose avidity along the ventral penis without a discrete lesion and a marked avidity of a right inguinal lymph node, which was suspicious for metastasis. A subsequent physical examination revealed a new 5-mm





**Fig. 2. Images of the metastatic lymph node and recurrent melanoma specimen.** A fine-needle aspiration of the inguinal lymph node showed numerous clusters of atypical cells with abundant pale cytoplasm and enlarged nuclei with irregular nuclear contours and hyperchromasia (a, 100× magnification). An inguinal lymph node showed metastatic melanoma, with extranodal extension and partial tumor regression-related changes (b, 40× magnification). Excision of the new distal penile shaft lesion demonstrated an ulcerated melanoma extending to the base of the specimen (c, 40× magnification), without melanoma in situ (d, 100× magnification). A sheet or nests of tumor cells exhibited a spindled and epithelioid appearance intermixed with deep brown pigmentation (e, 100× magnification). In transit melanoma was identified (f, 20× magnification), showing a similar morphology and supported by Mart-1 immunohistochemical (insets in f, 400× magnification).

ulcerated, pigmented lesion on the distal penile shaft, which prompted a fine-needle aspiration of the inguinal lymph node, revealing numerous clusters of atypical cells with abundant pale cytoplasm and enlarged nuclei with irregular nuclear contours and hyperchromasia (Fig. 2a). Significant dark brown pigmentations were present in the background as well. Subsequently, an inguinal lymph node dissection was performed and confirmed metastatic melanoma in one of eight inguinal lymph nodes, with extranodal extension and partial tumor regression-related changes (Fig. 2b). Simultaneous excision of the new distal penile shaft lesion

demonstrated an ulcerated melanoma extending to the base of the specimen (Fig. 2c-f). The tumor cells showed patchy CD117 immunoreactivity and were negative for BRAFV600E by immunohistochemistry, while later molecular analysis via multiplex polymerase chain reaction revealed a *BRAF* c.1780G>A mutation, resulting in the D594N alteration, and no *c-KIT* or *NRAS* mutations were detected. The one-month follow-up PET/magnetic resonance imaging scan showed no evidence of recurrent disease. Immunotherapy (Keytruda) was administered. However, the patient was miserable from the first infusion. Another PET scan showed that the tumor



continued to grow and that there was extensive metastatic pulmonary disease, leading to massive pleural effusion. Unfortunately, the patient died of disease 18 months after his first presentation.

## Discussion

Primary melanoma of the penis is rare, accounting for only 0.1-0.2% of all extracutaneous, extraocular melanomas,<sup>6,9</sup> and may arise from the epidermis or mucosa, which may be difficult but is important to distinguish both clinically and histologically.<sup>6</sup> Primary mucosal melanomas of the penile urethra are exceedingly rare, and only sparse cases have been reported in case reports or small series; they are most commonly located at the distal urethra, including the fossa navicularis and urethral meatus.<sup>6,10</sup> In our case, melanoma was located at the urethral meatus, with multiple foci of melanoma in situ identified at the mucosal surface of the urethra meatus, which was consistent with primary mucosal melanoma of the penile urethra. Published data on primary penile mucosal melanomas are sparse. A Dutch study of 66 patients in 2007 with primary mucosal penile melanoma, including 19 Dutch patients and 47 patients from the literature, concluded no significant effect on survival with a comparable tumor thickness, and the overall 2- and 5-year survival rates were 63% and 31%, respectively.<sup>6</sup> Similarly, the estimated 5-year cancer-specific survival rate was 45% based on 31 patients with primary urethral melanomas, including only two males diagnosed at Memorial Sloan Kettering Cancer Center from 1986 to 2017.<sup>11</sup> All patients with nodal and/or distant metastases at presentation in the Dutch study died within 2 years.<sup>6</sup> Our patient quickly developed local recurrence and regional metastasis and died of disease 18 months after his first presentation.

Melanomas of nonsun-exposed sites as a group, including mucosal membranes, exhibit distinct clinicopathological and molecular characteristics. Patients with melanoma of sun-protected locations are more likely to have older age of onset, and the tumor usually shows a broad radial growth phase with prominent lentiginous growth as well as the lack of a precursor nevus.<sup>12</sup> Most patients with urethral melanomas are women, 60% in a total of 150 reported patients<sup>13</sup> and 84% in a Surveillance, Epidemiology, and End Results (SEER)-based study.<sup>14</sup> Furthermore, molecular analysis of melanomas from nonsun-exposed areas displays unique molecular alterations from those of sun-exposed sites. A lower overall mutational burden but a higher number of chromosomal aberrations was seen in mucosal melanomas compared to their cutaneous counterpart.<sup>15,16</sup> A *BRAF* mutation has been rarely found in mucosal melanomas (0-11% of patients),<sup>17,18</sup> whereas it has been seen in ~50% of cutaneous melanomas, among which the *BRAF* V600E mutation was indicated as the most recurrent and therapeutically best-targetable gene alteration. In 31 patients with urethral melanomas treated at Memorial Sloan Kettering Cancer Center from 1986 to 2017, *BRAF* mutations were absent; however, a higher frequency of *TP53* mutations compared to cutaneous and vulvar/vaginal melanomas using the Memorial Sloan Kettering sequencing platform (MSK-IMPACT) and polymerase chain reaction-based sequencing of specific hotspots in *BRAF*, *KIT*, and/or *NRAS* was observed.<sup>11</sup> A study of 24 female patients with urogenital tract melanomas from the Netherlands revealed more prevalent *NRAS* mutations (4/24, 21%) than *KIT* mutations (1/24, 4%) as well as the absence of *BRAF* mutations by Sanger sequencing analysis for the detection of oncogenic mutations in exons 9, 11, 13, and 17 of *KIT*, exons 2 and 3 of *NRAS*, and exon 15 of *BRAF*.<sup>19</sup> In primary penile melano-

mas, neither *KIT* nor *BRAF* mutations have been reported,<sup>3,7</sup> and only one case of female urethral melanoma has shown a *BRAF* non-V600E mutation (D594G).<sup>8</sup> Meanwhile, in their study of five penile melanomas located on the glans penis or between the glans penis and prepuce, Omholt *et al.* showed that one patient had a *BRAF* c.A1781G mutation resulting in D594G, one patient had *KIT* c.1722insACA, 1723\_1731del9 mutations, and one patient had an *NRAS* c.G38A mutation.<sup>7</sup> In contrast, Oxley *et al.* demonstrated that none of the 12 penile melanomas in their study, 3 of which were urethral melanomas, showed either *KIT* or *BRAF* V600E mutations by Sanger sequencing and pyrosequencing, respectively.<sup>3</sup> Our case harbored a unique *BRAF* mutation, c.1780G>A mutation, resulting in the D594N alteration, which is located within the protein kinase domain and leads to impaired *BRAF* kinase activity, subsequently activating Erk signaling through CRAF in cell culture<sup>20</sup> and having a decreased transforming ability compared to wild-type *BRAF* in one of two cell lines in culture.<sup>21</sup> Therefore, D594N is predicted to confer a loss of function to the *BRAF* protein, which is classified as class III *BRAF* mutations. This class of *BRAF*-mutant kinase activity is impaired or dead; and, in contrast to activating *BRAF* mutants, such as *BRAF* V600E, they function in a RAS-dependent manner and are sensitive to ERK-mediated feedback.<sup>20</sup> A recent study has demonstrated that non-V600 *BRAF* mutations confer sensitivity to combined Dabrafenib and Trametinib therapy using lung tumor cell lines.<sup>22</sup> Emerging evidence suggests that colorectal cancer patients with class III *BRAF* mutations may benefit from EGFR blockade in combination with chemotherapy.<sup>23</sup> In a recent study on the clinical significance of kinase-impairing mutations involving *BRAF* codons 594 and 596 (n = 160), the authors concluded that *BRAF* D594/G596-mutated tumors occurred more frequently in mucosal melanomas (53.8%) and that patients with *BRAF* D594/G596 mutations had longer overall survival (OS) times (median OS: 45 months) compared to patients with *BRAF* V600E mutations (n = 752, median OS: 25 months).<sup>24</sup> However, the mucosal sites were not specified; therefore, it is not clear if there was any penile urethral melanoma included in their study. True associations between *BRAF*-mutated melanomas and histologic subtype, tumor behavior, therapeutic prediction, and patient prognosis have not yet been fully established.

*KIT* aberrations are more prevalent among patients with mucosal melanomas, including in the urethra, compared to patients with cutaneous melanomas. In a study of 66 mucosal and acral melanomas, *KIT* alterations were found in 15 of 38 (39%) mucosal melanomas as well as in 10 of 28 (36%) acral melanomas,<sup>25</sup> whereas *NRAS* mutations occurred in approximately 17% of primary mucosal melanomas.<sup>26</sup> Interestingly, oncogenic mutations in *KIT* K642E and N566D were concurrent with amplifications in three primary mucosal melanomas.<sup>25</sup> Another study of 75 mucosal melanomas analyzed using targeted next generation sequencing covering 29 known recurrently mutated genes detected *KIT* and *BRAF* mutations in 7.0% and 8.4% of tumor samples, respectively. In the same study, *NF1* and *RAS* mutations were identified as the most frequent driver alterations, occurring in 18.3% and 16.9% of tumors.<sup>27</sup> However, contrasting data also have been reported. None of 12 patients with penile melanomas in the United Kingdom showed *KIT* mutations.<sup>3</sup> In addition, *KIT* overexpression was observed in approximately 3% of all melanomas,<sup>28</sup> and *KIT* immunoreactivity was seen in *KIT*-mutated and/or -amplified mucosal and acral melanoma.<sup>25,29-31</sup> In our case, patchy positivity of *KIT* expression in tumor cells was seen, despite no *KIT* mutations detected in our patient, which may indicate *KIT* amplification

might be present. However, *KIT* amplification was not tested. To date, there is a paucity of available molecular data for primary penile urethral melanomas.

Clinically, the stage of primary penile melanoma depends on its pathologic stage in combination with evidence for metastatic disease. The most recent edition of the American Joint Committee on Cancer includes the following unfavorable histologic prognostic features: increasing diameter of the tumor, lymph node and distant metastases, in-transit or microsatellite deposits, increasing Breslow depth, ulceration, lymphovascular invasion, and increasing mitotic rate.<sup>6,32</sup> Some authors have reported that in penile melanoma, tumor diameters of up to 15 mm may be of clinical prognostic importance.<sup>6</sup> Moreover, the presence of tumor-infiltrating lymphocytes appears to be associated with a favorable prognosis.<sup>28</sup> In order to evaluate the extent of tumor involvement prior to surgical treatment, a 2020 review by a consensus group in the United Kingdom proposes that the staging includes magnetic resonance imaging of a pharmacologically induced erect penis to detect the proximity of the lesion to the distal corpus cavernosum as well as cysto-urethroscopy if there is urethral or per-meatal involvement.<sup>10</sup> Given the rarity of urogenital melanomas, particularly primary penile urethral melanoma, there is limited evidence-based medicine to guide the management of patients. Surgical excision (wide local excision, partial or total penectomy, depending on the size and depth of the lesion) is the initial treatment of choice. Unfortunately, wide excision often comes with a significant impairment on the patient's quality of life.

Therapeutically, the role of adjuvant immunotherapy in cases of metastatic disease is unclear. Although recent advances in the treatment of advanced cutaneous melanoma using checkpoint inhibitors (e.g., anti-CTLA-4 or anti-PD-1 antibodies) have greatly improved patient prognosis, the efficacy of these medications in mucosal melanomas is not known. A large 2018 study of 229 patients with metastatic mucosal melanoma found that the response rates of mucosal melanoma to immunotherapy were, on average, slightly lower than that to chemotherapy (11.9% vs. 14.1%, respectively).<sup>9</sup> However, the overall survival of patients treated with immunotherapy was longer than that of patients treated with chemotherapy (15.9 months vs. 8.82 months, respectively).<sup>9</sup> Furthermore, there is at least one report of the successful use of the *KIT* inhibitor imatinib in a patient with metastatic penile melanoma with double *KIT*-mutated disease.<sup>10</sup> These data suggest a potential role for immunotherapy in the management of metastatic mucosal melanoma.

## Conclusion

In summary, we report a case of an extremely rare primary penile urethral melanoma in an 82-year-old man harboring the *BRAF* c.1780G>A mutation, resulting in the D594N alteration, by multiplex polymerase chain reaction. This patient had a dismal prognosis. More research on the clinicopathological and molecular features of primary mucosal melanoma of the penile urethra, a rare but aggressive form of mucosal melanoma, is needed to determine the outcomes and best practices for management.

## Acknowledgments

None.

## Funding

None.

## Conflict of interest

The authors have no conflicts of interest to disclose.

## Author contributions

Designing the research study (ST, LJ), collecting the data (ST, TV, LJ), writing the manuscript (ST, LJ), critically reviewing and revising the manuscript (LJ).

## Ethical statement

This study received ethical approval from the Institutional Review Board of the University of Texas Southwestern Medical Center and was performed in accordance with the Declaration of Helsinki (as revised in 2013). A written informed consent was obtained from a family member of the patient for publication of this case report.

## References

- [1] Stillwell TJ, Zincke H, Gaffey TA, Woods JE. Malignant melanoma of the penis. *J Urol* 1988;140(1):72-75. doi:10.1016/s0022-5347(17)41490-x, PMID:3379702.
- [2] Bechara GR, Schwindt AB, Ornellas AA, Silva DE, Lott FM, Campos FS. Penile primary melanoma: analysis of 6 patients treated at Brazilian National Cancer Institute in the last eight years. *Int Braz J Urol* 2013;39(6):823-831. doi:10.1590/S1677-5538.IBJU.2013.06.08, PMID:24456774.
- [3] Oxley JD, Corbishley C, Down L, Watkin N, Dickerson D, Wong NA. Clinicopathological and molecular study of penile melanoma. *J Clin Pathol* 2012; 65(3):228-231. doi:10.1136/jclinpath-2011-200344, PMID:22011445.
- [4] Sanchez-Ortiz R, Huang SF, Tamboli P, Prieto VG, Hester G, Pettaway CA. Melanoma of the penis, scrotum and male urethra: a 40-year single institution experience. *J Urol* 2005;173(6):1958-1965. doi:10.1097/01.ju.0000159207.91737.53, PMID:15879790.
- [5] Demitsu T, Nagato H, Nishimaki K, Okada O, Kubota T, Yoneda K, *et al*. Melanoma in situ of the penis. *J Am Acad Dermatol* 2000;42(2 Pt 2):386-388. doi:10.1016/s0190-9622(00)90120-8, PMID:10640941.
- [6] van Geel AN, den Bakker MA, Kirkels W, Horenblas S, Kroon BB, de Wilt JH, *et al*. Prognosis of primary mucosal penile melanoma: a series of 19 Dutch patients and 47 patients from the literature. *Urology* 2007;70(1):143-147. doi:10.1016/j.urology.2007.03.039, PMID:17656225.
- [7] Omholt K, Grafstrom E, Kanter-Lewensohn L, Hansson J, Ragnarsson-Olding BK. *KIT* pathway alterations in mucosal melanomas of the vulva and other sites. *Clin Cancer Res* 2011;17(12):3933-3942. doi:10.1158/1078-0432.CCR-10-2917, PMID:21680547.
- [8] Zarei S, Voss JS, Jin L, Jenkins SM, Bryce AH, Erickson LA, *et al*. Mutational Profile in Vulvar, Vaginal, and Urethral Melanomas: Review of 37 Cases With Focus on Primary Tumor Site. *Int J Gynecol Pathol* 2020;39(6):587-594. doi:10.1097/PGP.0000000000000636, PMID:31567539.
- [9] Brady KL, Mercurio MG, Brown MD. Malignant tumors of the penis. *Dermatol Surg* 2013;39(4):527-547. doi:10.1111/dsu.12029, PMID:23164051.
- [10] Smith HG, Bagwan I, Board RE, Capper S, Coupland SE, Glen J, *et al*. Ano-uro-genital mucosal melanoma UK national guidelines. *Eur J Cancer* 2020;135:22-30. doi:10.1016/j.ejca.2020.04.030, PMID:32531566.
- [11] Mano R, Hoeh B, DiNatale RG, Sanchez A, Benfante NE, Reznik E, *et al*. Urethral Melanoma - Clinical, Pathological and Molecular Characteristics. *Bladder Cancer* 2022;8(3):291-301. doi:10.3233/BLC-211633, PMID:36277327.
- [12] Manolidis S, Donald PJ. Malignant mucosal melanoma of the head and neck: review of the literature and report of 14 patients. *Cancer* 1997;80(8):1373-1386. doi:10.1002/(sici)1097-0142(19971015)80:8<1373::aid-cnrc3>3.0.co;2-g, PMID:9338460.
- [13] El-Safadi S, Estel R, Maysner P, Muenstedt K. Primary malignant melanoma of the urethra: a systematic analysis of the current literature. *Arch Gynecol Obstet* 2014;289(5):935-943. doi:10.1007/s00404-013-3130-3, PMID:24370958.
- [14] Sanchez A, Rodriguez D, Allard CB, Bechis SK, Sullivan RJ, Boeke CE, *et al*. Primary genitourinary melanoma: Epidemiology and disease-specific survival in a large population-based cohort. *Urol Oncol* 2016;34(4):166.e167-114. doi:10.1016/j.urolonc.2015.11.009, PMID:26739672.
- [15] Furney SJ, Turajlic S, Stamp G, Nohadani M, Carlisle A, Thomas JM, *et al*. Genome sequencing of mucosal melanomas reveals that they are driven by distinct mechanisms from cutaneous melanoma. *J Pathol* 2013;230(3):261-269. doi:10.1002/path.4204, PMID:23620124.
- [16] Curtin JA, Fridlyand J, Kageshita T, Patel HN, Busam KJ, Kutzner H, *et al*. Distinct sets of genetic alterations in melanoma. *N Engl J Med* 2005;353(20):2135-2147. doi:10.1056/NEJMoa050092, PMID:16291983.
- [17] Davies H, Bignell GR, Cox C, Stephens P, Edkins S, Clegg S, *et al*. Mutations of the *BRAF* gene in human cancer. *Nature* 2002;417(6892):949-954. doi:10.1038/nature00766, PMID:12068308.
- [18] Tacastacas JD, Bray J, Cohen YK, Arbesman J, Kim J, Koon HB, *et al*. Update on primary mucosal melanoma. *J Am Acad Dermatol* 2014;71(2):366-375. doi:10.1016/j.jaad.2014.03.031, PMID:24815565.
- [19] van Engen-van Grunsven AC, Kusters-Vandeveldt HV, De Hullu J, van Duijn

- LM, Rijntjes J, Bovee JV, *et al*. NRAS mutations are more prevalent than KIT mutations in melanoma of the female urogenital tract—a study of 24 cases from the Netherlands. *Gynecol Oncol* 2014;134(1):10–14. doi:10.1016/j.ygyno.2014.04.056, PMID:24802725.
- [20] Yao Z, Yaeger R, Rodrik-Outmezguine VS, Tao A, Torres NM, Chang MT, *et al*. Tumours with class 3 BRAF mutants are sensitive to the inhibition of activated RAS. *Nature* 2017;548(7666):234–238. doi:10.1038/nature23291, PMID:28783719.
- [21] Ng PK, Li J, Jeong KJ, Shao S, Chen H, Tsang YH, *et al*. Systematic Functional Annotation of Somatic Mutations in Cancer. *Cancer Cell* 2018;33(3):450–462.e410. doi:10.1016/j.ccell.2018.01.021, PMID:29533785.
- [22] Noeparast A, Teugels E, Giron P, Verschelden G, De Brakeleer S, Decoster L, *et al*. Non-V600 BRAF mutations recurrently found in lung cancer predict sensitivity to the combination of Trametinib and Dabrafenib. *Oncotarget* 2017;8(36):60094–60108. doi:10.18632/oncotarget.11635, PMID:28947956.
- [23] Yaeger R, Kotani D, Mondaca S, Parikh AR, Bando H, Van Seventer EE, *et al*. Response to Anti-EGFR Therapy in Patients with BRAF non-V600-Mutant Metastatic Colorectal Cancer. *Clin Cancer Res* 2019;25(23):7089–7097. doi:10.1158/1078-0432.CCR-19-2004, PMID:31515458.
- [24] Wu X, Yan J, Dai J, Ma M, Tang H, Yu J, *et al*. Mutations in BRAF codons 594 and 596 predict good prognosis in melanoma. *Oncol Lett* 2017;14(3):3601–3605. doi:10.3892/ol.2017.6608, PMID:28927118.
- [25] Curtin JA, Busam K, Pinkel D, Bastian BC. Somatic activation of KIT in distinct subtypes of melanoma. *J Clin Oncol* 2006;24(26):4340–4346. doi:10.1200/JCO.2006.06.2984, PMID:16908931.
- [26] Cosgarea I, Ugurel S, Sucker A, Livingstone E. Targeted next generation sequencing of mucosal melanomas identifies frequent NF1 and RAS mutations. *Oncotarget* 2017;8(25):40683–40692. doi:10.18632/oncotarget.16542.
- [27] Cosgarea I, Ugurel S, Sucker A, Livingstone E, Zimmer L, Ziemer M, *et al*. Targeted next generation sequencing of mucosal melanomas identifies frequent NF1 and RAS mutations. *Oncotarget* 2017;8(25):40683–40692. doi:10.18632/oncotarget.16542, PMID:28380455.
- [28] Patterson J. *Weedon's Skin Pathology*, 5th Edition ed. Elsevier; 2019:839–901.
- [29] Satzger I, Schaefer T, Kuettler U, Broecker V, Voelker B, Ostertag H, *et al*. Analysis of c-KIT expression and KIT gene mutation in human mucosal melanomas. *Br J Cancer* 2008;99(12):2065–2069. doi:10.1038/sj.bjc.6604791, PMID:19018266.
- [30] Torres-Cabala CA, Wang WL, Trent J, Yang D, Chen S, Galbinca J, *et al*. Correlation between KIT expression and KIT mutation in melanoma: a study of 173 cases with emphasis on the acral-lentiginous/mucosal type. *Mod Pathol* 2009;22(11):1446–1456. doi:10.1038/modpathol.2009.116, PMID:19718013.
- [31] Beadling C, Jacobson-Dunlop E, Hodi FS, Le C, Warrick A, Patterson J, *et al*. KIT gene mutations and copy number in melanoma subtypes. *Clin Cancer Res* 2008;14(21):6821–6828. doi:10.1158/1078-0432.CCR-08-0575, PMID:18980976.
- [32] Gershenwald JE, Scolyer RA. Melanoma Staging: American Joint Committee on Cancer (AJCC) 8th Edition and Beyond. *Ann Surg Oncol* 2018;25(8):2105–2110. doi:10.1245/s10434-018-6513-7, PMID:29850954.