



Review Article

HMGA2: A Biomarker in Gynecologic Neoplasia



Jian-Jun Wei*

Department of Pathology, Northwestern University, School of Medicine, Chicago, IL, USA

Received: December 14, 2021 | Revised: January 10, 2022 | Accepted: January 15, 2022 | Published: January 27, 2022

Abstract

High Mobility Group A2 gene (HMGA2), an oncofetal protein, is normally expressed in fetal development and completely shuts down in almost all organs and tissue types during adulthood. It is upregulated or overexpressed again in certain mesenchymal neoplasms due to chromosomal translocations and in malignant epithelial tumors through transcription regulation. HMGA2 overexpression can either drive tumor development or promote the aggressiveness of tumor growth. Many gynecologic neoplasms, including uterine smooth muscle tumors and ovarian cancer, are associated with HMGA2 overexpression. In this article, we review recent developments in the study of HMGA2 and its expression as a potential biomarker for gynecologic neoplasms and clinic application.

Citation of this article: Wei JJ. HMGA2: A Biomarker in Gynecologic Neoplasia. J Clin Transl Pathol 2022;2(1):3–7. doi: 10.14218/JCTP.2021.00018.

Introduction

High Mobility Group A2 gene (HMGA2), located on chromosome 12q15, was discovered as a nuclear protein that appears upregulated after transformation of rat thyroid cells by retrovirus in 1985.¹ Human HMGA2 consists of five exons in an over 160 kb genomic region and contains a large intronic sequence (>140 kb) between exons 3 and 4. The major transcript of HMGA2a is a 4.1 kb mRNA that translates to a 108 amino acid HMGA2 protein. The first three exons encode three AT-hook domains, which play a very important role in transcriptional regulation. Exon 4 encodes 12 amino acids that separate the AT-hooks from the C-terminal amino acid domain, which is encoded by exon 5. The acidic tail is involved in protein-protein interaction.²

HMGA2 is overexpressed in embryonic tissue but is absent in almost all normal adult tissues and terminally differentiated tissues.^{3,4} HMGA2 overexpression in human neo-

plasm was originally identified in mesenchymal tumors by positional cloning due to non-random chromosomal translocations at the 12q15 region.^{5–11} HMGA2 functions as an architectural transcription factor that can regulate multiple downstream genes. However, the role of HMGA2 in regulating the molecular pathways responsible for tumorigenesis and tumor progression is only partially understood. The oncogenic functions of HMGA2 for neoplasia were identified through the observation of mouse models.¹² Specifically, transgenic mice carrying the full-length Hmga2 gene developed pituitary adenomas,¹³ while transgenic mice carrying the human HMGA2 transcript under the control of an adipocyte-specific promoter developed breast fibroadenomas and salivary gland adenomas.¹⁴ Another study reported that introducing HMGA2 overexpression in normal ovarian surface epithelial cells resulted in malignant transformation and tumor formation.¹⁵ Several biological processes involving HMGA2 include cell proliferation,¹⁶ stem cell self-renewal,¹⁷ cell transformation,² epithelial-to-mesenchymal transition (EMT),^{18,19} tumor invasion and metastasis,²⁰ and DNA damage repair.²¹ In addition, HMGA2 overexpression is associated with tumor differentiation,²² unfavorable outcome, and resistance to treatment.^{19,23}

As an oncofetal protein, HMGA2 overexpression is present in many epithelial and mesenchymal neoplasms and plays an important role in the tumorigenesis of both mesenchymal and epithelial neoplasms. In this short review, we briefly summarize HMGA2 as a biomarker in the diagnosis and prognosis of gynecologic neoplasms.

HMGA2 in gynecologic mesenchymal tumors

HMGA2 overexpression can be seen in many mesenchymal neoplasms of the head and neck, lungs, bone, breast, and female reproductive and other organ systems.²⁴ The uterine smooth muscle tumors and other mesenchymal neoplasms of gynecologic origin are among the tumors with characteristic molecular and genetic changes leading to HMGA2 overexpression.²¹

Uterine leiomyomas are the most common benign mesenchymal neoplasms in the gynecologic system, and up to 70% of women will develop leiomyomas. While most leiomyomas harbor MED12 mutations,²⁵ about 10–15% of usual type leiomyomas are caused by HMGA2 overexpression.²⁶ Importantly, each leiomyoma is driven by either MED12 or HMGA2, but not by both (mutually exclusive).²⁶ Morton's group was first to identify HMGA2 overexpression in leiomyomas due to non-random chromosome translocation and common gene rearrangement involving t(12;14) translocation.²⁷ Interestingly, the preferential breakpoints in leiomyoma are located at the 5'UTR of HMGA2, resulting in no fusion transcript, which is different from lipomatous

Keywords: HMGA2; Gynecologic neoplasm; Biomarker; Tumorigenesis; Gene function.

Abbreviations: EMT, epithelial-to-mesenchymal transition; FIGO, the International Federation of Gynecology and Obstetrics; HMGA2, High Mobility Group A2 gene; LN, lymph node; LVI, lymphatic vessel invasion; MED12, Mediator Complex Subunit 12; STIC, serous tubal intraepithelial carcinoma; TCGA, The Cancer Genomic Atlas.

***Correspondence to:** Jian-Jun Wei, Department of Pathology, Northwestern University, School of Medicine, Feinberg 7-334, 251 East Huron Street, Chicago, IL 60611, USA. ORCID: <https://orcid.org/0000-0003-0281-2793>. Tel: +1-312-926-1815, Fax: +1-312-926-3127, E-mail: jianjun-wei@northwestern.edu

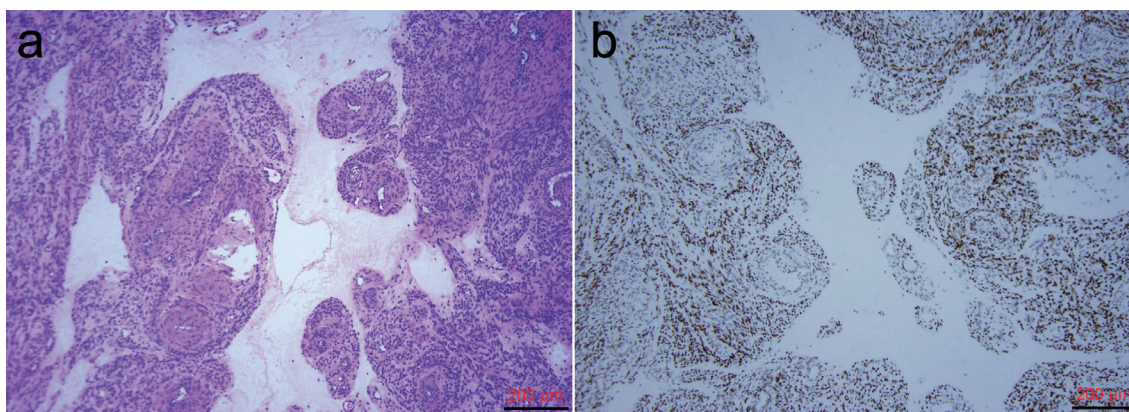


Fig. 1. HMGA2 expression in hydropic leiomyomas. (a) H/E stained slide of hydropic leiomyoma (10×); (b) Immunostain for HMGA2 (10×).

neoplasms at large intron 3.²⁴ Until recently, the association of HMGA2 with specific histologic variants of uterine smooth muscle tumor was largely unknown. Ordulu *et al.* observed that over 58% of intravenous leiomyomatosis harbored HMGA2 overexpression due to gene rearrangement.²⁸

By reviewing the selected cases of leiomyomas with HMGA2 overexpression, we noted that leiomyomas with HMGA2 overexpression exhibit subtle but distinct cytohistologic features, particularly tumor cells with small rounded and oval nuclei with increased vasculature, that differ from MED12 leiomyomas. This prompted us to investigate hydropic leiomyomas, a histologic variant of leiomyoma with the above-mentioned characteristic cytohistologic features. Hydropic leiomyomas are well-demarcated and vaguely nodular to lobulated tumors with white-grey, watery edematous cut surfaces. Microscopically, hydropic leiomyomas are edematous with increased vascularity and tumor cells arranged in nodules or cords. In a prior study, tumor cells displayed round to oval nuclei with a cord-like arrangement and perinodular growth around vessels.²⁹ In an analysis of 24 hydropic leiomyomas, 76% showed HMGA2 overexpression by immunohistochemistry (Fig. 1). In addition, a FISH analysis with a breakpoint fusion probe demonstrated at least 25% of hydropic leiomyoma had gene translocation.³⁰

Myxoid leiomyosarcoma is a rare variant of leiomyosarcomas accounting for 10% of malignant uterine smooth muscle tumors. Diagnosis by histology alone can be made in typical cases, but most cases can be diagnostically challenging due to the bland cytology of myxoid leiomyosarcoma that mimics myxoid leiomyoma, myxoid endometrial stromal sarcoma, myxoid inflammatory myofibroblastic tumors, and other uterine myxoid tumors, NOS.³¹ Interestingly, one study found that 10 out of 10 myxoid leiomyosarcomas have HMGA2 overexpression,³² an observation that was reproducible in our study of 4 myxoid leiomyosarcomas (unpublished data). However, a target RNA sequencing analysis failed to identify HMGA2 gene rearrangement in all 15 myxoid leiomyosarcoma.³³ Therefore, more studies are needed to compare HMGA2 expression in different mesenchymal tumors of the uterus with myxoid features. The conventional spindle cell leiomyosarcoma is considered a genomic unstable tumor with complex genomic alterations.³⁴ In our research, we examined 51 spindle cell leiomyosarcoma and found 14% of them (7/51) were strongly immunoreactive for HMGA2;³⁵ a similar finding was observed in leiomyomas with bizarre nuclei. Additional research is needed to further characterize the role of HMGA2 in leiomyoma development and differentiation. Due to a small case number, the association of HMGA2 with clinical outcome of leiomyosarcoma remains to be established.

Aggressive angiomyxoma is a rare and clinically aggressive tumor that occurs in the soft tissues of the lower genital tract, pelvis, and perineum. Histologically, it presents an infiltrative, hypocellular myxoid lesion with bland spindle cells with round/oval nuclei and prominent variably sized vessels. Tumors usually show an ill-defined border with local recurrence in about 30% of cases. Tumor stroma are myxoid with scattered delicate collagen fibers and broadly extend to fat, nerves, and muscle. Due to a bland histology and the aggressiveness of tumor nature, diagnosis is critical and challenging in certain cases. While most of the biomarkers for fibroblastic lesions may not contribute well to the differential diagnosis of aggressive angiomyxoma, HMGA2 is by far the most sensitive and specific marker that is overexpressed in over 90% of tumors of this type (Fig. 2).³⁶ Therefore, HMGA2 has been broadly used as surrogate marker in evaluation of this tumor type.

HMGA2 overexpression is also observed in several other mesenchymal neoplasms in gynecologic system, including lipoleiomyoma, endometrial polyp, fibroadenoma, and adenosarcoma. Moreover, HMGA2-mediated angiogenesis plays an important role in promoting tumor growth of these mesenchymal neoplasm.³⁷

HMGA2 in GYN epithelial malignancy

HMGA2 overexpression is common in epithelial carcinoma and is mostly caused by altered transcription regulation, rather than gene rearrangement.³⁸ HMGA2 overexpression has been reported in many solitary carcinomas, including but not limited to colorectal, pancreatic biliary, lung, breast, head and neck, and male and female reproductive organ cancer.³⁸ Currently, HMGA2 has been used as a biomarker for the evaluation of the aggressive tumor behavior associated with tumor growth,¹⁶ differentiation,²² unfavorable outcome, and resistance to treatment.^{19,23}

Ovarian/fallopian tube high-grade serous carcinoma is a deadly disease characterized by a short latent phase of early disease, rapid and fast tumor cell proliferation, and wide-spreading disease at the time of diagnosis. Identifying the biomarkers linked to aggressive ovarian cancer may help facilitate patient care and treatment options. Malek *et al.* found that HMGA2 was positive in over 65% of ovarian serous carcinomas but not in normal control tissue.³⁹ Shell *et al.*²² examined HMGA2 expression in 100 primary ovarian cancer cases and found that high expression of HMGA2 was significantly correlated with an adverse prognosis. In a cohort of 117 ovarian cancer cases with well-characterized clinical outcome, we found that in over 70% cases of ovar-

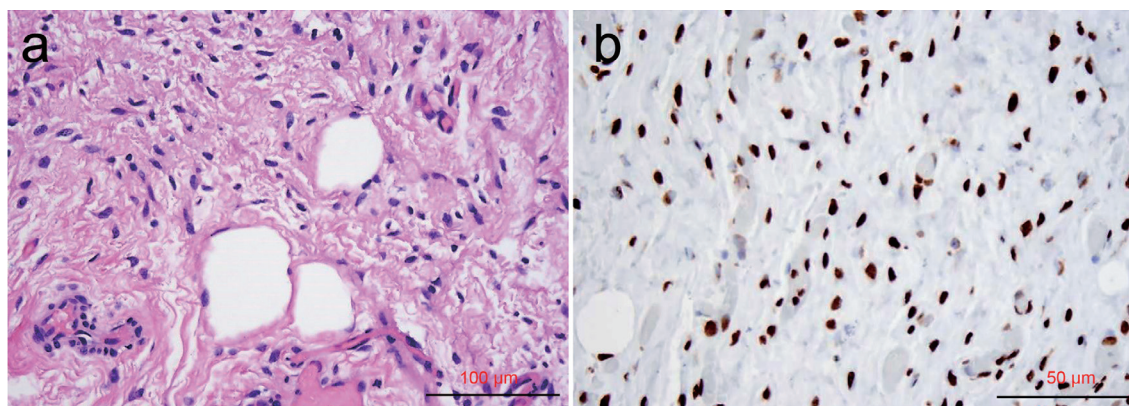


Fig. 2. HMGA2 expression in aggressive angiomyxomas. (a) H/E stained slide of aggressive angiomyxoma (20×); (b) Immunostain for HMGA2 (40×).

ian cancer, most high-grade serous carcinoma exhibited HMGA2 overexpression, and tumors with HMGA2 overexpression were significantly associated with worse clinical outcome.^{40,41} In addition, HMGA2 overexpression is also related to ascites, lymph node (LN) metastasis, and poor clinical outcome.⁴⁰ The aggressiveness of high-grade serous carcinoma in association with HMGA2 overexpression is mostly through its regulation of epithelial mesenchymal transition.²¹ Overall, HMGA2 overexpression is very common in high-grade serous carcinoma (>70%), followed by carcinosarcoma (65%), but is much less common in other histologic types of ovarian cancer.⁴¹ For example, only 7% of low-grade endometrioid carcinomas, 23% of clear cell carcinoma, and 6% of mucinous carcinoma were found to immunoreactive for HMGA2.⁴¹

Recent identification of serous tubal intraepithelial carcinoma (STIC) in the fallopian tube opens a new venue for a better understanding of the tumorigenesis of high-grade serous carcinoma. STIC demonstrates remarkable nuclear atypia along with mutant p53 immunostain patterns. To evaluate the role of HMGA2 as a surrogate biomarker for detection of this precancerous lesion, we examined HMGA2 expression in the normal epithelial cells of fallopian tubes and STIC lesions. Interestingly, HMGA2 showed to be highly overexpressed in STIC lesions, specifically in as many as 75% of STIC cases (Fig. 3), indicating an early event of HMGA2 overexpression in the tumorigenesis of high-grade serous carcinoma.⁴²

According to The Cancer Genomic Atlas (TCGA), high-grade serous carcinomas can be divided into 4 subtypes: Differentiated, Immunoreactive, Mesenchymal, and Proliferative. HMGA2 is one of the gene signatures closely associated with the Proliferative type of serous carcinoma.⁴³ HMGA2 was also one of the top-ranking dysregulated genes identified by genome-wide analysis in primary human ovar-

ian cancer.⁴⁴ All these findings strongly suggest that HMGA2 overexpression plays an important role in high-grade serous carcinoma development and progression and, thus, can be a useful prognostic biomarker for pathology evaluation.

Uterine serous carcinoma has different histologic presentations, immunostain patterns, and molecular profiles than those of ovarian/fallopian tube serous carcinoma.⁴⁵ Although p53 is a useful biomarker for the differential diagnosis of uterine serous carcinoma, many high-grade endometrioid carcinomas can harbor p53 mutations.⁴⁵ In particular, one study showed that over 91% of uterine serous carcinomas have HMGA2 overexpression.⁴⁶ FIGO grade 3 endometrioid and serous carcinomas are considered "high-grade endometrial carcinomas," the diagnosis of which is not highly reproducible due to the question of serous-like endometrioid carcinoma vs p53 alteration. Genomic studies on endometrial cancer consider molecular tumor classification, which separates prognostically favorable from unfavorable types of grade 3 endometrioid carcinomas. As such, combining genomic and FIGO grades has been proposed.⁴⁷ When unavailable for genomic analysis, p53 and MSI immunostains can discriminate some, but not all, grade 3 endometrioid carcinomas. In our recently unpublished study, we found that HMGA2 overexpression is present in more than 75% of uterine serous carcinomas and 45% of grade 3-endometrioid carcinomas. Interestingly, none of the grade 1 endometrioid carcinomas showed HMGA2 overexpression. HMGA2 overexpression was also associated with a higher rate of lymphatic vessel invasion (LVI) and LN metastasis in grade 3 endometrioid carcinoma. This study demonstrates that HMGA2 expression is closely correlated with p53 and with the aggressive histologic features of grade 3 endometrioid carcinoma. The findings suggest that HMGA2 can be a useful marker in discriminating aggressive high-grade carcinoma from low-grade endometrioid carcinoma.

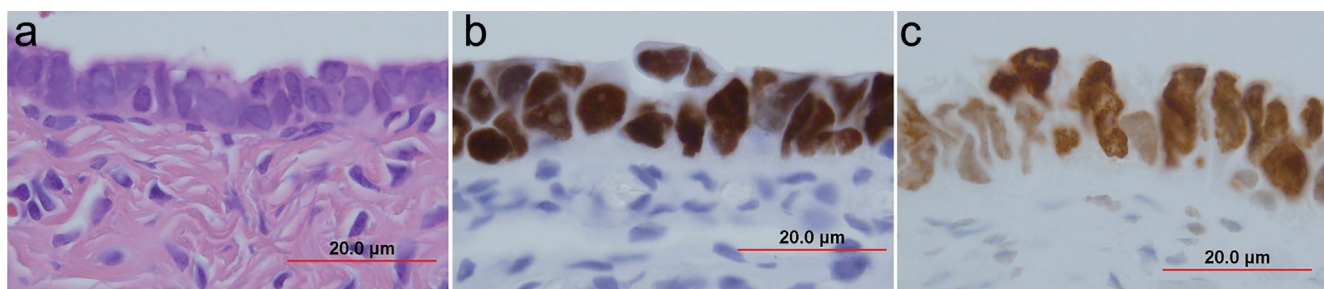


Fig. 3. HMGA2 expression in serous tubal intraepithelial carcinoma (STIC). (a) H/E stained slide of serous tubal intraepithelial carcinoma (STIC) (60×); (b) Immunostain for p53 (60×); (c) Immunostain for HMGA2 (60×).

Conclusions

HMGA2 is an oncofetal protein participating in embryogenesis and tumorigenesis that is upregulated in both epithelial and mesenchymal tissue-originated tumors. HMGA2 overexpression is correlated with distant metastasis, advanced stage tumors, and poor clinical outcome in many solitary carcinomas. As a regulator in AKT and sex-steroid hormone pathways, HMGA2 is a unique oncogene and biomarker in ER/PR positive or associated tumors. Nevertheless, additional studies are needed to further characterize the role of HMGA2 in other tumor types, grades, and differentiation. Most importantly, development of the therapeutic strategies targeting tumors with HMGA2 overexpression will help in treating many deadly neoplasms.

Acknowledgments

We thank those residents and postdoctoral fellows at Northwestern University who previously contributed to our HMGA2 studies. We particularly thank Dr. Debabrata Chakravarti for his support and scientific discussion.

Funding

This study was partially supported by the grant of NIH (P50 HD098580 to WJJ).

Conflict of interest

Dr. Wei has been an editorial board member of *Journal of Clinical and Translational Pathology* since May 2021. The author has no others to disclose.

Author contributions

Dr. Wei was the sole author of this article.

References

- Giancotti V, Berlingieri MT, DiFiore PP, Fusco A, Vecchio G, Crane-Robinson C. Changes in nuclear proteins on transformation of rat epithelial thyroid cells by a murine sarcoma retrovirus. *Cancer Res* 1985;45(12 Pt 1):6051-6057. PMID:2998592.
- Fedele M, Visone R, De Martino I, Troncone G, Palmieri D, Battista S, et al. HMGA2 induces pituitary tumorigenesis by enhancing E2F1 activity. *Cancer Cell* 2006;9(6):459-471. doi:10.1016/j.ccr.2006.04.024. PMID:16766265.
- Hammond SM, Sharpless NE. HMGA2, microRNAs, and stem cell aging. *Cell* 2008;135(6):1013-1016. doi:10.1016/j.cell.2008.11.026. PMID:19070572.
- Pfannkuche K, Summer H, Li O, Hescheler J, Droge P. The high mobility group protein HMGA2: a co-regulator of chromatin structure and pluripotency in stem cells? *Stem Cell Rev* 2009;5(3):224-230. doi:10.1007/s12015-009-9078-9. PMID:19551524.
- Mine N, Kurose K, Konishi H, Araki T, Nagai H, Emi M. Fusion of a sequence from HEI10 (14q11) to the HMGIC gene at 12q15 in a uterine leiomyoma. *Jpn J Cancer Res* 2001;92(2):135-139. doi:10.1111/j.1349-7006.2001.tb01075.x. PMID:11223542.
- Takahashi T, Nagai N, Oda H, Ohama K, Kamada N, Miyagawa K. Evidence for RAD51L/HMGIC fusion in the pathogenesis of uterine leiomyoma. *Genes Chromosomes Cancer* 2001;30(2):196-201. doi:10.1002/1098-2264(2000)999:999<::aid-gcc1078>3.0.co;2-8. PMID:11135437.
- Kurose K, Mine N, Doi D, Ota Y, Yoneyama K, Konishi H, et al. Novel gene fusion of COX6C at 8q22-23 to HMGIC at 12q15 in a uterine leiomyoma. *Genes Chromosomes Cancer* 2000;27(3):303-307. doi:10.1002/(sici)1098-2264(200003)27:3<303::aid-gcc11>3.0.co;2-3. PMID:10679920.
- Schoenmakers EF, Huysmans C, Van de Ven WJ. Allelic knockout of novel splice variants of human recombination repair gene RAD51B in t(12;14) uterine leiomyomas. *Cancer Res* 1999;59(1):19-23. PMID:9892177.
- Kubo T, Matsui Y, Naka N, Araki N, Goto T, Yukata K, et al. Expression of HMGA2-LPP and LPP-HMGA2 fusion genes in lipoma: identification of a novel type of LPP-HMGA2 transcript in four cases. *Anticancer Res* 2009;29(6):2357-2360. PMID:19528502.
- Pierron A, Fernandez C, Saada E, Keslair F, Hery G, Zattara H, et al. HMGA2-NFIB fusion in a pediatric intramuscular lipoma: a novel case of NFIB alteration in a large deep-seated adipocytic tumor. *Cancer Genet Cytogenet* 2009;195(1):66-70. doi:10.1016/j.cancergencyto.2009.06.009. PMID:19837271.
- Petit MM, Schoenmakers EF, Huysmans C, Geurts JM, Mandahl N, Van de Ven WJ. LHFP, a novel translocation partner gene of HMGIC in a lipoma, is a member of a new family of LHFP-like genes. *Genomics* 1999;57(3):438-441. doi:10.1006/geno.1999.5778. PMID:10329012.
- Ashar HR, Chouinard RA Jr, Dokur M, Chada K. In vivo modulation of HMGA2 expression. *Biochim Biophys Acta* 2010;1799(1-2):55-61. doi:10.1016/j.bbagg.2009.11.013. PMID:20123068.
- Fedele M, Battista S, Kenyon L, Baldassarre G, Fidanza V, Klein-Szanto AJ, et al. Overexpression of the HMGA2 gene in transgenic mice leads to the onset of pituitary adenomas. *Oncogene* 2002;21(20):3190-3198. doi:10.1038/sj.onc.1205428. PMID:12082634.
- Zaidi MR, Okada Y, Chada KK. Misexpression of full-length HMGA2 induces benign mesenchymal tumors in mice. *Cancer Res* 2006;66(15):7453-7459. doi:10.1158/0008-5472.CAN-06-0931. PMID:16885341.
- Wu J, Liu Z, Shao C, Gong Y, Hernando E, Lee P, et al. HMGA2 overexpression-induced ovarian surface epithelial transformation is mediated through regulation of EMT genes. *Cancer Res* 2011;71(2):349-359. doi:10.1158/0008-5472.CAN-10-2550. PMID:21224353.
- Peng Y, Laser J, Shi G, Mittal K, Melamed J, Lee P, et al. Antiproliferative effects by Let-7 repression of high-mobility group A2 in uterine leiomyoma. *Mol Cancer Res* 2008;6(4):663-673. doi:10.1158/1541-7786.MCR-07-0370. PMID:18403645.
- Nishino J, Kim I, Chada K, Morrison SJ. Hmga2 promotes neural stem cell self-renewal in young but not old mice by reducing p16Ink4a and p19Arf Expression. *Cell* 2008;135(2):227-239. doi:10.1016/j.cell.2008.09.017. PMID:18957199.
- Thuault S, Tan EJ, Peinado H, Cano A, Heldin CH, Moustakas A. HMGA2 and Smads co-regulate SNAIL1 expression during induction of epithelial-to-mesenchymal transition. *J Biol Chem* 2008;283(48):33437-33446. doi:10.1074/jbc.M802016200. PMID:18832382.
- Tagashira Y, Taniguchi F, Harada T, Ikeda A, Watanabe A, Terakawa N. Interleukin-10 attenuates TNF-alpha-induced interleukin-6 production in endometriotic stromal cells. *Fertil Steril* 2009;91(5 Suppl):2185-2192. doi:10.1016/j.fertnstert.2008.04.052. PMID:18684450.
- Polyak K, Weinberg RA. Transitions between epithelial and mesenchymal states: acquisition of malignant and stem cell traits. *Nat Rev Cancer* 2009;9(4):265-273. doi:10.1038/nrc2620. PMID:19262571.
- Wu J, Wei JJ. HMGA2 and high-grade serous ovarian carcinoma. *J Mol Med (Berl)* 2013;91(10):1155-1165. doi:10.1007/s00109-013-1055-8. PMID:23686260.
- Shell S, Park SM, Radjabi AR, Schickel R, Kistner EO, Jewell DA, et al. Let-7 expression defines two differentiation stages of cancer. *PNAS* 2007;104(27):11400-11405. doi:10.1073/pnas.0704372104. PMID:17600087.
- Fusco A, Fedele M. Roles of HMGA proteins in cancer. *Nat Rev Cancer* 2007;7(12):899-910. doi:10.1038/nrc2271. PMID:18004397.
- Wei J. HMGA2 (high mobility group AT-hook2). *Atlas Genet Cytogenet Oncol Haematol* 2016;20(7):403-412. doi:10.4267/2042/66056.
- Makinen N, Vahteristo P, Butzow R, Sjoberg J, Aaltonen LA. Exomic landscape of MED12 mutation-negative and -positive uterine leiomyomas. *Int J Cancer* 2014;134(4):1008-1012. doi:10.1002/ijc.28410. PMID:23913526.
- Bertsch E, Qiang W, Zhang Q, Espona-Fiedler M, Druschitz S, Liu Y, et al. MED12 and HMGA2 mutations: two independent genetic events in uterine leiomyoma and leiomyosarcoma. *Mod Pathol* 2014;27(8):1144-1153. doi:10.1038/modpathol.2013.243. PMID:24390224.
- Ligon AH, Morton CC. Leiomyomata: heritability and cytogenetic studies. *Hum Reprod Update* 2001;7(1):8-14. doi:10.1093/humupd/7.1.8. PMID:11212080.
- Ordlu Z, Nucci MR, Dal Cin P, Hollowell ML, Otis CN, Hornick JL, et al. Intravenous leiomyomatosis: an unusual intermediate between benign and malignant uterine smooth muscle tumors. *Mod Pathol* 2016;29(5):500-510. doi:10.1038/modpathol.2016.36. PMID:26892441.
- Clement PB, Young RH, Scully RE. Diffuse, perinodular, and other patterns of hydropic degeneration within and adjacent to uterine leiomyomas. Problems in differential diagnosis. *Am J Surg Pathol* 1992;16(1):26-32. doi:10.1097/00000478-199201000-00004. PMID:1309411.
- Griffin BB, Ban Y, Lu X, Wei JJ. Hydropic leiomyoma: a distinct variant of leiomyoma closely related to HMGA2 overexpression. *Hum Pathol* 2019;84:164-172. doi:10.1016/j.humpath.2018.09.012. PMID:30292626.
- Parra-Herran C, Schoolmeester JK, Yuan L, Dal Cin P, Fletcher CD, Quade BJ, et al. Myxoid Leiomyosarcoma of the Uterus: A Clinicopathologic Analysis of 30 Cases and Review of the Literature With Reappraisal of Its Distinction From Other Uterine Myxoid Mesenchymal Neoplasms. *Am J Surg Pathol* 2016;40(3):285-301. doi:10.1097/PAS.0000000000000593. PMID:26866354.
- Lu B, Shi H, Zhang X. Myxoid leiomyosarcoma of the uterus: a clinicopathological and immunohistochemical study of 10 cases. *Hum Pathol* 2017;59:139-146. doi:10.1016/j.humpath.2016.09.014. PMID:27717885.
- Arias-Stella JA 3rd, Benayed R, Oliva E, Young RH, Hoang LN, Lee CH, et al. Novel PLAG1 Gene Rearrangement Distinguishes a Subset of Uterine Myxoid Leiomyosarcoma From Other Uterine Myxoid Mesenchymal Tumors. *Am J Surg Pathol* 2019;43(3):382-388. doi:10.1097/PAS.0000000000001196. PMID:30489320.

- [34] Vanharanta S, Wortham NC, Laiho P, Sjöberg J, Aittomäki K, Arola J, *et al.* 7q deletion mapping and expression profiling in uterine fibroids. *Oncogene* 2005;24(43):6545–6554. doi:10.1038/sj.onc.1208784, PMID:15940248.
- [35] Zhang Q, Kanis MJ, Ubago J, Liu D, Scholtens DM, Strohl AE, *et al.* The selected biomarker analysis in 5 types of uterine smooth muscle tumors. *Hum Pathol* 2018;76:17–27. doi:10.1016/j.humpath.2017.12.005, PMID:29258902.
- [36] Dreux N, Marty M, Chibon F, Velasco V, Hostein I, Ranchere-Vince D, *et al.* Value and limitation of immunohistochemical expression of HMGA2 in mesenchymal tumors: about a series of 1052 cases. *Mod Pathol* 2010;23(12):1657–1666. doi:10.1038/modpathol.2010.174, PMID:20834238.
- [37] Li Y, Qiang W, Griffin BB, Gao T, Chakravarti D, Bulun S, *et al.* HMGA2-mediated tumorigenesis through angiogenesis in leiomyoma. *Fertil Steril* 2020;114(5):1085–1096. doi:10.1016/j.fertnstert.2020.05.036, PMID:32868105.
- [38] Pallante P, Sepe R, Puca F, Fusco A. High mobility group a proteins as tumor markers. *Front Med (Lausanne)* 2015;2:15. doi:10.3389/fmed.2015.00015, PMID:25859543.
- [39] Malek A, Bakhidze E, Noske A, Sers C, Aigner A, Schäfer R, *et al.* HMGA2 gene is a promising target for ovarian cancer silencing therapy. *Int J Cancer* 2008;123(2):348–356. doi:10.1002/ijc.23491, PMID:18452175.
- [40] McMillen BD, Aponte MM, Liu Z, Helenowski IB, Scholtens DM, Buttin BM, *et al.* Expression analysis of MIR182 and its associated target genes in advanced ovarian carcinoma. *Mod Pathol* 2012;25(12):1644–1653. doi:10.1038/modpathol.2012.118, PMID:22790015.
- [41] Mahajan A, Liu Z, Gellert L, Zou X, Yang G, Lee P, *et al.* HMGA2: a biomarker significantly overexpressed in high-grade ovarian serous carcinoma. *Mod Pathol* 2010;23(5):673–681. doi:10.1038/modpathol.2010.49, PMID:20228781.
- [42] Wei JJ, Wu J, Luan C, Yeldandi A, Lee P, Keh P, *et al.* HMGA2: a potential biomarker complement to P53 for detection of early-stage high-grade papillary serous carcinoma in fallopian tubes. *Am J Surg Pathol* 2010;34(1):18–26. doi:10.1097/PAS.0b013e3181be5d72, PMID:19898227.
- [43] Cancer Genome Atlas Research Network. Integrated genomic analyses of ovarian carcinoma. *Nature* 2011;474(7353):609–615. doi:10.1038/nature10166, PMID:21720365.
- [44] Welsh JB, Zarrinkar PP, Sapinoso LM, Kern SG, Behling CA, Monk BJ, *et al.* Analysis of gene expression profiles in normal and neoplastic ovarian tissue samples identifies candidate molecular markers of epithelial ovarian cancer. *PNAS* 2001;98(3):1176–1181. doi:10.1073/pnas.98.3.1176, PMID:11158614.
- [45] Cancer Genome Atlas Research Network, Kandoth C, Schultz N, Cherniack AD, Akbani R, Liu Y, *et al.* Integrated genomic characterization of endometrial carcinoma. *Nature* 2013;497(7447):67–73. doi:10.1038/nature12113, PMID:23636398.
- [46] McCluggage WG, Connolly LE, McBride HA, Kalloger S, Gilks CB. HMGA2 is commonly expressed in uterine serous carcinomas and is a useful adjunct to diagnosis. *Histopathology* 2012;60(4):547–553. doi:10.1111/j.1365-2559.2011.04105.x, PMID:22250726.
- [47] Soslow RA, Tornos C, Park KJ, Malpica A, Matias-Guiu X, Oliva E, *et al.* Use of FIGO Grading and Genomic Subcategories in Clinical Practice: Recommendations of the International Society of Gynecological Pathologists. *Int J Gynecol Pathol* 2019;38(1 Suppl 1):S64–S74. doi:10.1097/PGP.0000000000000518, PMID:30550484.