



Original Article

# Diagnostic Accuracy of the Apparent Diffusion Coefficient for Microvascular Invasion in Hepatocellular Carcinoma: A Meta-analysis

Yuhui Deng<sup>1,2#</sup>, Jisheng Li<sup>3#</sup>, Hui Xu<sup>1</sup>, Ahong Ren<sup>1</sup>, Zhenchang Wang<sup>1</sup>, Dawei Yang<sup>1\*</sup> and Zhenghan Yang<sup>1\*</sup>

<sup>1</sup>Department of Radiology, Beijing Friendship Hospital, Capital Medical University, Beijing, China; <sup>2</sup>Medical Imaging Division, Heilongjiang Provincial Hospital, Harbin Institute of Technology, Harbin, Heilongjiang, China; <sup>3</sup>Department of Interventional Radiology, Yantai Penglai Traditional Chinese Medicine Hospital, Yantai, Shandong, China

Received: 30 June 2021 | Revised: 13 October 2021 | Accepted: 27 October 2021 | Published: 4 January 2022

## Abstract

**Background and Aims:** Microvascular invasion (MVI) is a major risk factor for the early recurrence of hepatocellular carcinoma (HCC) and it seriously worsens the prognosis. Accurate preoperative evaluation of the presence of MVI could greatly benefit the treatment management and prognosis prediction of HCC patients. The study aim was to evaluate the diagnostic performance of the apparent diffusion coefficient (ADC), a quantitative parameter for the preoperative diagnosis MVI in HCC patients. **Methods:** Original articles about diffusion-weighted imaging (DWI) and/or intravoxel incoherent motion (IVIM) conducted on a 3.0 or 1.5 Tesla magnetic resonance imaging (MRI) system indexed through January 17, 2021 were collected from MEDLINE/PubMed, Web of Science, EMBASE, and the Cochrane Library. Methodological quality was evaluated using Quality Assessment of Diagnostic Accuracy Studies 2 (QUADAS-2). The pooled sensitivity, specificity, and summary area under the receiver operating characteristic curve (AUROC) were calculated, and meta-regression analysis was performed using a bivariate random effects model through a meta-analysis. **Results:** Nine original articles with a total of 988 HCCs were included. Most studies had low bias risk and minimal applicability concerns. The pooled sensitivity, specificity and AUROC of the ADC value were 73%, 70%, and 0.78, respectively. The time interval between the index test and the reference standard was identified as a possible source of heterogeneity by subgroup meta-regression analysis. **Conclusions:** Meta-analysis showed that the ADC

value had moderate accuracy for predicting MVI in HCC. The time interval accounted for the heterogeneity.

**Citation of this article:** Deng Y, Li J, Xu H, Ren A, Wang Z, Yang D, et al. Diagnostic Accuracy of the Apparent Diffusion Coefficient for Microvascular Invasion in Hepatocellular Carcinoma: A Meta-analysis. J Clin Transl Hepatol 2022;10(4):642–650. doi: 10.14218/JCTH.2021.00254.

## Introduction

Hepatocellular carcinoma (HCC) is one of the most common primary liver malignancies and the third leading cause of tumor-related deaths worldwide.<sup>1,2</sup> Surgical resection and transplantation are currently considered the optimal treatments of HCC, and despite consistent improvement in recent decades, both early-stage and long-term prognosis remain poor because of high recurrence rates.<sup>3</sup> Studies of tumor characteristics, such as histological grade and tumor size,<sup>4,5</sup> have verified that microvascular invasion (MVI) is involved in early recurrence and poor long-term prognosis in HCC patients treated with resection or transplantation.<sup>6,7</sup> As preoperative evaluation of MVI is difficult, a noninvasive, highly accurate tool for evaluating the presence/absence of MVI in HCC patients would help to make treatment decisions.

Diffusion-weighted imaging (DWI) is a magnetic resonance imaging (MRI) technique that is widely accessible and its high sensitivity for detecting the restriction of water molecule movement, contributes to the imaging of liver lesions, including HCC.<sup>8,9</sup> The apparent diffusion coefficient (ADC) value, which reflects the combination of water molecular diffusion and capillary perfusion, has been investigated for lesion characterization, HCC histological grade assessment,<sup>9,10–12</sup> and preoperative assessment of MVI in HCC.<sup>13–15</sup> The varied results of available studies warrants a pooled analysis. This meta-analysis aimed to evaluate the diagnostic accuracy of the ADC value for predicting the presence of MVI in HCC.

## Methods

Preferred Reporting Items for Systematic Reviews and Me-

**Keywords:** Hepatocellular carcinoma; Meta-analysis; Diagnostic accuracy; Diffusion-weighted imaging; Microvascular invasion.

**Abbreviations:** ADC, apparent diffusion coefficient; AUROC, area under the receiver operating characteristic curve; DWI, diffusion-weighted imaging; HCC, hepatocellular carcinoma; IVIM, intravoxel incoherent motion; MRI, Magnetic resonance imaging; MVI, Microvascular invasion; QUADAS 2, Quality Assessment of Diagnostic Accuracy Studies 2.

#Contributed equally to this work.

\*Correspondence to: Dawei Yang and Zhenghan Yang, Beijing Friendship Hospital, Capital Medical University, Yongan Road 95, West District, Beijing 100050, China. ORCID: <https://orcid.org/0000-0002-1868-2746> (DY) and <https://orcid.org/0000-0003-3986-1732> (ZY). Tel: +86-13488676354 (DY) and +86-13910831365 (ZY), Fax: +86-10-63138490, E-mail: yangdawei@ccmu.edu.cn (DY) and yangzhenghan@vip.163.com (ZY)

ta-Analyses (PRISMA)<sup>16</sup> was adopted as a guide for performing the meta-analysis.

### Literature search

The PICOS standard was used to guide the search.<sup>17</sup> We conducted a comprehensive search for studies on the diagnostic validity of all diffusion-related parameters for the preoperative evaluation of MVI in HCC in Web of Science, EMBASE, PubMed/MEDLINE, and the Cochrane Library until January 17, 2021. EndNote X9 software (Thomson Reuters, NY, USA) was used for efficient filtering. Details of the search strategy are shown in Supplement 1. Additionally, all references shown in the listed literature were manually checked.

### Inclusion and exclusion criteria

The inclusion criteria were as follows. (1) The diagnostic performance of MVI in HCC was evaluated using the ADC parameters of DWI or intravoxel incoherent motion (IVIM) in the original quantitative study. (2) The data provided by the study were sufficient to construct a diagnostic 2 × 2 table. (3) The article was published in English; and (4) at least 30 HCC patients were included. The exclusion criteria were as follows: (1) nonhuman research; and (2) literature published in formats including reviews, patents, guidelines, chapters, case reports, conference abstracts, letters, or editorials.

### Data extraction and quality assessment

Two observers with more than 6 years of experience in liver imaging performed the data extraction and quality assessment. For any disagreements in the above process, consensus was obtained with the help of a third radiologist with 16 years of liver imaging experience, as needed. The extracted data included basic data (true positives, false negatives, false negatives, and true negatives) and additional data (patient characteristics, imaging characteristics, and study characteristics) for meta-regression.<sup>18</sup> If multiple diagnostic performance data were provided in the original study, we chose the best outcome. All extracted data were entered into Microsoft Excel 2016 for further analysis. Quality assessment was performed with Quality Assessment of Diagnostic Accuracy Studies 2 (QUADAS-2).<sup>19</sup> The bias risk was rated as low, unclear, or high, and the clinical applicability concern was rated as low, unclear, or high, with converted scores of 1, 2, or 3, respectively.<sup>20</sup> In subsequent meta-regression analyses, the total scores of each study served as covariates to quantitatively represent the general risk of bias and applicability.

### Pathological MVI in HCC

MVI is defined as the presence of tumors in endothelial cells by microscopy, including the portal vein and hepatic vein.<sup>21</sup> In all included studies, MVI was divided into two groups (positive MVI or negative MVI).

### Statistical analysis

QUADAS evaluations of the included articles were performed with Review Manager 5.3 software (Cochrane Collaboration,

Copenhagen, Denmark). Threshold effect assessment was conducted using Meta-Disc 1.4 software provided by Ramon y Cajal Hospital, Madrid, Spain.<sup>22</sup> The pooled sensitivity, specificity, positive likelihood ratio, negative likelihood ratio, and diagnostic odds ratio and their corresponding 95% confidence intervals (CIs) were determined by STATA 14 (StataCorp, College Station, Texas, USA) software using the MIDAS command.<sup>23,24</sup> Both the  $I^2$  statistic ( $I^2 > 50\%$ ) and Cochran Q ( $p < 0.05$ ) were used to determine the possible occurrence of between-study heterogeneity.<sup>25,26</sup> Meta-regression was conducted to assess study heterogeneity.

## Results

### Literature search

After a comprehensive search, 435 records were retrieved. Initially, 148 records were removed by the automatic find-duplicate function embedded in Endnote X9 software, and 44 conference abstracts, 21 reviews, five meta-analyses, two case reports, two letters, and two editorials were excluded because their improper publication type. For a more accurate screening, we read the full texts of the remaining 211 records. After excluding seven non-English studies, those without sufficient data to extract, and 191 unrelated studies, nine studies eventually remained (Fig. 1).

### Quality assessment and data extraction

The detailed data of the included articles are shown in Table 1<sup>13-15,27-32</sup> and Supplement 2, including patient characteristics (country/region, year, average age, number of lesions, average size), research characteristics (research design, number of readers, recruitment methods, time interval between the index test and the reference standard, blindness to the index test during the reference test, blindness to the reference test during the index test), and imaging characteristics (MR manufacturer, MR field, MRI sequence, quantitative parameters, details of  $b$  values). The methodologic quality of all studies based on QUADAS-2 is shown in Figure 2. Generally, there was a low bias risk and minimal concern of clinical applicability in most studies. Five studies had an unclear bias risk because it was not certain whether consecutive patients were recruited. Unclear applicability concerns were present in four studies because of the relative simplicity of the patient inclusion and exclusion criteria. Only one study had an unclear bias risk because it was not clear whether the reference results were blinded during the index test. Five studies had an unclear bias risk because they did not report the status of blinding of the index test results during the reference test in the reference standard. Additionally, there were concerns of the applicability of two studies because of insufficient information on pathological MVI. Regarding flow and timing, one study that did not report the interval between the reference standard and MRI examinations, and three with time intervals greater than 1 month were regarded as having an unclear bias risk and a high bias risk, respectively.

### Diagnosis of MVI in HCC

Overall, the accuracy of the ADC value in predicting the presence of MVI was evaluated in nine studies including 988 HCCs. The details of pooled sensitivity, specificity, positive likelihood ratio, negative likelihood ratio, and diagnostic

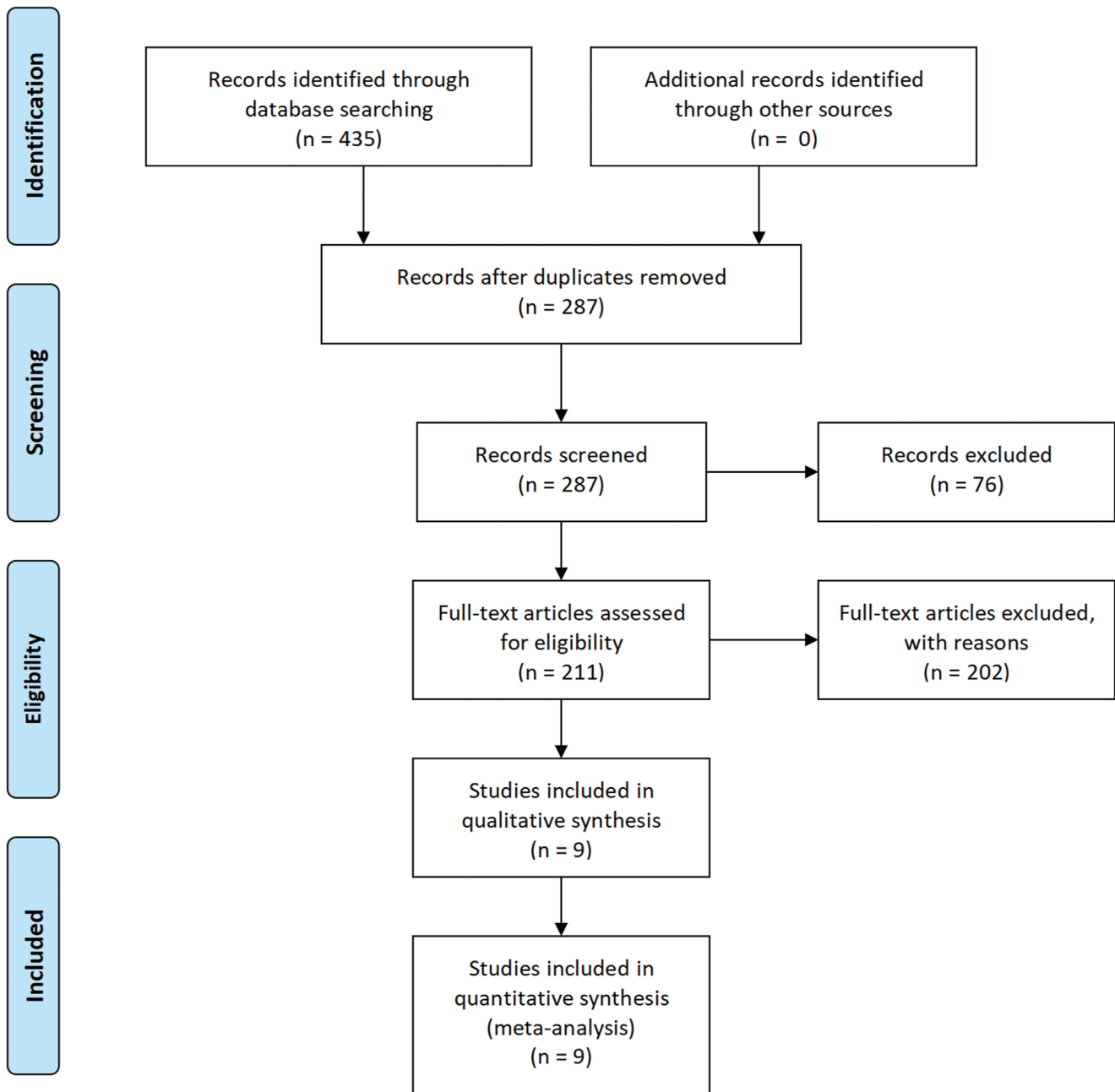


Fig. 1. Flowchart of study selection. ADC, apparent diffusion coefficient.

odds ratio were shown in Table 2. The area under the receiver operating characteristic curve (AUROC) of the ADC value was 0.78 for diagnosing MVI in HCC (Fig. 3). The forest plots showed that the between-study heterogeneities of ADC presented sensitivity ( $p=0.10$ ,  $I^2=40.64\%$ ) and specificity ( $p < 0.01$ ,  $I^2=70.59\%$ , Fig. 4).

The Begg’s funnel plot for ADC in predicting MVI ( $Z=2.40$ ,  $p=0.016$ ) are presented in Figure 5, which suggests slight asymmetry in the data. Therefore, in evaluating our funnel plots, we can report only that there may have been publication bias, which is difficult to quantify, and that no major publication bias was detected. There was no significant threshold effect ( $p=1.0$ ) for ADC in di-

agnosing MVI in HCC.

**Meta-regression**

Subgroup meta-regression analyses were performed with the following nine covariates: number of lesions (<90 or  $\geq 90$ ), average age (<54 or  $\geq 54$  years), average size (<30 or  $\geq 30$  mm), interval between the index test and the reference test (<30 or  $\geq 30$  days), blinding of the index test during the reference test (yes or unclear), blinding of the reference test during the index test (yes or unclear), concern of applicability score (<4 or  $\geq 4$ ), risk of bias score ( $\leq 6$  or  $> 6$ ) and MR

**Table 1. Characteristics of the included studies**

Patient characteristics						Study characteristics						Reference
Region	Age, years	Size, mm	Lesions, n	Study design	Consecutive	Readers, n	Blind 1	Blind 2	TI (days)	Risk score	Application score	
China	51.97	63.1	135	p	Yes	2	Yes	Yes	14	4	3	Wei <i>et al.</i> <sup>27</sup>
Japan	66.7	20.72	73	R	Yes	2	Yes	Unclear	85	7	4	Okamura <i>et al.</i> <sup>15</sup>
China	52	19	94	R	Unclear	2	Yes	Unclear	14	6	3	Rao <i>et al.</i> <sup>28</sup>
Korea	56	34.06	67	R	Unclear	1	Yes	Yes	45	7	4	Suh <i>et al.</i> <sup>14</sup>
China	54.14	39.43	100	unclear	Yes	Unclear	Unclear	Unclear	Unclear	7	4	Wang <i>et al.</i> <sup>32</sup>
China	51.51	27.9	41	p	Yes	2	Yes	Unclear	30	5	3	Li <i>et al.</i> <sup>29</sup>
China	53.2	14.4	109	R	Unclear	2	Yes	Yes	16	5	4	Xu <i>et al.</i> <sup>13</sup>
China	59	57	318	R	Unclear	2	Yes	Unclear	7	6	5	Zhao J <i>et al.</i> <sup>30</sup>
China	50.6	56.7	51	R	Unclear	2	Yes	Yes	58	7	3	Zhao W <i>et al.</i> <sup>31</sup>

Imaging characteristics					Reference
Sequence	Parameter	Field (T)	Manufacturer	b-value feature, s/mm <sup>2</sup>	
IVIM	ADC/D	3	GE	0, 10, 20, 40, 80, 100, 150, 200, 400, 600, 800, 1,000, and 1,200	Wei <i>et al.</i> <sup>27</sup>
DWI	ADC	1.5/3.0	Siemens/GE	0, 1,000	Okamura <i>et al.</i> <sup>15</sup>
DWI	ADC	1.5	Siemens	0, 500	Rao <i>et al.</i> <sup>28</sup>
DWI	ADC	3	Siemens	50, 400, 800	Suh <i>et al.</i> <sup>14</sup>
DWI	ADC	3	GE/Philips	0, 100, 600	Wang <i>et al.</i> <sup>32</sup>
IVIM	ADC/D	3	Philips	0, 10, 20, 40, 80, 200, 400, 600, 1000	Li <i>et al.</i> <sup>29</sup>
DWI	ADC	1.5	Siemens	0, 500	Xu <i>et al.</i> <sup>13</sup>
DWI	ADC	1.5	GE	0, 800	Zhao J <i>et al.</i> <sup>30</sup>
IVIM	ADC/D	3	GE	0, 10, 20, 30, 40, 50, 60, 70, 80, 90, 100, 200, 300, 400, 500, 1,000	Zhao W <i>et al.</i> <sup>31</sup>

ADC, apparent diffusion coefficient; Application score, QUADAS score of clinical application concern; Blind 1, blinded to reference standard when assessing index test; Blind 2, blinded to index test when assessing reference test; D, tissue diffusivity; DWI, diffusion-weighted imaging; IVIM, intravoxel incoherent motion; P, prospective; R, retrospective; Risk score, QUADAS bias risk score; T, Tesla; TI, time interval between index test and reference standard.

parameter (DWI or IVIM). The results are shown in Table 3. The time interval ( $p < 0.01$  by the joint model) was a significant cause of heterogeneity. Studies with time intervals  $\geq 30$  days had significantly lower sensitivity and higher specificity than those with time intervals of  $< 30$  days (72% vs. 75% and 70% vs. 72%, respectively,  $p < 0.01$ ). In contrast, there were no sources of heterogeneity for mean age ( $p = 0.21$ ), mean size ( $p = 0.08$ ), number of lesions ( $p = 0.91$ ), blinding of the reference standard during the index test ( $p = 0.70$ ), blinding of the index test during the reference test ( $p = 0.49$ ), QUADAS risk of bias score ( $p = 0.35$ ), QUADAS applicability concern score ( $p = 0.11$ ) and MR sequence ( $p = 0.57$ ).

In addition, studies with a large number of lesions had the same specificity (70% vs. 70%,  $p = 0.12$ ) and a significantly higher sensitivity (74% vs. 72%,  $p < 0.01$ ) than those with a small number of lesions. Studies with a low risk of bias reported a significantly higher sensitivity than studies with a high risk of bias (75% vs. 71%,  $p = 0.02$ ). Studies with small sample sizes reported a significantly higher sensitivity

and a significantly lower specificity (65% vs. 74%,  $p = 0.01$ ) than those with large sizes (79% vs. 69%,  $p = 0.04$ ). Studies with unclear blinding of the index test reported significantly higher sensitivity and specificity than studies with blinding of the index test (74% vs. 73%,  $p < 0.01$  and 73% vs. 66%,  $p = 0.02$ , respectively). Studies using the DWI parameter reported a significantly higher sensitivity and a significantly lower specificity (67% vs. 75%,  $p = 0.01$ ) than those using the IVIM parameter (74% vs. 72%,  $p = 0.03$ ).

## Discussion

This meta-analysis included nine original articles with 988 HCCs and assessed the diagnostic performance of the ADC value for predicting MVI, with a pooled sensitivity, specificity, and AUROC of 73%, 70% and 0.78, respectively. Our meta-analysis indicated that the ADC value had moderate

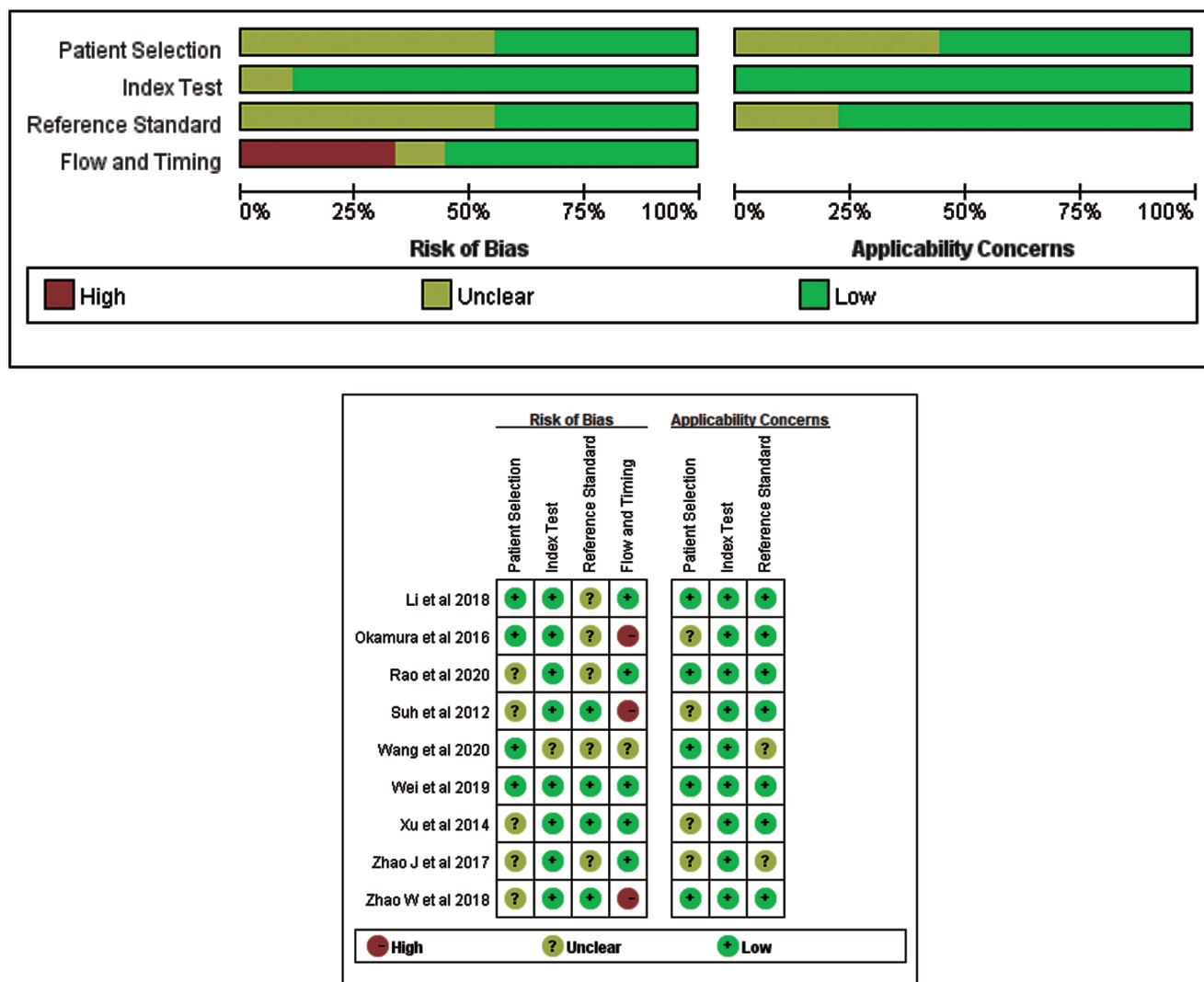


Fig. 2. Stacked bar charts of Quality Assessment of Diagnostic Accuracy Studies 2 (QUADAS2) scores of methodologic study quality provide an overview of study quality in the whole meta-analysis.

accuracy in predicting MVI in HCC, which was consistent with the findings of several high-impact original studies,<sup>27-30</sup> with a sensitivity and specificity of 71-76% and 65-66%, respectively. Several hypothetical reasons may contribute to the relation between the ADC value and the MVI status in HCC. First, MVI is more common in HCCs with higher histologic grades,<sup>33</sup> and the ADC value has been reported to accurately assess the histologic grade of HCC.<sup>18</sup> Therefore, it is possible that the ADC value could be used to predict MVI in HCC. Second, tumor embolism in MVI-positive hepatic vascular branches, such as the portal vein, hepatic vein and intracapsular vessel, can limit the diffusion of wa-

ter molecules to some extent.<sup>34</sup> Additionally, the presence of MVI can further increase the infiltration of tumor cells, provide more nutrients needed for proliferation, increase the tumor-cell density, and further limit the diffusion of water molecules.<sup>27</sup> However, because of the intrinsic inability to separate the effects of capillary perfusion and molecular diffusion, the diagnostic performance of the ADC value is not as promising in predicting MVI in HCC.

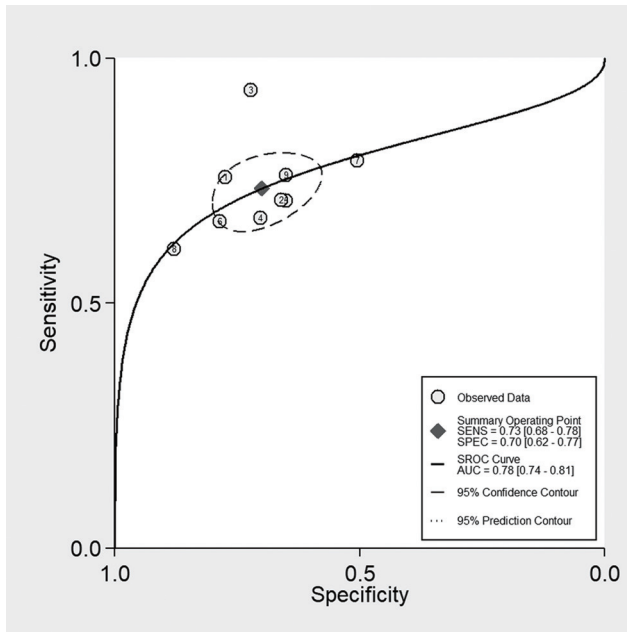
Several studies have investigated the diagnostic accuracy of other diffusion parameters, including the mean apparent kurtosis coefficient and tissue diffusivity (*D*-value). Wang *et al.*<sup>35</sup> and Cao, *et al.*<sup>36</sup> found that higher mean kur-

Table 2. Diagnostic accuracy of the apparent diffusion coefficient value for microvascular invasion of hepatocellular carcinoma

	Studies, <i>n</i> (patients, <i>n</i> )	AUROC	Sensitivity, % (95% CI)	Specificity, % (95% CI)	positive likelihood ratio, (95% CI)	Negative likelihood ratio, (95% CI)	Diagnostic odds ratio, (95% CI)
ADC	9 (988)	0.78 (0.74, 0.81)	0.73 (0.68, 0.78)	0.70 (0.62, 0.77)	2.4 (2.0, 3.1)	0.38 (0.32, 0.46)	6 (5, 9)

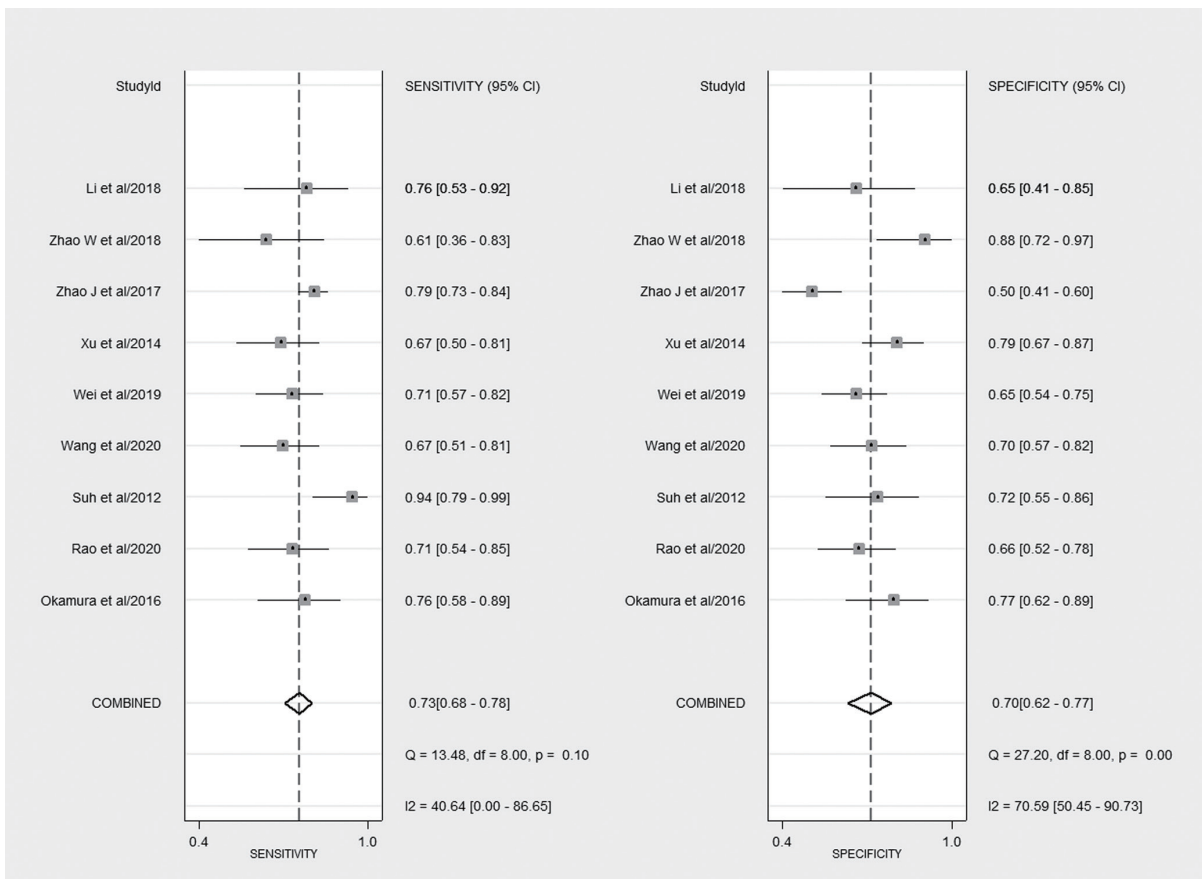
ADC, apparent diffusion coefficient; AUROC, area under the summary receiver operating characteristic curve; HCC, hepatocellular carcinoma; MVI, microvascular invasion.





**Fig. 3. Summary receiver operating characteristic (SROC) plots of the apparent diffusion coefficient (ADC) value for microvascular invasion (MVI) of hepatocellular carcinomas.**

tosis values were potential predictors of MVI in HCC, with sensitivity, specificity and AUROC values of 70%, 77%, and 0.784 and 68.4%, 75%, and 0.77, respectively, which were comparable to the diagnostic performance of the ADC value calculated in this study. Diffusion kurtosis imaging (DKI), which reflects the heterogeneity and irregularity of tissue components, is an extension of diffusion tensor imaging for the detection of non-Gaussian water diffusion.<sup>37</sup> The higher mean kurtosis values may be caused by a more complex microenvironment with denser cellular structures and more irregular and heterogeneous lesions introduced by MVI, such as neoplastic cells, necrosis, and inflammation.<sup>35</sup> In theory, IVIM can distinguish true water molecule diffusion from microcapillary perfusion. Therefore, the true tissue molecular diffusivity (*D*) calculated by the IVIM technique is more effective than the ADC value in probing the small differences in water molecule diffusion induced by MVI.<sup>38,39</sup> To date, three published studies have examined the diffusion parameter of the *D*-value, and the results are inconsistent.<sup>27,29,31</sup> Wei *et al.*<sup>27</sup> found that the *D*-value was better than the ADC value for assessing MVI in HCC, with sensitivity, specificity and AUROC values of 78.2%, 75%, and 0.815, respectively. Zhao *et al.*<sup>31</sup> showed that the *D*-value had a moderate diagnostic performance for assessing MVI in HCC, with sensitivity, specificity and AUROC values of 66.7%, 88.9%, and 0.753, respectively. With limited studies and varied results, more studies are needed in the future to evaluate and confirm the diagnostic performance of the *D*-value and apparent kurtosis coefficient for MVI in HCC.



**Fig. 4. Forest plots of tests.** The accuracy estimates (sensitivity and specificity) of the apparent diffusion coefficient (ADC) value for microvascular invasion (MVI) of hepatocellular carcinomas.

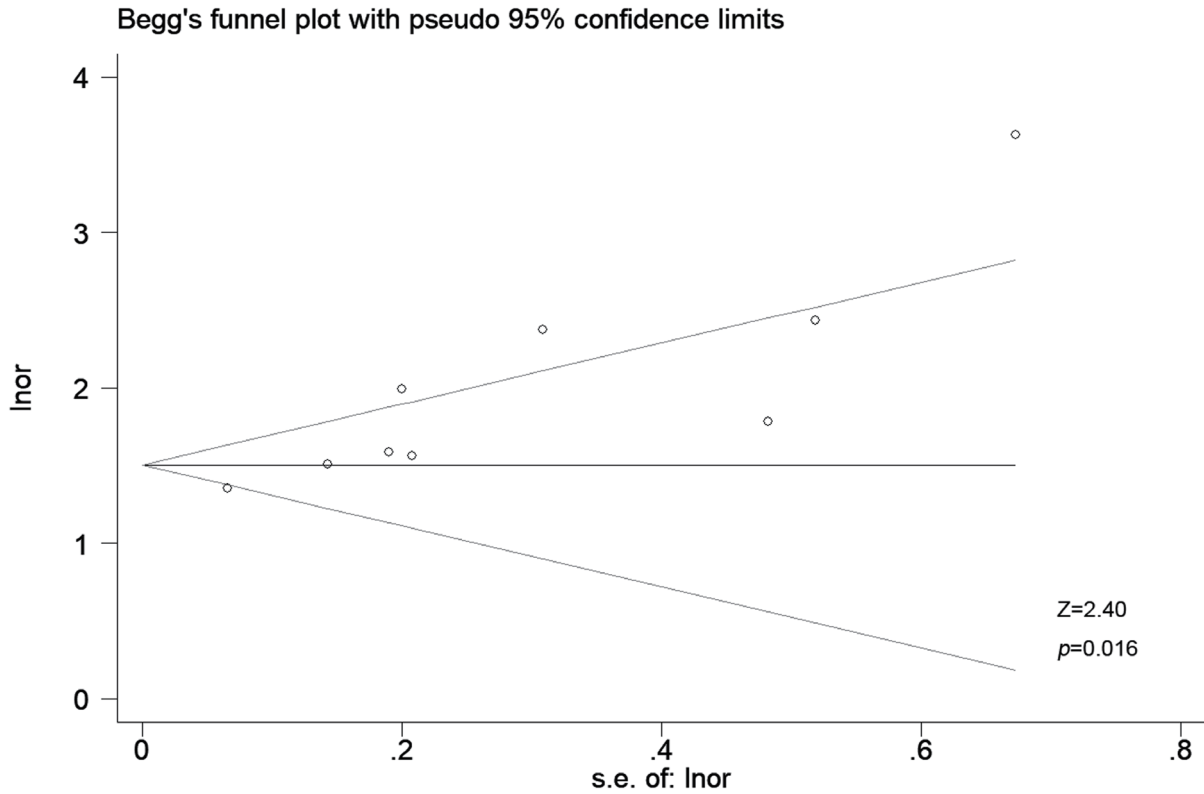


Fig. 5. Begg's funnel plot for publication bias. The apparent diffusion coefficient (ADC) value for microvascular invasion (MVI) of hepatocellular carcinomas.

Table 3. Covariate meta-regression results of apparent diffusion coefficient value for microvascular invasion of hepatocellular carcinoma

Covariate	Sub-group	Studies, n	p	Summary sensitivity, % (95% CI)	p1	Summary specificity, % (95% CI)	p2
Age, years	<54	5	0.21	0.77 (0.72, 0.83)	0.05	0.69 (0.59, 0.78)	0.05
	≥54	4		0.68 (0.61, 0.76)		0.72 (0.62, 0.82)	
Size, mm	<30	4	0.08	0.79 (0.73, 0.84)	0.04	0.65 (0.55, 0.76)	0.01
	≥30	5		0.69 (0.62, 0.76)		0.74 (0.65, 0.82)	
Included lesions, n	<90	4	0.91	0.72 (0.64, 0.80)	0.00	0.70 (0.59, 0.81)	0.12
	≥90	5		0.74 (0.68, 0.81)		0.70 (0.60, 0.80)	
Blind to reference	Yes	8	0.70	0.74 (0.68, 0.79)	0.18	0.71 (0.63, 0.78)	0.72
	Unclear	1		0.71 (0.57, 0.85)		0.65 (0.44, 0.86)	
Blind to index test, n	Yes	4	0.49	0.73 (0.66, 0.80)	0.00	0.66 (0.56, 0.77)	0.02
	Unclear	5		0.74 (0.67, 0.82)		0.73 (0.64, 0.82)	
Time interval, days	<30	4	0.00	0.75 (0.68, 0.82)	0.03	0.72 (0.61, 0.83)	0.24
	≥30	4		0.72 (0.64, 0.80)		0.70 (0.58, 0.82)	
Risk score	≤6	5	0.35	0.75 (0.69, 0.82)	0.02	0.73 (0.63, 0.82)	0.32
	>6	4		0.71 (0.63, 0.78)		0.67 (0.56, 0.78)	
Applicability concern score	<4	4	0.11	0.78 (0.69, 0.87)	0.14	0.74 (0.65, 0.84)	0.29
	≥4	5		0.71 (0.63, 0.78)		0.67 (0.58, 0.76)	
Sequence	DWI	6	0.57	0.74 (0.68, 0.80)	0.03	0.67 (0.59, 0.75)	0.01
	IVIM	3		0.72 (0.62, 0.83)		0.75 (0.65, 0.86)	

ADC, apparent diffusion coefficient; DWI, diffusion-weighted imaging; HCC, hepatocellular carcinoma; IVIM, intravoxel incoherent motion; MVI, microvascular invasion.

In addition to quantitative parameters, many qualitative parameters are available for evaluating MVI, such as non-smooth tumor margins, irregular rim-like enhancement in the arterial phase, peritumoral arterial phase hyperenhancement, and peritumoral hepatobiliary phase hypointensity on MRI. In a high-quality meta-analysis, Hong *et al.*<sup>40</sup> summarized multiple MRI features and concluded that rim arterial enhancement, arterial peritumoral enhancement, peritumoral hypointensity in the hepatobiliary phase (HBP), and non-smooth margins were significant predictors of MVI of HCC, with sensitivities and specificities of 36.4% and 87.9%, 49.7% and 81.5%, 44.2% and 91.1%, and 67.1% and 60.7%, respectively. A recent meta-analysis<sup>41</sup> of the evaluation of non-smooth tumor margins and peritumoral hypointensity in the HBP to preoperatively diagnose the presence of MVI in HCC obtained similar results with sensitivity, specificity and AUROC values of 73%, 61%, and 0.74 and 43%, 90%, and 0.76, respectively. Those parameters were similar to the ADC value in predicting MVI in HCC with moderate accuracy, but qualitative parameters are subjective. Even for experienced radiologists, there is a difference.<sup>42</sup> The ADC value can be quantitative or qualitative. As a quantitative parameter, compared with qualitative parameters, it is not limited by subjective differences of interpretation and has stronger practicability. In addition, the ADC value is one of the most commonly used clinical indicators and can be obtained without the use of contrast agents. Accordingly, we believe this work is necessary and useful, especially for those who are unable to undergo MRI enhancement for many reasons.

Compared with deep learning and radiomics, the diagnostic performance of the ADC value was inferior to that of the fusion-deep supervision net based on ADC, with sensitivity, specificity and AUROC values of 67.06% vs. 75.29%, 70.43% vs. 79.13%, and 71.24 vs. 79.69, respectively.<sup>32</sup> Additionally, the diagnostic performance of the ADC value was inferior to that of radiomics models based on MRI. Feng *et al.*<sup>43</sup> found that a radiomics model based on HBP images had a relatively high performance in predicting MVI in HCC, with sensitivity, specificity and AUROC values of 90%, 75%, and 0.83, respectively, in the validation cohort. A recent study<sup>44</sup> found that a radiomics model based on DWI combined with multiple phases of gadoxetate disodium-enhanced MRI had a higher performance in diagnosing MVI in HCC, with sensitivity, specificity and AUROC values of 96%, 86%, and 0.918 in the validation cohort. Therefore, the use of deep learning and radiomics can improve the diagnostic performance of MVI in liver cancer and is a direction for future research.

In this study, meta-regression analyses of nine covariates showed that only the time interval was a significant source of heterogeneity. Studies with time intervals <30 days exhibited significantly higher sensitivity and specificity than those with time intervals ≥30 days. The shorter the time interval between MRI examination and surgical resection, the more closely the imaging features reflect the tumor parenchyma, and the better the diagnostic effectiveness. Therefore, an appropriate time interval should be considered in future studies. Additionally, studies with tumor sizes of <30 mm exhibited significantly higher sensitivity and lower specificity than studies with tumors ≥30 mm. Generally, the larger the diameter of HCCs, the greater the possibility of the existence of MVI<sup>45-47</sup> and the easier it is to observe the imaging features; thus, the diagnostic efficiency of MVI is better. However, that result was not obtained in the study. A possible reason is that the larger the HCC is, the more prone it is to bleeding and necrosis, which affect the ADC measurement. Meta-regression was conducted for bias risk, and studies with low risk had higher sensitivity than studies with high risk (75% vs. 71%,  $p=0.02$ ), which showed that improving the quality of test studies is essential. Meta-regression was also conducted for

the blind to index test, and studies with unclear blinding had better sensitivity and specificity than those with blinding (74% vs. 73%,  $p < 0.01$  and 73% vs. 66%,  $p=0.02$ ). The measurement bias of the pathological results probably occurred because reviewers had some knowledge of the signal intensity. Meta-regression was also conducted for the number of included lesions, and studies with a large number of lesions had higher sensitivity than those with a small number of lesions (74% vs. 72%,  $p < 0.01$ ), which indicated that increasing the number of samples is essential. Those covariates should be used to reduce heterogeneity as much as possible in further studies.

There were several limitations. First, most of the studies included in the meta-analysis were retrospective, which may cause patient and imaging technique selection biases. Second, we discussed the diagnostic accuracy of the D-value in predicting MVI in HCC in our discussion but did not include it in our meta-analysis because of the limited number of studies. Finally, only original articles in English were included in the meta-analysis. In conclusion, our meta-analysis found that the ADC value had moderate accuracy in noninvasively predicting pathological MVI in HCC. In future studies, artificial intelligence such as radiomics studies and deep learning based on a combination of multiple MRI sequences or more MRI features, including the D-value of IVIM, could be performed to investigate and verify potential improvements for predicting MVI in HCC.

#### Acknowledgments

The authors would like to express our enormous appreciation and gratitude to all participants.

#### Funding

The work was supported by the National Natural Science Foundation of China (Nos. 82071876, 61871276); Beijing Natural Science Foundation (No. 7184199); and Heilongjiang province Science Foundation for Youths (No. QC201807); Beijing Municipal Administration of Hospitals' Youth Programme (No. QML20200108).

#### Conflict of interest

The authors have no conflict of interests related to this publication.

#### Author contributions

Study concept and design (DY, ZY), acquisition of data (YD, JL), analysis and interpretation of data (DY, ZY, YD, JL), drafting of the manuscript (DY, YD), critical revision of the manuscript for important intellectual content (HX, AR, ZW), administrative, technical, and material support, study supervision (ZW).

#### Data sharing statement

No additional data are available.

#### References

[1] Golabi P, Fazel S, Otgonsuren M, Sayiner M, Locklear CT, Younossi ZM. Mor-



- tality assessment of patients with hepatocellular carcinoma according to underlying disease and treatment modalities. *Medicine (Baltimore)* 2017; 96(9):e5904. doi:10.1097/md.0000000000005904, PMID:28248853.
- [2] El-Serag HB. Epidemiology of viral hepatitis and hepatocellular carcinoma. *Gastroenterology* 2012;142(6):1264–1273.e1261. doi:10.1053/j.gastro.2011.12.061, PMID:22537432.
- [3] Iguchi T, Shirabe K, Aishima S, Wang H, Fujita N, Ninomiya M, *et al*. New Pathologic Stratification of Microvascular Invasion in Hepatocellular Carcinoma: Predicting Prognosis After Living-donor Liver Transplantation. *Transplantation* 2015;99(6):1236–1242. doi:10.1097/tp.0000000000000489, PMID:25427164.
- [4] Imamura H, Matsuyama Y, Tanaka E, Ohkubo T, Hasegawa K, Miyagawa S, *et al*. Risk factors contributing to early and late phase intrahepatic recurrence of hepatocellular carcinoma after hepatectomy. *J Hepatol* 2003;38(2):200–207. doi:10.1016/s0168-8278(02)00360-4, PMID:12547409.
- [5] Cucchetti A, Piscaglia F, Caturelli E, Benvenuto L, Vivarelli M, Ercolani G, *et al*. Comparison of recurrence of hepatocellular carcinoma after resection in patients with cirrhosis to its occurrence in a surveilled cirrhotic population. *Ann Surg Oncol* 2009;16(2):413–422. doi:10.1245/s10434-008-0232-4, PMID:19034578.
- [6] Sumie S, Kuromatsu R, Okuda K, Ando E, Takata A, Fukushima N, *et al*. Microvascular invasion in patients with hepatocellular carcinoma and its predictable clinicopathological factors. *Ann Surg Oncol* 2008;15(5):1375–1382. doi:10.1245/s10434-008-9846-9, PMID:18324443.
- [7] Oishi K, Itamoto T, Amano H, Fukuda S, Ohdan H, Tashiro H, *et al*. Clinicopathologic features of poorly differentiated hepatocellular carcinoma. *J Surg Oncol* 2007;95(4):311–316. doi:10.1002/jso.20661, PMID:17326126.
- [8] Koh DM, Collins DJ. Diffusion-weighted MRI in the body: applications and challenges in oncology. *AJR Am J Roentgenol* 2007;188(6):1622–1635. doi:10.2214/ajr.06.1403, PMID:17515386.
- [9] Taouli B, Koh DM. Diffusion-weighted MR imaging of the liver. *Radiology* 2010;254(1):47–66. doi:10.1148/radiol.09090021, PMID:20032142.
- [10] Lim KS. Diffusion-weighted MRI of hepatocellular carcinoma in cirrhosis. *Clin Radiol* 2014;69(1):1–10. doi:10.1016/j.crad.2013.07.022, PMID:24034549.
- [11] Nishie A, Tajima T, Asayama Y, Ishigami K, Kakihara D, Nakayama T, *et al*. Diagnostic performance of apparent diffusion coefficient for predicting histological grade of hepatocellular carcinoma. *Eur J Radiol* 2011;80(2):e29–33. doi:10.1016/j.ejrad.2010.06.019, PMID:20619566.
- [12] Mannelli L, Kim S, Hajdu CH, Babb JS, Taouli B. Serial diffusion-weighted MRI in patients with hepatocellular carcinoma: Prediction and assessment of response to transarterial chemoembolization. Preliminary experience. *Eur J Radiol* 2013;82(4):577–582. doi:10.1016/j.ejrad.2012.11.026, PMID:23246330.
- [13] Xu P, Zeng M, Liu K, Shan Y, Xu C, Lin J. Microvascular invasion in small hepatocellular carcinoma: is it predictable with preoperative diffusion-weighted imaging? *J Gastroenterol Hepatol* 2014;29(2):330–336. doi:10.1111/jgh.12358, PMID:24033853.
- [14] Suh YJ, Kim MJ, Choi JY, Park MS, Kim KW. Preoperative prediction of the microvascular invasion of hepatocellular carcinoma with diffusion-weighted imaging. *Liver Transpl* 2012;18(10):1171–1178. doi:10.1002/lt.23502, PMID:22767394.
- [15] Okamura S, Sumie S, Tonan T, Nakano M, Satani M, Shimose S, *et al*. Diffusion-weighted magnetic resonance imaging predicts malignant potential in small hepatocellular carcinoma. *Dig Liver Dis* 2016;48(8):945–952. doi:10.1016/j.dld.2016.05.020, PMID:27338850.
- [16] Frank RA, Bossuyt PM, McInnes MDF. Systematic Reviews and Meta-Analyses of Diagnostic Test Accuracy: The PRISMA-DTA Statement. *Radiology* 2018;289(2):313–314. doi:10.1148/radiol.2018180850, PMID:30015590.
- [17] Moher D, Shamseer L, Clarke M, Ghersi D, Liberati A, Petticrew M, *et al*. Preferred reporting items for systematic review and meta-analysis protocols (PRISMA-P) 2015 statement. *Syst Rev* 2015;4(1):1. doi:10.1186/2046-4053-4-1, PMID:25554246.
- [18] Yang D, She H, Wang X, Yang Z, Wang Z. Diagnostic accuracy of quantitative diffusion parameters in the pathological grading of hepatocellular carcinoma: A meta-analysis. *J Magn Reson Imaging* 2020;51(5):1581–1593. doi:10.1002/jmri.26963, PMID:31654537.
- [19] Whiting PF, Rutjes AW, Westwood ME, Mallett S, Deeks JJ, Reitsma JB, *et al*. QUADAS-2: a revised tool for the quality assessment of diagnostic accuracy studies. *Ann Intern Med* 2011;155(8):529–536. doi:10.7326/0003-4819-155-8-201110180-00009, PMID:22007046.
- [20] Yang D, Li D, Li J, Yang Z, Wang Z. Systematic review: The diagnostic efficacy of gadoxetic acid-enhanced MRI for liver fibrosis staging. *Eur J Radiol* 2020;125:108857. doi:10.1016/j.ejrad.2020.108857, PMID:32113153.
- [21] Rodríguez-Perálvarez M, Luong TV, Andreana L, Meyer T, Dhillon AP, Burroughs AK. A systematic review of microvascular invasion in hepatocellular carcinoma: diagnostic and prognostic variability. *Ann Surg Oncol* 2013;20(1):325–339. doi:10.1245/s10434-012-2513-1, PMID:23149850.
- [22] Zamora J, Abaira V, Muriel A, Khan K, Coomarasamy A. Meta-DiSc: a software for meta-analysis of test accuracy data. *BMC Med Res Methodol* 2006;6:31. doi:10.1186/1471-2288-6-31, PMID:16836745.
- [23] Roberts DJ, Chaubey VP, Zygun DA, Lorenzetti D, Faris PD, Ball CG, *et al*. Diagnostic accuracy of computed tomographic angiography for blunt cerebrovascular injury detection in trauma patients: a systematic review and meta-analysis. *Ann Surg* 2013;257(4):621–632. doi:10.1097/SLA.0b013e318288c514, PMID:23470509.
- [24] Vogelgesang F, Schlattmann P, Dewey M. The Evaluation of Bivariate Mixed Models in Meta-analyses of Diagnostic Accuracy Studies with SAS, Stata and R. *Methods Inf Med* 2018;57(3):111–119. doi:10.3414/me17-01-0021, PMID:29719917.
- [25] Melsen WG, Bootsma MC, Rovers MM, Bonten MJ. The effects of clinical and statistical heterogeneity on the predictive values of results from meta-analyses. *Clin Microbiol Infect* 2014;20(2):123–129. doi:10.1111/1469-0699.12494, PMID:24320992.
- [26] Leefflang MM, Deeks JJ, Takwoingi Y, Macaskill P. Cochrane diagnostic test accuracy reviews. *Syst Rev* 2013;2:82. doi:10.1186/2046-4053-2-82, PMID:24099098.
- [27] Wei Y, Huang Z, Tang H, Deng L, Yuan Y, Li J, *et al*. IVIM improves preoperative assessment of microvascular invasion in HCC. *Eur Radiol* 2019;29(10):5403–5414. doi:10.1007/s00330-019-06088-w, PMID:30877465.
- [28] Rao C, Wang X, Li M, Zhou G, Gu H. Value of T1 mapping on gadoxetic acid-enhanced MRI for microvascular invasion of hepatocellular carcinoma: a retrospective study. *BMC Med Imaging* 2020;20(1):43. doi:10.1186/s12880-020-00433-y, PMID:32345247.
- [29] Li H, Zhang J, Zheng Z, Guo Y, Chen M, Xie C, *et al*. Preoperative histogram analysis of intravoxel incoherent motion (IVIM) for predicting microvascular invasion in patients with single hepatocellular carcinoma. *Eur J Radiol* 2018;105:65–71. doi:10.1016/j.ejrad.2018.05.032, PMID:30017300.
- [30] Zhao J, Li X, Zhang K, Yin X, Meng X, Han L, *et al*. Prediction of microvascular invasion of hepatocellular carcinoma with preoperative diffusion-weighted imaging: A comparison of mean and minimum apparent diffusion coefficient values. *Medicine (Baltimore)* 2017;96(33):e7754. doi:10.1097/md.00000000000007754, PMID:28816952.
- [31] Zhao W, Liu W, Liu H, Yi X, Hou J, Pei Y, *et al*. Preoperative prediction of microvascular invasion of hepatocellular carcinoma with IVIM diffusion-weighted MR imaging and Gd-EOB-DTPA-enhanced MR imaging. *PLoS One* 2018;13(5):e0197488. doi:10.1371/journal.pone.0197488, PMID:29771954.
- [32] Wang G, Jian W, Cen X, Zhang L, Guo H, Liu Z, *et al*. Prediction of Microvascular Invasion of Hepatocellular Carcinoma Based on Preoperative Diffusion-Weighted MR Using Deep Learning. *Acad Radiol* 2021;28(Suppl 1):S118–S127. doi:10.1016/j.acra.2020.11.014, PMID:33303346.
- [33] Pawlik TM, Delman KA, Vauthey JN, Nagorney DM, Ng IO, Ikai I, *et al*. Tumor size predicts vascular invasion and histologic grade: Implications for selection of surgical treatment for hepatocellular carcinoma. *Liver Transpl* 2005;11(9):1086–1092. doi:10.1002/lt.20472, PMID:16123959.
- [34] Iima M, Le Bihan D. Clinical Intravoxel Incoherent Motion and Diffusion MR Imaging: Past, Present, and Future. *Radiology* 2016;278(1):13–32. doi:10.1148/radiol.2015150244, PMID:26690990.
- [35] Wang WT, Yang L, Yang ZX, Hu XX, Ding Y, Yan X, *et al*. Assessment of Microvascular Invasion of Hepatocellular Carcinoma with Diffusion Kurtosis Imaging. *Radiology* 2018;286(2):571–580. doi:10.1148/radiol.2017170515, PMID:28937853.
- [36] Cao L, Chen J, Duan T, Wang M, Jiang H, Wei Y, *et al*. Diffusion kurtosis imaging (DKI) of hepatocellular carcinoma: correlation with microvascular invasion and histologic grade. *Quant Imaging Med Surg* 2019;9(4):590–602. doi:10.21037/qims.2019.02.14, PMID:31143650.
- [37] Rosenkrantz AB, Padhani AR, Chenevert TL, Koh DM, De Keyser F, Taouli B, *et al*. Body diffusion kurtosis imaging: Basic principles, applications, and considerations for clinical practice. *J Magn Reson Imaging* 2015;42(5):1190–1202. doi:10.1002/jmri.24985, PMID:26119267.
- [38] Guiu B, Cercueil JP. Liver diffusion-weighted MR imaging: the tower of Babel? *Eur Radiol* 2011;21(3):463–467. doi:10.1007/s00330-010-2017-y, PMID:2110195.
- [39] Chandarana H, Taouli B. Diffusion and perfusion imaging of the liver. *Eur J Radiol* 2010;76(3):348–358. doi:10.1016/j.ejrad.2010.03.016, PMID:20399054.
- [40] Hong SB, Choi SH, Kim SY, Shim JH, Lee SS, Byun JH, *et al*. MRI Features for Predicting Microvascular Invasion of Hepatocellular Carcinoma: A Systematic Review and Meta-Analysis. *Liver Cancer* 2021;10(2):94–106. doi:10.1159/000513704, PMID:33981625.
- [41] Deng Y, Yang D, Xu H, Ren A, Yang Z. Diagnostic performance of imaging features in the HBP of gadoxetic acid-enhanced MRI for microvascular invasion in hepatocellular carcinoma: a meta-analysis. *Acta Radiol* 2021;2841851211038806. doi:10.1177/02841851211038806, PMID:34459669.
- [42] Min JH, Lee MW, Park HS, Lee DH, Park HJ, Lim S, *et al*. Interobserver Variability and Diagnostic Performance of Gadoxetic Acid-enhanced MRI for Predicting Microvascular Invasion in Hepatocellular Carcinoma. *Radiology* 2020;297(3):573–581. doi:10.1148/radiol.2020201940, PMID:32990512.
- [43] Feng ST, Jia Y, Liao B, Huang B, Zhou Q, Li X, *et al*. Preoperative prediction of microvascular invasion in hepatocellular cancer: a radiomics model using Gd-EOB-DTPA-enhanced MRI. *Eur Radiol* 2019;29(9):4648–4659. doi:10.1007/s00330-018-5935-8, PMID:30689032.
- [44] Chong HH, Yang L, Sheng RF, Yu YL, Wu DJ, Rao SX, *et al*. Multi-scale and multi-parametric radiomics of gadoxetic acid-enhanced MRI predicts microvascular invasion and outcome in patients with solitary hepatocellular carcinoma  $\leq$  5 cm. *Eur Radiol* 2021;31(7):4824–4838. doi:10.1007/s00330-020-07601-2, PMID:33447861.
- [45] Kim BK, Han KH, Park YN, Park MS, Kim KS, Choi JS, *et al*. Prediction of microvascular invasion before curative resection of hepatocellular carcinoma. *J Surg Oncol* 2008;97(3):246–252. doi:10.1002/jso.20953, PMID:18095300.
- [46] Kaibori M, Ishizaki M, Matsui K, Kwon AH. Predictors of microvascular invasion before hepatectomy for hepatocellular carcinoma. *J Surg Oncol* 2010;102(5):462–468. doi:10.1002/jso.21631, PMID:20872949.
- [47] Eguchi S, Takatsuki M, Hidaka M, Soyama A, Tomonaga T, Muraoka I, *et al*. Predictor for histological microvascular invasion of hepatocellular carcinoma: a lesson from 229 consecutive cases of curative liver resection. *World J Surg* 2010;34(5):1034–1038. doi:10.1007/s00268-010-0424-5, PMID:20127241.