Gene Expression **2023** vol. 22(3) | 258–261
DOI: 10.14218/GE.2022.00019

Research Letter

Two Novel Variants of Undetermined Significance in the *ABCC2* Gene Were Identified in a Patient with Dubin-Johnson Syndrome

Ranran Shi[1#], Ning Geng[1#], Zhenzhen Zhao[2], Yong Zhou[3] and Yongning Xin[1*]

[1]*Department of Infectious Diseases, Qingdao Municipal Hospital Affiliated to Dalian Medical University, Qingdao, China;* [2]*Clinical Research Center, Qingdao Municipal Hospital Affiliated to Dalian Medical University, Qingdao, China;* [3]*Qingdao Sixth People's Hospital, Qingdao, Shandong, China*

Received: December 13, 2022 | **Revised:** January 15, 2023 | **Accepted:** June 06, 2023 | **Published online:** July 14, 2023

Dubin-Johnson syndrome (DJS), also known as chronic idiopathic jaundice, black liver-jaundice syndrome, etc. most often develops in adolescents or young adults, and is more common in males, with clinical manifestations of asymptomatic long-term mild-moderate jaundice. The disease belongs to hereditary non-hemolytic jaundice. It is an autosomal recessive genetic disease caused by variants in the ATP-binding cassette subfamily C member (*ABCC2*) gene. It is characterized by intermittent, predominantly conjugated hyperbilirubinemia and liver pigmentation. Routine *ABCC2* gene variant analysis can help in the diagnosis of DJS. In the present study, we reported a patient with Dubin-Johnson syndrome who underwent jaundice-related gene sequencing and identified two novel unknown and significant variants: c.2439+5G>A(p.?) and c.2345_2347del (p.Tyr782_Leu783delinsPhe) of the *ABCC2* gene.

A 27-year-old male patient presented to the hospital with "elevated bilirubin detected 11 years ago". It was established that the patient had elevated bilirubin 11 years ago and complained of total bilirubin up to "100 μmol/L", with the deepening of urine color, mild yellow sclera, no white clay-like stool, no loss of appetite, fatigue, skin itching and other discomforts at that time, no special treatment during the period, and the bilirubin was elevated in several check-ups. Three days ago, the liver function test was performed in our hospital: total bilirubin 73.21 μmol/L, direct bilirubin 53.43 μmol/L, indirect bilirubin 19.78 μmol/L, total serum bile acids 28.50 μmol/L. The patient had a previous history of "peripheral facial nerve palsy and facial muscle spasm (left)", no other past medical history, no history of infectious disease, and no history of drug allergy. Personal history: The patient was born in Boyang County, Jiangxi Province, with no history of contact with epidemic areas or epidemic water, no history of eating raw fish or raw meat, no history of tobacco or alcohol addiction, no history of industrial dust or toxic exposure, etc. The patient is married and has a son, and his wife and child are in good health. Family history: The patient's parents were healthy and denied any history of infectious diseases and tumors in the family. The patient was not aware of his family's genetic history and the authors were unable to make a family genetic map of the patient.

Physical examination: stable vital signs, no yellowing of the skin, mild yellowing of the sclera, no signs of chronic liver disease. There were no obvious positive signs on the abdominal examination. No edema in both lower limbs. The results of relevant ancillary tests were summarized in Table 1. Imaging examinations: CT scan of the whole abdomen showed no significant abnormalities. Ultrasound suggested fatty liver. A liver puncture biopsy showed a large number of pigment granule deposits (Fig. 1).

Further diagnostic work-up: The patient was subsequently sequenced for jaundice-related genes, and two new variants of unknown significance were identified: namely c.2439+5G>A(p.?) and c.2345_2347del(p.Tyr782_Leu783delinsPhe) of the *ABCC2* gene (Fig. 2).

Treatment was given to protect liver function. After treatment, the patient's blood biochemical parameters improved and reached the following values: liver function tests: total protein 63.27 g/L, globulin 19.60 g/L, total bilirubin 62.90 μmo1/L, direct bilirubin 34.80 μmol/L, indirect bilirubin 28.10 μmol/g, total serum bile acids 23.10 μmol/L. In order to observe the patient's long-term prognosis, we recommend that the patient be followed up in the hepatology clinic within 2 weeks after discharge. But the patient did not follow the doctor's orders again for a post-discharge follow-up visit. Therefore, we are currently missing information that could be attained from the patient's follow-up visit.

DJS presents with chronic jaundice and hyperbilirubinemia in the form of conjugated hyperbilirubinemia and is a rare autosomal recessive liver disease without the features of chronic liver disease.[1] DJS is caused by variants in the *ABCC2* gene, which provides instructions for the production of a transporter protein called multidrug resistance protein 2 (MRP2), which is involved in the material export of cells and plays an important role in the secretion of bound bilirubin from hepatocytes into the biliary system. Variants in the *ABCC2* gene result in the under-expression of tubular MRP2, which affects bound bilirubin into the biliary system that in

Abbreviations: *ABCC2*, ATP-binding cassette subfamily C member; DJS, Dubin-Johnson syndrome; MRP2, multidrug resistance protein 2.

*Correspondence to: Yongning Xin, Department of Infectious Diseases, Qingdao Hospital, University of Health and Rehabilitation Sciences (Qingdao Municipal Hospital), No.1 Jiaozhou Road, Qingdao, Shandong 266011, China. ORCID: https://orcid.org/0000-0002-3692-7655. Tel: 0532-88905508, Fax: 0532-85968434, Email: xinyongning@163.com

#These authors contributed equally.

How to cite this article: Shi R, Geng N, Zhao Z, Zhou Y, Xin Y. Two Novel Variants of Undetermined Significance in the *ABCC2* Gene Were Identified in a Patient with Dubin-Johnson Syndrome. *Gene Expr* 2023;22(3):258–261. doi: 10.14218/GE.2022.00019.

© 2023 The Author(s). This article has been published under the terms of Creative Commons Attribution-Noncommercial 4.0 International License (CC BY-NC 4.0), which permits noncommercial unrestricted use, distribution, and reproduction in any medium, provided that the following statement is provided. "This article has been published in *Gene Expression* at https://doi.org/10.14218/GE.2022.00019 and can also be viewed on the Journal's website at https://www.xiahepublishing.com/journal/ge".

Table 1. Laboratory results of this patient

Method	Index	Result
Stool Routine and Occult Blood	OB	–
Routine coagulation tests	PT	10.9S
	APTT	25.7S
Multi-tumor markers	Glycoantigen CA-50	2.46 IU/ml
	Glycoantigen CA-199	4.98 U/ml
Thyroid function tests	FT3	6.28 pmol/L
	FT4	13.12 pmol/L
	TSH	1.78u IU/ml
Copper Blue Protein	Copper Blue Protein	–
Hepatitis B five tests	HBsAg	–
	HBsAb	+
	HBeAg	–
	HBeAb	–
	HBcAb	–
Direct anti-human globulin (Coombs) test	Direct anti-human globulin (Coombs) test	–
ANA antibody spectrum	All items	–
ANCA	All items	–
Autoimmune liver disease antibodies	All items	–
Liver Function	TBIL	77.90 μmol/L
	DBIL	43.20 μmol/L
	IBIL	34.70 μmol/L
	TBA	28.50 μmol/L
	Alb	43.67 g/L
	transferrin saturation	30.82%
	ferritin	264.8 μg/L
Urine Routine	Urine bilirubin	++
Blood routine	MCV	90.20 fl
	platelets	205.00*10^9/L
HCV serology	Hepatitis C virus core antigen	–

–, Negative; +, Positive; Alb, albumin; ANA, Antinuclear antibody; ANCA, Anti-neutrophil cytoplasmic antibody assay; APTT, Partially activated thromboplastin time; DBIL, Direct bilirubin; FT3, Free triiodothyronine; FT4, Free thyroxine; HBcAb, Hepatitis B core antibody; HBeAb, Hepatitis B e antibody; HBeAg, Hepatitis B e antigen; HBsAb, Hepatitis B surface antibody; HBsAg, Hepatitis B surface antigen; HBV, Hepatitis B virus; HCV, Hepatitis C virus; IBIL, Indirect bilirubin; MCV, mean corpuscular volume; PLT, platelets; PT, Prothrombin time; TBIL, Total bilirubin; TSH, Thyroid stimulating hormone.

turn leads to the accumulation of conjugated bilirubin in the hepatocytes, as well as elevated levels of conjugated bilirubin in the blood.[2] DJS has traditionally been considered a benign disease that does not require treatment. However, recent studies have shown that variants in the genes responsible for hyperbilirubinemia, as well as minor genetic variants, may lead to increased sensitivity of the liver to drug toxicity.[3] After the diagnosis of DJS is important to exclude other diseases that may cause liver damage such as biliary obstructive disease, acute or chronic liver injury, intrahepatic cholestasis, and portal shunt.[3] DJS needs to be differentiated from Rotor syndrome, breast milk jaundice, Gilbert-Meulengracht syndrome, hemolysis and other blood disorders, as well as Crigler-Najjar syndrome in addition to other diseases.[4]

In our case, the patient was diagnosed with DJS by combining the medical history, clinical manifestations, and ancillary tests. With the development of sequencing technologies, genetic and epigenetic studies of complex diseases are becoming more common. *ABCC2* variants found in DJS patients include gene deletions, missense variants, nonsense variants, and splice site variants.[5] Such variants now include the c.2439+5G>A(p.?) of the *ABCC2* gene found in this patient. The variant is a minor variant in the intron region. Although there is no inclusion in the following; literature in the HGMD database; the thousand genomes (1000g2015aug_ALL) database, ESP6500siv2_ALL or dbSNP147 database, bio-

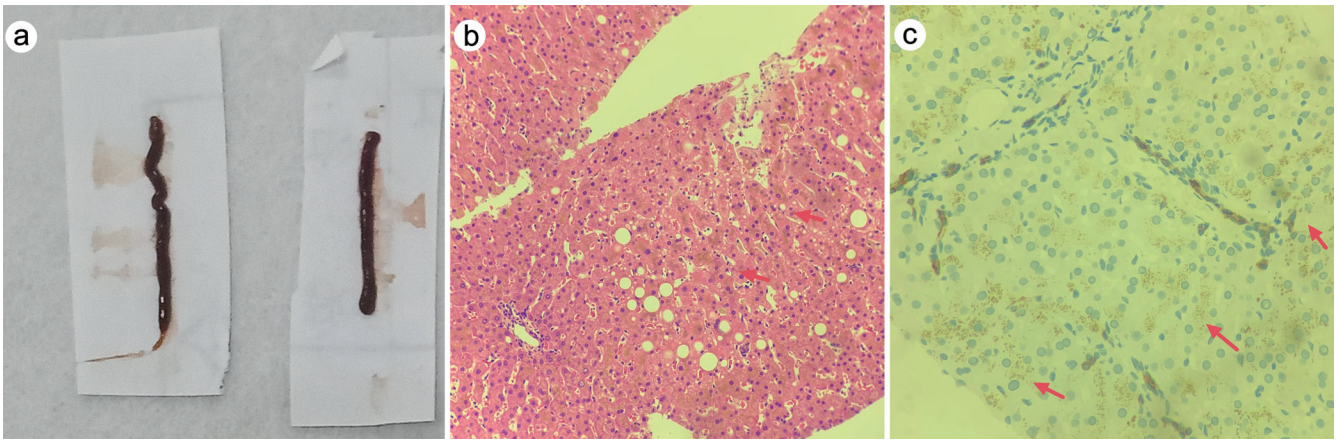

Fig. 1. Results of a liver puncture biopsy. (a) Liver biopsy specimen of the patient Visually, the liver tissue is darker than normal liver tissue; (b) Hematoxylin and eosin staining (original magnification ×10) shows large deposits of pigment particles (red arrows); (c) Immunohistochemistry of the liver tissue also shows large deposits of pigment particles (red arrows).

informatics software predicts that the variant significantly affects mRNA splicing. According to previous studies, many sequence variants are single nucleotide changes in introns or exons that do not result in amino acid changes and therefore may have no functional impact.[6] The clinical significance of c.2439+5G>A(p.?) is not yet clear. Furthermore, the c.2345_2347del(p.Tyr782_Leu783delinsPhe) of the *ABCC2* gene is a minor deletion insertion variant (expected to result in a deletion at amino acids 782 to 783 of the encoded protein and the Phe was inserted into the position), which was not previously reported in the HGMD database, the thousand genomes (1000g2015aug_ALL) database, the ESP6500siv2_ALL or the dbSNP147 databases. The clinical significance of c.2345_2347del (p.Tyr782_Leu783delinsPhe) cannot yet be clarified. Based on previous research results, the authors hypothesized that such small deletion insertion variants may result in apical localization of *ABCC2* proteins that are either not func-

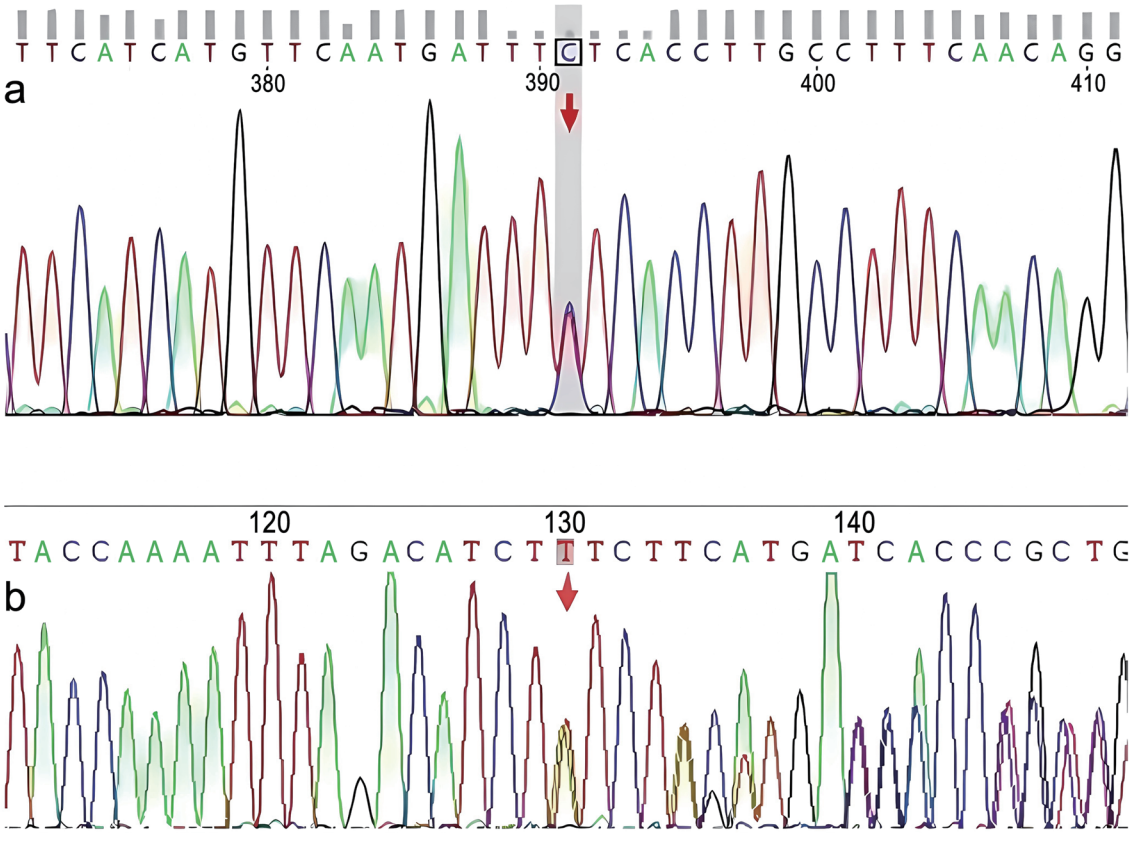

Fig. 2. Gene sequencing results of this patient. (a) c.2439+5G>A(p.?); (b) c.2345_2347del(p.Tyr782_Leu783delinsPhe).

tionally active or cause a lack of maturation and impaired sorting of *ABCC2* proteins.[6]

Lina Wu *et al.* found at least one nonsynonymous variant in the *ABCC2* gene in all Chinese DJS patients.[7] The variants that have been identified are all heterozygous, with only two cases having complex heterozygous variants, suggesting the involvement of other clinically relevant *ABCC2* variants. Two novel pure heterozygous variants have been identified abroad, c.1013_1014delTG and 974C->G, located in the eighth exon of the *ABCC2* gene, but relatively few genetic analyses of DJS cases have been performed in China.[6,8–10] In the present report, the variants in the patient were confirmed by gene sequencing to be c.2439+5G>A(p.?) and c.2345_2347del (p.Tyr782_Leu783delinsPhe) that belonged to heterozygous variants and were identified as variants of undetermined significance. DJS cases carrying c.2345_2347del(p.Tyr782_Leu783delinsPhe) and c.2439+5G>A(p.?) of the *ABCC2* gene, as well as other variants of undetermined significance may be associated with additional *ABCC2* variants in hereditary or metabolic liver disease. Reporting novel variants of the *ABCC2* gene variant in DJS could help reduce the rate of under- and misdiagnosis of the disease. Evaluation of rare, potentially *ABCC2* variants could contribute to genetic studies of DJS.

Acknowledgments

None to declare.

Funding

This study was supported by a grant from the National Natural Science Foundation of China (No. 32171277).

Conflict of interest

The authors have no conflict of interests related to this publication.

Author contributions

Treating the patient (RRS, NG and YNX); drafting the manuscript (RRS and NG); assisting in writing the manuscript (ZZZ); supervising and editing the manuscript (YNX). All authors have read and agreed to the final manuscript.

Ethical statement

Written informed consent for publication was obtained from this participant in this study.

References

[1] Corpechot C, Barbu V, Chazouillères O, Broué P, Girard M, Roquelaure B, *et al*. Genetic contribution of ABCC2 to Dubin-Johnson syndrome and inherited cholestatic disorders. Liver Int 2020;40(1):163–174. doi:10.1111/liv.14260, PMID:31544333.

[2] Lyu Y, Wei X, Xu J, Gao M, Zhang K, Liu Y, *et al*. Diagnosis of a patient with Dubin-Johnson syndrome by using next generation sequencing. Zhonghua Yi Xue Yi Chuan Xue Za Zhi 2019;36(3):242–245. doi:10.3760/cma.j.issn.1003-9406.2019.03.012, PMID:30835355.

[3] Moinuddin O, Wood EH, Drenser KA. Adult Coats' Disease, Dubin-Johnson Syndrome, and the Search for Targeted Therapies. Ophthalmic Surg Lasers Imaging Retina 2019;50(5):318–321. doi:10.3928/23258160-20190503-10, PMID:31100164.

[4] Junge N, Goldschmidt I, Wiegandt J, Leiskau C, Mutschler F, Laue T, *et al*. Dubin-Johnson Syndrome as Differential Diagnosis for Neonatal Cholestasis. J Pediatr Gastroenterol Nutr 2021;72(5):e105–e111. doi:10.1097/MPG.0000000000003061, PMID:33534365.

[5] Wu L, Li Y, Song Y, Zhou D, Jia S, Xu A, *et al*. A recurrent ABCC2 p.G693R mutation resulting in loss of function of MRP2 and hyperbilirubinemia in Dubin-Johnson syndrome in China. Orphanet J Rare Dis 2020;15(1):74. doi:10.1186/s13023-020-1346-4, PMID:32183854.

[6] Nies AT, Keppler D. The apical conjugate efflux pump ABCC2 (MRP2). Pflugers Arch 2007;453(5):643–659. doi:10.1007/s00424-006-0109-y, PMID:16847695.

[7] Wu L, Zhang W, Jia S, Zhao X, Zhou D, Xu A, *et al*. Mutation analysis of the ABCC2 gene in Chinese patients with Dubin-Johnson syndrome. Exp Ther Med 2018;16(5):4201–4206. doi:10.3892/etm.2018.6682, PMID:30344695.

[8] Martínez-Solís M, Pinos D, Endo H, Portugal L, Sato R, Ferré J, *et al*. Role of Bacillus thuringiensis Cry1A toxins domains in the binding to the ABCC2 receptor from Spodoptera exigua. Insect Biochem Mol Biol 2018;101:47–56. doi:10.1016/j.ibmb.2018.07.006, PMID:30077769.

[9] Corpechot C, Ping C, Wendum D, Matsuda F, Barbu V, Poupon R. Identification of a novel 974C—>G nonsense mutation of the MRP2/ABCC2 gene in a patient with Dubin-Johnson syndrome and analysis of the effects of rifampicin and ursodeoxycholic acid on serum bilirubin and bile acids. Am J Gastroenterol 2006;101(10):2427–2432. doi:10.1111/j.1572-0241.2006.00695.x, PMID:16952291.

[10] Huynh MT, Chrétien Y, Grison S, Delaunay JL, Lascols O, Tran CT, *et al*. Novel compound heterozygous ABCC2 variants in patients with Dubin-Johnson syndrome and intrahepatic cholestasis of pregnancy. Clin Genet 2018;94(5):480–481. doi:10.1111/cge.13420, PMID:30092126.