



## Repurposing Pirfenidone for Nonalcoholic Steatohepatitis-related Cirrhosis: A Case Series

Cyriac Abby Philips<sup>\*1</sup>, Guruprasad Padsalgi<sup>2</sup>, Rizwan Ahamed<sup>2</sup>, Rajaguru Paramaguru<sup>3</sup>, Sasidharan Rajesh<sup>4</sup>, Tom George<sup>4</sup>, Pushpa Mahadevan<sup>5</sup> and Philip Augustine<sup>2</sup>

<sup>1</sup>The Liver Unit and Monarch Liver Lab, Cochin Gastroenterology Group, Ernakulam Medical Centre, Kochi, Kerala, India; <sup>2</sup>Department of Gastroenterology, Cochin Gastroenterology Group, Ernakulam Medical Centre, Kochi, Kerala, India; <sup>3</sup>Department of Pathology, Al Salam International Hospital, Bneid Al Qar, Kuwait, India; <sup>4</sup>Department of Diagnostic and Interventional Radiology, Department of Gastroenterology and The Liver Unit, Cochin Gastroenterology Group, Ernakulam Medical Centre, Kochi, Kerala, India; <sup>5</sup>Department of Clinical Pathology, VPS Lakeshore Hospital, Kochi, Kerala, India

### Abstract

We repurposed the antifibrotic drug pirfenidone—which is approved for treatment of idiopathic lung fibrosis—in a series of patients with nonalcoholic steatohepatitis-related cirrhosis. Our report demonstrates the observed improvements in necroinflammation and regression of cirrhosis with pirfenidone use for 12-weeks, associated with classical hepatic repair complex features on follow-up liver biopsies. This novel work could help stimulate further randomized trials of pirfenidone in patients with nonalcoholic steatohepatitis-related liver fibrosis or cirrhosis, for whom no recommended drug treatments exists currently.

**Citation of this article:** Philips CA, Padsalgi G, Ahamed R, Paramaguru R, Rajesh S, George T, *et al.* Repurposing pirfenidone for nonalcoholic steatohepatitis-related cirrhosis: A case series. *J Clin Transl Hepatol* 2020;8(1):100–105. doi: 10.14218/JCTH.2019.00056.

### Introduction

Regression of cirrhosis has been demonstrated with antiviral therapy in patients with chronic hepatitis B and hepatitis C virus infections and with immunosuppressants in autoimmune hepatitis.<sup>1</sup> Pharmacological therapies leading to regression of nonalcoholic steatohepatitis (NASH)-related cirrhosis have not been demonstrated. We present here proof-of-concept in regression of NASH-cirrhosis, through serial liver biopsies, achieved by repurposing the antifibrotic drug pirfenidone (PFD) in three patients.

### Case report

Patient-1 is a 30 year-old overweight male, with occasional alcohol intake, abstinent for 18 months after diagnosis of chronic liver disease, and with a family history of diabetes mellitus and cirrhosis. Patient-2 is a 49 year-old overweight

female with hypothyroidism and family history of diabetes mellitus, fatty liver disease and dyslipidemia. Patient-3 is a 58 year-old obese female with dyslipidemia, diabetes mellitus, hypothyroidism and systemic hypertension, with family history of fatty liver disease and coronary artery disease. All three patients had biopsy-proven NASH cirrhosis (percutaneous, right lobe only, 16-gauge cutting needle, minimum of five un-fragmented cores, each with minimum length of 20mm and with at least 10 identifiable portal tracts) in the absence of portal hypertension. Other causes for chronic liver disease, including chronic viral hepatitis, alcoholic liver disease, Wilson's disease, autoimmune hepatitis, chronic cholestatic liver disease and hemochromatosis, were explicitly ruled out as per standard diagnostic recommendations.

All three patients were started on PFD (Pirfenex<sup>®</sup>; Cipla, India) at 200mg thrice daily for 12 weeks. All underwent Shearwave elastography (LOGIQ E9; GE-Healthcare, USA) as per manufacturer's guideline recommendation, with at least 4 h of fasting prior to the procedure at baseline and after 12 weeks post-therapy. The right lobe of the liver was chosen for stiffness measurement in all patients, with 10 readings taken by the same radiologist; the final result was generated by the system software as an average (kPa). Liver function tests were performed once weekly for the first 4 weeks and once monthly thereafter. Patients were monitored for adverse events through monthly telephonic interview.

Percutaneous liver biopsy was performed in all three patients at the end of 12 weeks (in view of liver stiffness measurement changes noted at this arbitrary time point) and compared to baseline. Two trained liver pathologists who were blinded to the treatment but not to the patients assessed the liver biopsies, working independently. Informed consent was obtained from all patients included in the study, prior to the start of PFD therapy and before baseline and follow-up liver biopsy procedures. The study was approved by the Institutional Ethics and Review Committee and all protocols conformed to the ethical guidelines as laid out by the Declaration of Helsinki and its latest amendments. The complete patient details at baseline and end of 12 weeks are shown in Table 1.

### Results

Post-treatment, at the end of 12 weeks, in the absence of intentional weight loss (exercise regimen- and dietary

**Keywords:** NASH; Fibrosis; Antifibrotic; Hepatitis; Pirfenidone.

**Abbreviations:** NASH, nonalcoholic steatohepatitis; PFD, pirfenidone.

Received: 28 November 2019; Revised: 4 January 2020; Accepted: 17 January 2020

**\*Correspondence to:** Cyriac Abby Philips, Philips Augustine Associates, The Liver Unit and Monarch Liver Lab, Cochin Gastroenterology Group, Ernakulam Medical Centre, Palarivattom, Cochin 682025, Kerala, India. E-mail: abbyphilips@gmail.com

**Table 1. Baseline and follow-up parameters of all three patients with nonalcoholic fatty liver disease-related cirrhosis on pirfenidone treatment**

Parameters	Patient-1	Patient-2	Patient-3
Age in years	30	49	58
Sex	Male	Female	Female
Height in cm	168	154	152
Weight in kg, at baseline / 12 weeks	79 / 78	72 / 73	81 / 79
Body mass index in kg/m <sup>2</sup> , at baseline / 12 weeks	28 / 27.6	30.4 / 30.8	35.1 / 34.2
Associated chronic diseases	None	Hypothyroidism	Dyslipidemia, diabetes mellitus, hypothyroidism, systemic hypertension
Associated drug intake, dose (duration)	None	Thyroxine 75 mcg once daily (14 years)	Rosuvastatin 10 mg (10 years), metformin 1000 mg (10 years), glimepiride 1 mg (4 years), thyroxine 50 mcg (8 years), metoprolol 50 mg (3 years)
Hemoglobin in g/L, at baseline / 12 weeks	12.2 / 11.8	13.4 / 13	11.8 / 12.1
Total leucocyte count as $\times 10^9$ /L, at baseline / 12 weeks	5.6 / 6.4	7.2 / 6.7	6.2 / 7.0
Platelet count as $\times 10^3$ / $\mu$ L, at baseline / 12 weeks	220 / 230	210 / 194	260 / 272
Total bilirubin in mg/dL, at baseline / 12 weeks	0.8 / 1.1	1.2 / 0.9	1.2 / 0.9
Direct bilirubin in mg/dL, at baseline / 12 weeks	0.4 / 0.6	0.8 / 0.4	0.3 / 0.4
Aspartate transaminase in IU/L, at baseline / 12 weeks	54 / 48	62 / 60	78 / 56
Alanine transaminase in IU/L, at baseline / 12 weeks	112 / 74	98 / 78	102 / 44
Alkaline phosphatase in IU/L, at baseline / 12 weeks	98 / 88	84 / 92	78 / 92
$\gamma$ -Glutamyl transpeptidase in IU/L, at baseline / 12 weeks	42 / 54	38 / 72	62 / 44
Serum albumin in g/dL, at baseline / 12 weeks	4.2 / 4.1	4.4 / 4.1	4.2 / 3.9
Serum creatinine in mg/dL, at baseline / 12 weeks	0.8 / 1.1	0.9 / 0.6	1.0 / 0.9
Serum sodium in mmol/L, at baseline / 12 weeks	141 / 140	139 / 140	138 / 136
Serum potassium in mmol/L, at baseline / 12 weeks	4.2 / 3.8	4.1 / 4.0	4.5 / 4.8
International normalized ratio, at baseline / 12 weeks	1.1 / 0.9	1 / 1.2	1.2 / 1.2
HbA1c, at baseline / 12 weeks	5.6 / 6.1	6.1 / 5.9	7.4 / 7.8
APRI score, at baseline / 12 weeks <sup>1*</sup>	0.61 / 0.52	0.78 / 0.77	0.75 / 0.51
FIB4 score, at baseline / 12 weeks <sup>2*</sup>	0.7 / 0.73	1.46 / 1.72	1.72 / 1.8
Shearwave elastography in kPA, at baseline / 12 weeks	22.4 / 7.8	18.6 / 9.8	9.4 / 10.2
NAFLD activity score (known as NAS)	5 / 2	5 / 3	5 / 4
Steatosis-Activity-Fibrosis (known as SAF) score, at baseline / 12 weeks	S2A2F4 / S0A0F3	S2A2F4 / S0A1F4	S1A4F4 / S0A2F3

\*Noninvasive scores like the aspartate aminotransferase-to-platelet ratio index (APRI) and the Fibrosis-4 score (FIB4) have been studied and fully validated in patients with chronic hepatitis C and in patients with hepatitis C and human immunodeficiency virus-related coinfection and not in patients with NASH-cirrhosis, and have low diagnostic accuracy when used alone.

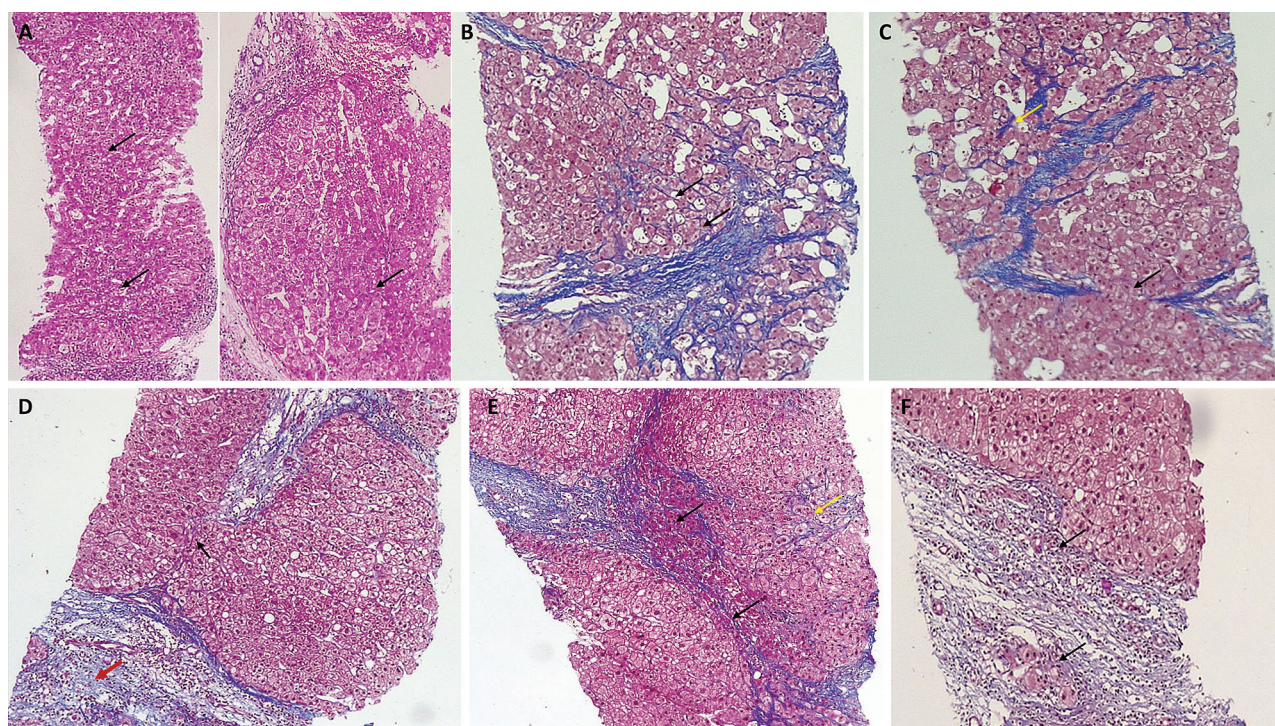
restriction-based), substantial reduction in liver elastography values were notable in two patients and a reduction in alanine transaminase was notable in all three patients. The liver biopsy evaluation revealed amelioration in steatosis as well as inflammation, associated with features of cirrhosis regression, such as thinning and perforation of fibrous septae, presence of isolated thick collagen fibers, delicate periportal spikes, clusters of hepatocytes within portal tracts, splitting of septa by hepatocytes and loss of distinction of hepatic nodules; components of the 'hepatic repair complex' were observed, in varying degrees, in all three patients (Fig. 1).<sup>1</sup> The complete representational images of pre- and post-treatment liver biopsies of all three patients are shown in the Supplementary Figs. 1–6. No adverse events were reported. However, Patient-1 and Patient-3 reported unintentional weight loss (of approximately 2.2 kg at 12 weeks) in the absence of dietary restrictions, anorexia and exercise regimen.

## Discussion

PFD is an orally bioavailable pyridone derivative, approved for the treatment of idiopathic pulmonary fibrosis. Oral PFD is rapidly absorbed, reaching maximal concentration at 30 min in fasted, older adults, having a terminal half-life of 2.5 h. PFD is primarily metabolized through the cytochrome P450 enzyme CYP1A2 and excreted through urine. Several high-quality

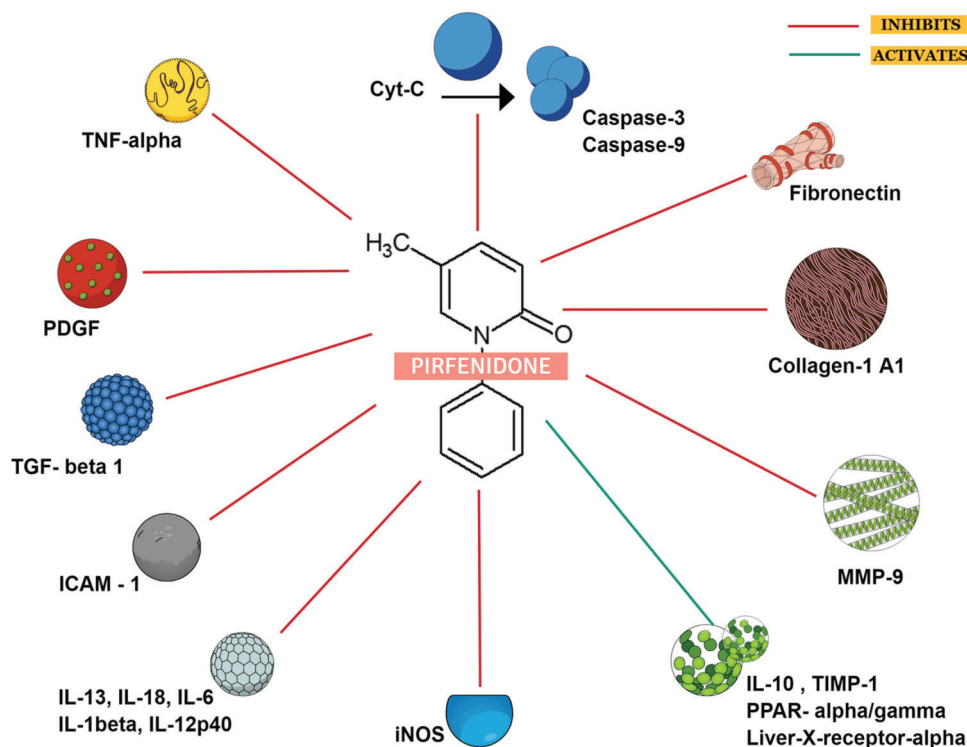
studies on the anti-inflammatory and antifibrotic effects of PFD in small animal models of bleomycin-induced lung fibrosis, cardiac, renal and hepatic fibrosis, and allergen-induced airway-remodeling have been published.<sup>2</sup> PFD exerts multifaceted actions on inflammatory and fibrosis mediators to improve inhibitory effects on multiple pathways, which ultimately lead to liver fibrosis (Fig. 2).

PFD was shown to reduce hepatocyte apoptosis and tumor necrosis factor- $\alpha$ -related fibrogenesis and to markedly attenuate liver fibrosis in a rodent model of human NASH.<sup>3</sup> It was also recently demonstrated that prolonged release PFD in an animal model of NASH led to increase in the peroxisome proliferator-activated receptors- $\gamma$  and - $\alpha$  and liver -X receptor- $\alpha$ -related metabolic transcriptional factors, causing a reduction in steatosis, and down-regulation of transforming growth factor- $\beta$ 1, nuclear factor- $\kappa$ B and interleukins-1, -6 and -17A eliciting antifibrotic effects.<sup>4</sup> In a pilot trial, patients with chronic hepatitis C virus-related advanced liver fibrosis were given 1200mg/day of PFD for 1 year. The authors found that there was marked reduction in necrosis, inflammation and steatosis on follow-up biopsy, along with liver cell regeneration (measured by antiproliferating cell nuclear antigen immunostaining). Fibrosis was reduced in 30% of patients at the end of 1 year and mRNAs coding for profibrogenic molecules, such as collagen type I  $\alpha$ -1, transforming growth factor- $\beta$ 1 and tissue inhibitors of metalloproteinases, were markedly down-regulated by the end of treatment.<sup>5</sup>



**Fig. 1. Percutaneous liver biopsy features showing various components of the hepatic repair complex in patients with nonalcoholic steatohepatitis-related cirrhosis after a 12-week course of pirfenidone.**

(A) Loss of distinct nodularity and absence of steatosis (black arrows; H&E stain, 40x). (B) Thinning of fibrous septa with delicate periportal spikes (arrows; MTS, 100x). (C) Splitting of thinned out fibrous septa by clusters of hepatocytes (black arrow; MTS, 100x), with isolated dense bands of collagen (yellow arrow). (D) Pale staining of edematous resorptive septa, with loss of fibrous appearance (red arrow; MTS, 100x). (D, E) Thinned and perforated fibrous septae (black arrows; MTS, 100x). (E, F) Clusters of hepatocytes and hepatocyte buds within areas of fibrosis regression (E, yellow arrow and F, black arrows; MTS, 100x). H&E, hematoxylin and eosin stain; MTS, Masson's trichrome stain.



**Fig. 2. Multiple anti-inflammatory and antifibrotic effects of pirfenidone on advanced liver disease confirmed in studies based on cell culture and small animal models.**

Abbreviations: Cyt-C, cytochrome C; ICAM, intercellular adhesion molecule 1; IL, interleukin; iNOS, inducible nitric oxide synthase; MMP, matrix metalloproteinase; PDGF, platelet-derived growth factor; PPAR, peroxisome proliferator-activated receptors; TNF, tumor necrosis factor; TGF, transforming growth factor; TIMP, tissue inhibitor of metalloproteinases.

Angulo *et al.*<sup>6</sup> studied the utility of PFD (2400 mg/day for 12 months) in patients with primary sclerosing cholangitis. They found no significant changes in liver biochemistries, Mayo risk score, degree of inflammation, fibrosis nor histologic changes in the treated patients at end of 1 year but found adverse events (gastrointestinal symptoms and skin rash) in 83% (which disappeared shortly after stopping PFD) of treated patients. This study, however, used a very high dose of PFD and overlooked cholangitis episodes and other factors that promoted worsening of primary sclerosing cholangitis. A critical review on effects of PFD in animal models of liver fibrosis and clinical trials in humans is shown in Table 2.

To date, there are no drug treatments that promote regression of NASH-cirrhosis. Glass *et al.*<sup>7</sup> has shown reversal of advanced NASH fibrosis in patients who lost  $\geq 10\%$  total body weight through bariatric and nonsurgical methods. However, achieving such targets through rigorous exercise (the ideal dose yet to be defined) or through surgery may not be universally possible or acceptable. Of the 47 drugs that are currently in various phases of clinical trials for the treatment of NASH, none are postulated or demonstrated to target reversal of cirrhosis. Considering the fact that a reasonable number of these potential therapeutic agents are in very early testing phases, it is safe to assume that a long wait is required before the next generation of NASH drugs are available for clinical use. In this regard, drug repurposing becomes the need of the hour.<sup>8</sup>

Our report is of a small case series and may not be adequately powered to identify efficacy of PFD in NASH-

related advanced liver disease. However, even though not very conclusive, our findings are strong enough to stimulate further studies on PFD in advanced NASH-fibrosis/cirrhosis. It may be argued that the reduction in fibrosis observed in our study could be due to sampling error, but other features of the hepatic repair complex were strikingly evident in all our treated patients, being highly suggestive of PFD-related regression of cirrhosis independent of weight loss or dietary restrictions. Drug-induced weight loss is a known event with PFD use, and this in itself could have caused reversal features of cirrhosis, independent of a direct drug effect.<sup>9</sup>

Verma *et al.*<sup>10</sup> demonstrated acute liver failure due to PFD in an elderly male, aged 77 years, with idiopathic pulmonary fibrosis and multiple comorbidities, including Parkinson's disease. This single report, however, did not consider drug-drug interactions of PFD with other medications ingested by the patient that could have potentiated the liver injury, as was shown in a report by Benesic *et al.*<sup>11</sup> (also in an elderly male, aged 75 years) which featured the concomitant use of esomeprazole. In our patient, simultaneous use of other medications was well documented and adverse events associated with PFD was not seen at 3 months. Ideally, Sirius red and smooth muscle actin staining for quantification of collagen and the fibrotic area needs to be performed to demonstrate fibrosis regression; unfortunately, the technology and image analysis software for such was lacking at our facility.

Future studies assessing fibrosis regression with off-label or experimental drug use for NASH should ideally include

**Table 2. Small animal model and human subject clinical study on efficacy of pirfenidone in liver fibrosis**

Author / Year	Study	Findings	Comments
Animal models			
Tada <i>et al.</i> / 2001	<ul style="list-style-type: none"> <li>• Dimethyl nitrosamine rat model of fibrosis</li> <li>• 500 mg/kg, oral gavage</li> </ul>	<ul style="list-style-type: none"> <li>• 40% decrease in fibrotic area</li> <li>• Significant reduction in liver hydroxyproline content</li> <li>• Significant reduction in expression of collagen 1 mRNA</li> </ul>	
Garcia <i>et al.</i> / 2002	<ul style="list-style-type: none"> <li>• Carbon-tetrachloride mouse model of cirrhosis</li> <li>• One group received pirfenidone after discontinuation of carbon-tetrachloride</li> <li>• Second group received pirfenidone along with carbon-tetrachloride</li> <li>• Additional group of bile duct ligation rat model of cirrhosis</li> </ul>	<ul style="list-style-type: none"> <li>• Pirfenidone use resulted in 70% reduction in fibrosis staining from baseline when used after stopping carbon-tetrachloride</li> <li>• Pirfenidone use resulted in 40% reduction in fibrosis staining from baseline when used along with carbon-tetrachloride</li> <li>• Total liver hydroxyproline levels reduced by 40%</li> <li>• Number of hepatic stellate cells reduced significantly</li> </ul>	<ul style="list-style-type: none"> <li>• Increased survival when compared to placebo due to less liver-related events</li> </ul>
Di Sario <i>et al.</i> / 2004	<ul style="list-style-type: none"> <li>• Dimethyl nitrosamine rat model of fibrosis/cirrhosis</li> <li>• Pirfenidone (0.5% of liquid diet) dosed at weeks 3 to 5 in a 5-week model</li> </ul>	<ul style="list-style-type: none"> <li>• 70% reduction in fibrosis staining area</li> <li>• Significant reduction in alanine transaminase, necroinflammatory score, hepatic stellate cell accumulation</li> <li>• Transforming growth factor-beta expression decreased significantly</li> <li>• Procollagen-1 mRNA expression decreased</li> </ul>	
Salazar-Montes <i>et al.</i> / 2008	<ul style="list-style-type: none"> <li>• Carbon-tetrachloride rat model of fibrosis</li> <li>• Bile duct ligation rat model of cirrhosis</li> <li>• 200 mg/kg</li> <li>• Control group – placebo</li> </ul>	<ul style="list-style-type: none"> <li>• Liver fibrosis decreased by 40%</li> <li>• Collagen 1 mRNA expression decreased</li> <li>• Nitrite and malondialdehyde, superoxide dismutase and catalase mRNA levels (markers of oxidative stress) reduced in the liver</li> </ul>	<ul style="list-style-type: none"> <li>• Markers of liver injury: transaminases and total bilirubin decreased significantly compared to controls</li> </ul>
Human studies			
Angulo <i>et al.</i> / 2002	<ul style="list-style-type: none"> <li>• Primary sclerosing cholangitis</li> <li>• <i>n</i> = 24</li> <li>• 12-month study duration</li> <li>• 2400 mg/day</li> </ul>	<ul style="list-style-type: none"> <li>• No improvements in necroinflammation, fibrosis, Mayo risk score, bile duct changes on imaging</li> <li>• 75% gastrointestinal adverse events, 46% severe fatigue, 42% photosensitive rash</li> <li>• Discontinuation of pirfenidone in 50% patients</li> </ul>	<ul style="list-style-type: none"> <li>• Very high dose of pirfenidone utilized</li> <li>• Ideal dose finding not performed</li> <li>• Pathophysiology of primary sclerosing cholangitis not wholly targeted</li> <li>• Cholangitis episodes, dominant strictures and other clinical events that could worsen primary sclerosing cholangitis not looked into in depth</li> </ul>
Armendariz-Borunda <i>et al.</i> / 2006	<ul style="list-style-type: none"> <li>• Hepatitis C virus-related advanced fibrosis</li> <li>• <i>n</i> = 15</li> <li>• 12-month study duration</li> <li>• 1200 mg/day</li> </ul>	<ul style="list-style-type: none"> <li>• Reduction in necroinflammatory scores, liver steatosis, fibrosis</li> <li>• Collagen 1-A1 protein expression, transforming growth factor-beta expression and tumor necrosis factor-<math>\alpha</math> levels were reduced significantly at end of 1 year</li> <li>• Gastrointestinal and photosensitivity in 15%</li> <li>• Complete resolution of adverse events after 2 to 3 months of therapy</li> </ul>	<ul style="list-style-type: none"> <li>• Uncontrolled study</li> <li>• Associated factors that affected improvement in liver fibrosis and necroinflammation not looked into</li> </ul>

quantification analyses with methods/technologies that have more subjective acceptance and better reproducibility. Other biomarker combinations, such as those obtained by the Fibrotest® or Enhanced Liver Fibrosis™ test and ProC3, were also not available at our hospital; regardless, they are not yet validated in Indian patients with advanced NASH-fibrosis. However, the presence of serial liver biopsies (gold standard) along with the findings from the validated method for liver stiffness assessment in our patients add to the improvement in the objective findings of our study.

### Conclusions

Even though our case series of three patients with conclusions that are based on raw observations require future, prospective, randomized placebo-controlled trials to confirm our findings related to regression of cirrhosis with use of PFD, our study has demonstrated a proof-of-concept in regression of NASH-cirrhosis with 12-week use of low-dose PFD. This could stimulate initiation of clinical trials to evaluate the repurposing of low- or high-dose of PFD given in the intermediate or long term for early and advanced NASH fibrosis, which could eventually become an important component in the armamentarium of treatments against NASH.

### Funding

None to declare.

### Conflict of interest

The authors have no conflict of interests related to this publication.

### Author contributions

Study concept and design (CAP, GP), acquisition of data (RA, RP, PM, SR, TG), analysis and interpretation of data (CAP, GP,

PA, PM, RP), drafting of the manuscript (CAP, GP), critical revision of the manuscript for important intellectual content (CAP, GP, RA, RP, SR, TG, PM, PA).

### References

- [1] Hytioglou P, Theise ND. Regression of human cirrhosis: an update, 18 years after the pioneering article by Wanless *et al*. *Virchows Arch* 2018;473:15–22. doi: 10.1007/s00428-018-2340-2.
- [2] Macías-Barragán J, Sandoval-Rodríguez A, Navarro-Partida J, Armendáriz-Borunda J. The multifaceted role of pirfenidone and its novel targets. *Fibrogenesis Tissue Repair* 2010;3:16. doi: 10.1186/1755-1536-3-16.
- [3] Komiya C, Tanaka M, Tsuchiya K, Shimazu N, Mori K, Furuke S, *et al*. Antifibrotic effect of pirfenidone in a mouse model of human nonalcoholic steatohepatitis. *Sci Rep* 2017;7:44754. doi: 10.1038/srep44754.
- [4] Armendariz-Borunda J, Rodriguez-Echevarria R, Macias-Barragan J, Mendivil-Rangel E, Vera-Cruz J, Garcia-Banuelos J. Prolonged-release pirfenidone is a dual activator for PPARalpha and PPARgamma and improves NASH features induced by high fat/carbohydrate diet. *J Hepatol* 2017;66:S605.
- [5] Armendáriz-Borunda J, Islas-Carbajal MC, Meza-García E, Rincón AR, Lucano S, Sandoval AS, *et al*. A pilot study in patients with established advanced liver fibrosis using pirfenidone. *Gut* 2006;55:1663–1665. doi: 10.1136/gut.2006.107136.
- [6] Angulo P, MacCarty RL, Sylvestre PB, Jorgensen RA, Wiesner RH, LaRusso NA, *et al*. Pirfenidone in the treatment of primary sclerosing cholangitis. *Dig Dis Sci* 2002;47:157–161. doi: 10.1023/a:1013240225965.
- [7] Glass LM, Dickson RC, Anderson JC, Suriawinata AA, Putra J, Berk BS, *et al*. Total body weight loss of ≥ 10 % is associated with improved hepatic fibrosis in patients with nonalcoholic steatohepatitis. *Dig Dis Sci* 2015;60:1024–1030. doi: 10.1007/s10620-014-3380-3.
- [8] Sookoian S, Pirola CJ. Repurposing drugs to target nonalcoholic steatohepatitis. *World J Gastroenterol* 2019;25:1783–1796. doi: 10.3748/wjg.v25.i15.1783.
- [9] Cottin V, Maher T. Long-term clinical and real-world experience with pirfenidone in the treatment of idiopathic pulmonary fibrosis. *Eur Respir Rev* 2015; 24:58–64. doi: 10.1183/09059180.00011514.
- [10] Verma N, Kumar P, Mitra S, Taneja S, Dhooria S, Das A, *et al*. Drug idiosyncrasy due to pirfenidone presenting as acute liver failure: Case report and mini-review of the literature. *Hepatol Commun* 2017;2:142–147. doi: 10.1002/hep4.1133.
- [11] Benesic A, Jalal K, Gerbes AL. Acute liver failure during pirfenidone treatment triggered by co-medication with esomeprazole. *Hepatology* 2019;70:1869–1871. doi: 10.1002/hep.30684.