

Treatment of Hepatitis C in Patients Undergoing Immunosuppressive Drug Therapy

Kohtaro Ooka¹ and Joseph K. Lim*²

¹Department of Internal Medicine, Yale University School of Medicine, New Haven, CT, USA; ²Yale Liver Center, Section of Digestive Diseases, Yale University School of Medicine, New Haven, CT, USA

Abstract

With 185 million people chronically infected globally, hepatitis C is a leading bloodborne infection. All-oral regimens of direct acting agents have superior efficacy compared to the historical interferon-based regimens and are significantly more tolerable. However, trials of both types of regimens have often excluded patients on immunosuppressive medications for reasons other than organ transplantation. Yet, these patients—most often suffering from malignancy or autoimmune diseases—could stand to benefit from these treatments. In this study, we systematically review the literature on the treatment of hepatitis C in these neglected populations. Research on patients with organ transplants is more robust and this literature is reviewed here non-systematically. Our systematic review produced 2273 unique works, of which 56 met our inclusion criteria and were used in our review. The quality of data was low; only 3 of the 56 studies were randomized controlled trials. Sustained virologic response was reported sporadically. Interferon-containing regimens achieved this end-point at rates comparable to that in immunocompetent individuals. Severe adverse effects and death were rare. Data on all-oral regimens were sparse, but in the most robust study, rates of sustained virologic response were again comparable to immunocompetent individuals (40/41). Efficacy and safety of interferon-containing regimens and all-oral regimens were similar to rates

in immunocompetent individuals; however, there were few interventional trials. The large number of case reports and case series makes conclusions vulnerable to publication bias. While firm conclusions are challenging, given the dearth of high-quality studies, our results demonstrate that antiviral therapy can be safe and effective. The advent of all-oral regimens offers patients and clinicians greatly increased chances of cure and fewer side effects. Preliminary data reveal that these regimens may confer such benefits in immunosuppressed individuals as well. More prospective interventional trials would greatly benefit the many patients with chronic hepatitis C on immunosuppressive therapies.

© 2016 The Second Affiliated Hospital of Chongqing Medical University. Published by XIA & HE Publishing Inc. All rights reserved.

Introduction

Background

More than 185 million people are chronically infected with hepatitis C virus (HCV) globally.¹ In the United States and Canada, an estimated 4.4 million persons have chronic HCV infection. Chronic hepatitis C is associated with substantial morbidity and mortality due to progressive liver fibrosis, liver cirrhosis, liver cancer, liver failure and need for liver transplantation. Recent advances in antiviral therapy based on all-oral, interferon (IFN)-free regimens with direct acting antiviral agents (DAAs) have resulted in significant improvements in safety and viral eradication rates, also known as sustained virologic response (SVR). However, outside of the organ transplant context, very limited data are available that address safety and efficacy in patients undergoing immunosuppressive drug therapy. Although clinical trials have addressed specific populations that are immunocompromised, including those with human immunodeficiency virus (HIV) coinfection and post-liver or -kidney transplantation, patients undergoing other forms of immunosuppressive drug therapy in the context of cancer chemotherapy and the treatment of autoimmune conditions have generally been excluded. As such, the available literature addressing these populations has been limited primarily to case reports or series and to historical IFN-based regimens. Due to the high prevalence of autoimmune conditions and cancer in the general population² and among those with chronic hepatitis C, more evidence-based guidance is needed to inform clinicians of the implications of immunosuppressive drug therapy on HCV treatment. Herein, we report the results of a systematic

Keywords: MeSH terms Hepatitis C/dt [drug therapy]; Interferons; Direct acting antivirals; Immunosuppressive agents; Chemotherapy.

Abbreviations: 5FU, 5-fluorouracil; AASLD, American Association for the Study of Liver Diseases; ABX, antibiotics; AE, adverse effect; AIH, autoimmune hepatitis; ALL, acute lymphoblastic leukemia; APASL, Asian Pacific Association for the Study of Liver; ASA, aminosalicic acid; AT, antiviral therapy; BFM, Berlin-Frankfurt-Münster; CD, Crohn's disease; CR, complete response; CRP, C-reactive protein; DAA, direct acting antiviral; EASL, European Association for the Study of Liver; EPO, erythropoietin; ESRD, end-stage renal disease; EVR, early viral response; G-CSF, granulocyte-colony stimulating factor; Hb, hemoglobin; HBV, hepatitis B virus; HCC, hepatocellular carcinoma; HCV, hepatitis C virus; HIV, human immunodeficiency virus; IBD, inflammatory bowel disease; IDSA, Infectious Diseases Society of America; IFN, interferon; IS, immunosuppression; MM, multiple myeloma; MPGN, membranoproliferative glomerulonephritis; MTX, methotrexate; NHL, non-Hodgkin's lymphoma; NK cell, natural killer cell; NR, no response; PASI, psoriasis area severity index; peg, polyethylene glycol; PLT, platelets; PR, partial response; QD, daily; RA, rheumatoid arthritis; RBV, ribavirin; RNA, ribonucleic acid; SSD, sickle cell disease; SVR, sustained virologic response; TNF- α , tumor necrosis factor- α ; TRAIL, TNF-related apoptosis-inducing ligand; UC, ulcerative colitis; VL, viral load; WBC, white blood cells; wnl, within normal limits; XELOX, Xeloda-oxaliplatin.

Received: 13 April 2016; Revised: 22 June 2016; Accepted: 12 July 2016

*DOI: 10.14218/JCTH.2016.00017.

*Correspondence to: Joseph K. Lim, Yale Liver Center, Section of Digestive Diseases, Yale University School of Medicine, 333 Cedar Street, LMP 1080, New Haven, CT 06520-8019, USA. Tel: +1-203-737-6063, Fax: +1-203-785-7273, E-mail: joseph.lim@yale.edu

review of available literature addressing HCV treatment in patients undergoing pharmacologic immunosuppression, focusing on immunosuppression for purposes other than organ rejection, and identify key gaps in the evidence that form the basis for future research priorities.

Chronic Hepatitis C in Immunosuppressed Patients

The immunopathogenesis of HCV infection is complex. Immunosuppression might be expected to reduce host-mediated inflammatory pathways that lead to liver damage; it may also reduce immune defenses against direct virally mediated liver injury.³ Steroids used in patients with hepatitis C/autoimmune hepatitis (AIH) overlap syndrome have led to clinical, biochemical and histologic improvements, despite an increase in viral load (VL).^{4–9} Inhibitors of tumor necrosis factor- α (TNF- α) appear to be safe for use in patients with HCV.^{10–12} Recent studies have argued that rates of hepatocellular carcinoma (HCC) in patients with HCV who were treated for psoriasis with anti-TNF- α agents are no higher than in those not on TNF- α inhibitors, which raises the possibility of a therapeutic role for TNF- α inhibitors for psoriasis in patients with chronic HCV infection.¹³ Among patients with inflammatory bowel disease (IBD) and HCV infection who are on immunosuppressive therapy, the rate of progression of fibrosis is similar to rates reported in patients not on immunosuppressive therapy.¹⁴

Scientific Rationale for Limiting Treatment

Treatment of HCV in immunosuppressed patients during the IFN era was complicated by varying effects on HCV and the disease being treated with immunosuppressive agents. Immunosuppression can cause worsening of liver dysfunction in patients infected with HCV.¹⁴ For patients on cytotoxic chemotherapy, this may lead to interruption or cessation of chemotherapy, as is reportedly the case for nearly 50% of patients.¹⁵ Secondly, IFN can induce flares of autoimmune disorders.^{16–18}

There are mechanistic reasons to believe that IFN-based treatment will be less effective in immunosuppressed patients. IFN-based therapy reduces VL through immune-mediated and non-immune-mediated mechanisms. It promotes T-cell survival and proliferation, both of which are strongly associated with successful IFN therapy.^{19,20} This is in line with primate studies that have shown that viral clearance of initial HCV infection is dependent on cytotoxic T-cells.^{21–23} IFN also up-regulates natural killer cell production of the apoptotic particle, TNF-related apoptosis-inducing ligand (TRAIL).^{24,25} Ribavirin (RBV) possesses T-cell-mediated antiviral effects.^{20,26} Immunosuppressive therapy, especially cytotoxic chemotherapy, would inhibit innate and adaptive immunity and could be expected to mitigate the immune-mediated effects of IFN and RBV.

However, the success of DAAs in achieving SVR without IFN demonstrates that inhibiting viral replication without inducing an additional immune response may be sufficient to clear HCV. This may be explained partly by the fact that there are no reservoirs of latent virus in infected individuals.²⁵ It is not clear, however, to what extent an intact immune system is necessary for viral eradication with DAAs.

Immunosuppression is a critical component of post-transplant maintenance therapy where concerns of rejection are in opposition to concerns of HCV reactivation.²⁷ Theoretically, immunosuppression reduces the former while increas-

ing the chance of the latter recurring, although the risk is lower than for hepatitis B virus (HBV) reactivation.^{28,29} In addition, withdrawal of immunosuppressive agents can cause a surge in immune response, leading to flares of hepatitis.^{28,30} Experience with transplant patients, however, shows that HCV can be treated safely and effectively in the setting of immunosuppression. With IFN-free regimens, rates of SVR in transplant patients without cirrhosis are similar to those in pre-transplant patients.^{31–34}

IFN-based treatment is only moderately effective and has frequent and significant side effects and many contraindications.^{35,36} Significant adverse effects of combination IFN and RBV include depression, cytopenias and flu-like symptoms. Importantly, it is contraindicated in the presence of conditions known to be exacerbated by IFN, such as autoimmune hemolytic anemia,³⁷ thyroid disease³⁸ and AIH.³⁹ Approximately one-quarter of patients who begin the IFN/RBV regimen do not complete the full treatment course.⁴⁰

DAAs are more efficacious, safer and more tolerable^{41–43} and do not cause potent immune stimulation. Patients who would not qualify for IFN-containing regimens—those with contraindications or severe comorbidities and those for whom the lower cure rate of IFN-containing regimens would be insufficient to justify the risk and cost—might benefit from DAAs. This raises the possibility that patients on immunosuppression may undergo treatment for HCV with IFN-free regimens and expect high rates of viral eradication and few serious adverse effects.

However, understanding of the effects of DAAs in patients on immunosuppression is limited by the fact that randomized controlled trials of DAAs have excluded such patients based on presence of malignancy, cytopenias (e.g. anemia, neutropenia, thrombocytopenia) and contraindications to IFN (e.g. chronic autoimmune diseases).^{44–47}

Transplant Experience

Liver Transplant

The literature supporting the treatment of hepatitis C in liver transplant recipients is more robust than that for patients on immunosuppressive drug therapy for other indications. In patients with HCV prior to liver transplant, recurrence is nearly universal. Historical IFN-based regimens used in patients with recurrent post-transplant HCV were poorly tolerated and associated with low rates of SVR. A systematic review of IFN-based treatment in liver transplant recipients on immunosuppressive regimens (mostly comprised of tacrolimus, cyclosporine and corticosteroids) revealed pooled SVR rates (24% and 27% with IFN/RBV and polyethylene glycol (peg)IFN/RBV, respectively).⁴⁸ Acute rejection occurred in 2% to 5% of patients, and a least two-thirds required dose reduction or early discontinuation. More recent reports cite SVR rates that are lower than 50%^{49–52} and acute rejection rates that are not significantly higher than those achieved with placebo.^{49,53}

Updated consensus guidelines of the American Association for the Study of Liver Diseases (AASLD) and Infectious Diseases Society of America (IDSA) now recommend all-oral treatment of hepatitis C in liver transplant recipients.⁵⁴ Randomized controlled trials have found SVR rates of over 90% in post-transplant patients with F0–F3 fibrosis and compensated cirrhosis, and of 80–85% in post-transplant patients with Child B or C decompensated cirrhosis undergoing

antiviral therapy with sofosbuvir/ledipasvir or sofosbuvir/daclatasvir.^{44,55,56} Serious adverse effects attributed to antiviral therapy were rare, and both regimens were well tolerated. Drug-drug interactions between DAAs and immunosuppressive drugs such as tacrolimus and cyclosporine are common, and require careful attention prior to and throughout the treatment course.

Kidney Transplant

No drugs are currently approved for the treatment of hepatitis C in kidney transplant recipients. IFN-containing regimens are generally avoided in renal transplant recipients because of an increased risk of graft rejection. A 2014 meta-analysis showed that IFN-containing regimens achieved SVR in 34%, but approximately one-third of patients failed to complete the treatment course, of whom approximately half discontinued due to graft dysfunction.⁵⁷ Accordingly, renal society guidelines from the IFN era suggest treating hepatitis C in renal transplant recipients only when the benefits outweigh the significant risk of rejection from IFN (e.g. fibrosing cholestatic hepatitis, cirrhosis or life-threatening vasculitis).⁵⁸ These guidelines suggested that although conventional immunosuppression can be used in this context, the evidence base to support specific therapies post-renal transplant is largely of very low quality, including case reports and case series.

Recent reports do suggest that all-oral DAA regimens appear to be well tolerated and efficacious in patients following renal transplantation.^{59–62} One randomized controlled trial by Colombo *et al*⁶³ reported at the International Liver Congress in April 2016 revealed that sofosbuvir/ledipasvir for 12 or 24 weeks was associated with an SVR of 98% (112/114) in GT1 or 4 treatment-naïve or experienced patients post-renal transplant, and was associated with favorable safety, with no events of acute rejection.

Other Transplant

We are aware of no studies examining the treatment of hepatitis C in recipients of other types of solid organ transplants. We were also unable to find studies in patients who had received stem cell transplants. One series of hepatitis C treatment in patients who had received bone marrow transplants excluded patients on immunosuppressive drug therapy.⁶⁴ A letter to the editor reports outcomes of five patients treated for hepatitis C after autologous stem cell transplantation but does not report immunosuppressive regimens that were used.⁶⁵

Methods

We conducted a systematic search of Medline (OVID), Cochrane Library, Embase and CINAHL in February 2016 for publications with the following terms: antineoplastic protocols, chemotherapy, antineoplastic agents, neoplasms/drug therapy, immunosuppressive agents, glucocorticoids, TNF- α , calcineurin inhibitors, and hepatitis c/drug therapy. We excluded citations with the keyword "organ transplantation" and limited our search to English language articles. Conference abstracts from the AASLD, the European Association for the Study of Liver (EASL), and the Asian Pacific Association for the Study of Liver (APASL) from 2015 and 2016 were reviewed in a targeted fashion, and one abstract from an international conference in February 2016 was included.⁶⁶

Long-term steroid regimens with more than 20 mg of prednisone equivalent per day were considered to be immunosuppressive. Patients who received rituximab administrations as early as 1 month before initiation of antiviral therapy were included. Otherwise, administration of any immunosuppressive agent while the patient was being treated for HCV was considered to be concomitant with antiviral therapy. Trials without clear description of the timing of drug therapy were excluded. Pharmacologic dosing trials were excluded as well.

Studies were characterized by their study design (e.g. randomized controlled trial), sample size, treatment regimens and outcomes. Outcomes for the disease for which immunosuppressive therapy was administered was judged to be positive if partial response or complete response was achieved or if otherwise described as being generally positive. If the treatment was repeated due to relapse, we chose to report the results of the first course only.

SVR was defined as undetectable HCV RNA at 12 weeks after the end of treatment for all-oral, IFN-free regimens, and 24 weeks after the end of treatment for historical IFN-based regimens. If RNA levels were not reported at 24 weeks but were reported at a later time point (e.g. at 36 weeks after the end of treatment) SVR at that point was used. Reports on cryoglobulinemic vasculitis are reported separately (i.e. not grouped by agent), as multiple classes of immunosuppressive therapies were often used and the primary intent of IFN-based treatment was as much treatment of vasculitis as treatment of HCV infection per se.

Results

Literature Search Results

A total of 2916 citations were retrieved through our search of the databases (Fig. 1). Of these, 143 were duplicates, leaving 2273 unique works. Abstracts from four international society meetings (AASLD, EASL, APASL, and Digestive Disease Week) were also reviewed to identify relevant studies, contributing one abstract from February 2016.⁶⁶ The studies were screened by KO and 96 studies were identified as possibly meeting criteria. After further review, 56 were included in this systematic review (Fig. 1). The studies selected for this review included 8 prospective interventional studies (n = 185 patients), including 3 randomized controlled trials (n = 76 patients), one non-randomized controlled trial (n = 76 patients), and four other prospective interventional trials (n = 33 patients). The studies also included 4 prospective cohort studies (n = 84 patients), 15 retrospective cohort studies, case-control studies, and case series (n = 80 patients), and 29 case reports (n = 33 patients). Approximately 40% of studies addressed cryoglobulinemia (Table 2). Ten studies comprising only 19 patients reported the results of cancer patients. Five studies with an average of 31 patients each reported the results of immunosuppressive agents used for the treatment of hepatitis C. IBD and other autoimmune disorders (e.g. rheumatoid arthritis) made up the remainder (19 studies and 93 patients).

Cryoglobulinemia and Vasculitis

In HCV-associated cryoglobulinemic vasculitis, B-cell expansion causes elevated levels of immunoglobulins that in turn can lead to skin ulcers, renal disease, neuropathy and other

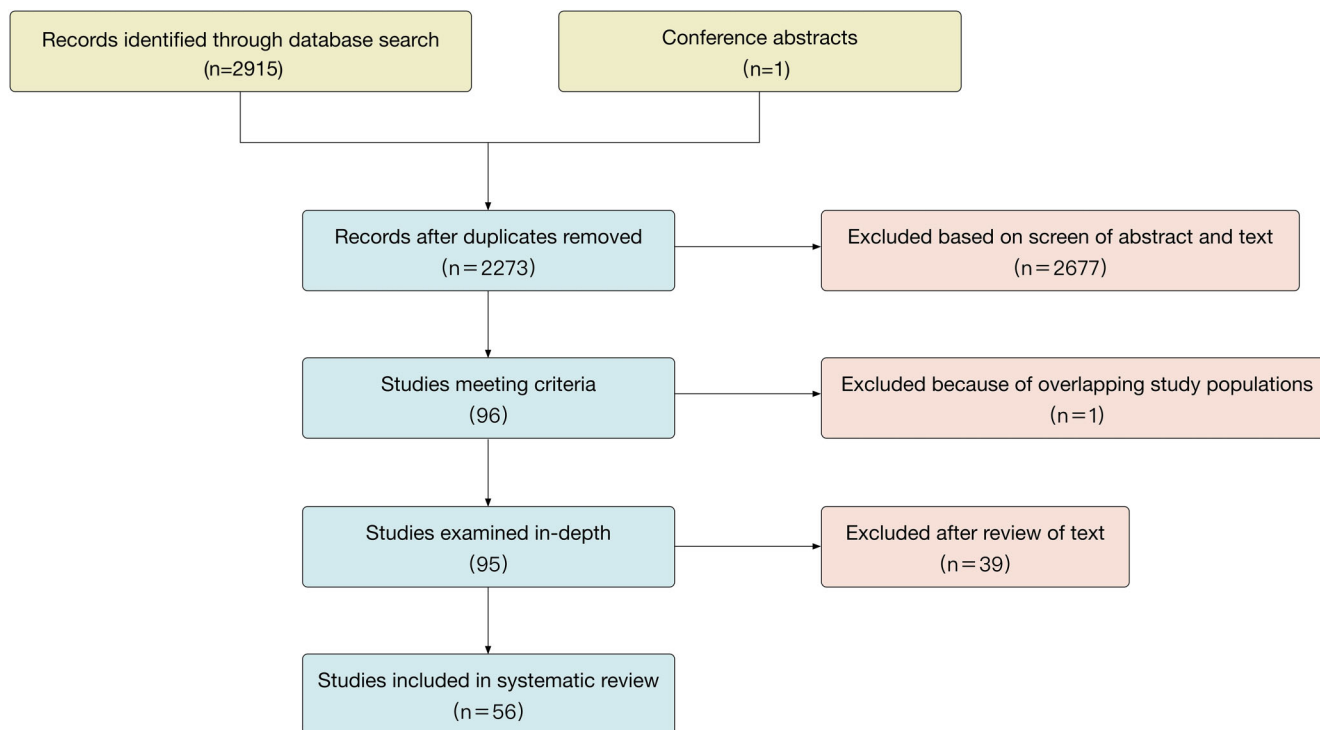


Fig. 1. PRISMA chart.

symptoms.⁶⁷ Both IFN-based antiviral therapy and immunosuppressive agents (e.g. rituximab) are components of regimens used to treat HCV-associated vasculitis.⁶⁸⁻⁷⁰ A number of studies have investigated the use of combination antiviral therapy and anti-CD20 antibodies to treat HCV-associated cryoglobulinemia, vasculitis or a combination of the two. As the primary intent is resolution of symptoms and organ dysfunction, rather than treatment of HCV, clinical response of renal function, skin ulcers and other manifestations of vasculitis are often described in detail but viral response rates, including SVR, are often not reported. Nonetheless, we can assess the efficacy and safety of anti-HCV agents used concomitantly with immunosuppressants in these settings.

In total, 22 studies reported outcomes of 116 patients (Table 3). In the nine studies that reported VL at 24 weeks after treatment or later, on aggregate, 56% of patients achieved

SVR; this finding was roughly similar to the usual efficacy of the various IFN-based regimens used in these studies. Nine patients required cessation or interruption of therapy secondary to adverse effects related to the medications. In the three studies with more than 10 patients, 46 of 80 patients (58%; range, 55-59%) reached SVR; all three used rituximab with pegIFN and RBV.⁷¹⁻⁷³ Similarly, clinical response of the cryoglobulinemia was seen in 84 of the 110 patients (76%). Adverse effects of IFN, RBV and rituximab did not appear to be more common than in patients not on immunosuppressive therapy. In a prospective cohort study of 38 patients on rituximab and various corticosteroids, other immunosuppressive agents or plasma exchange, three patients died (cirrhosis, liver carcinoma, unknown) but mortality was not significantly different from the control group (2/55 died from liver carcinoma).⁷¹

Few studies report the use of DAAs in cryoglobulinemia or vasculitis. Humphries *et al*⁷⁴ reported a case of cryoglobulinemic vasculitis manifesting as membranoproliferative glomerulonephritis (MPGN) and skin ulcers that was treated

Table 1. Study designs

Study Design	Studies	Patients
Case report	29	33
Case series	10	44
Case-control	2	11
Retrospective cohort	3	25
Prospective cohort	4	84
Prospective interventional	4	33
Non-randomized controlled trial	1	76
Randomized controlled trial	3	76
Total	56	382

Table 2. Reasons for immunosuppression

Reason for Immunosuppression	Studies	Patients
Cryoglobulinemia/vasculitis	22	116
Cancer	10	19
HCV – trial	5	154
IBD	8	60
Autoimmune – Other	11	33
Total	56	382

Table 3. Cryoglobulinemia and vasculitis

Study	Type	n	Age	Male, %	Immunosuppression	AT	Outcomes	Adverse Effects	SVR, %	Clinical Response, %
Sise, 2016 ⁷⁶	Case series	5	N/A	N/A	Rituximab × 4 pts Ustekinumab × 1 pt	Sofosbuvir + ribavirin or sofosbuvir + simeprevir × 12 wks	SVR12 in 3/4 pts on rituximab and 0/1 pts on ustekinumab (relapsed)	Not reported separately	60%	
Saadoun, 2014 ⁷⁵	Prospective cohort	4	N/A	N/A	Rituximab given 1 mo before AT	pegIFN α + RBV × 48 wks + telaprevir × 12 wks or boceprevir × 44 wks	PR in 2/4 and CR in 2/4	Not reported separately		100%
Humphries, 2014 ⁷⁴	Case report	1	59	100%	Methylprednisolone 500 mg × 2d and plasmapheresis × 5	Telaprevir, IFN, RBV × 24 wks	PR. Progressed to ESRD on HD 7 wks after end of tx. SVR achieved	Anemia requiring transfusions, EPO, and interruption of IFN and RBV	100%	0%
Wu, 2013 ⁸¹	Case report	1	57	0%	Methylprednisolone 40 mg/d started with AT	PegIFN α -2b + RBV	Thrombocytopenia resolved. Renal function improved. Cryoglobulins persistently high	None reported		100%
Zaidan, 2012 ¹²⁶	Case report	2	44	50%	Case 3: Cyclophosphamide and "IV steroid pulses." Later prednisone 50 mg/d Case 4: Prednisone PO 1 mg/kg/day × 5d, plasma exchange, rituximab IV	PegIFN- α 2a + RBV	Case 3: HCV: SVR at unknown time point. Purpura resolved. Renal function PR. Case 4: Skin lesions resolved. Renal function recovered	None reported		100%
Rodrigo, 2012 ¹²⁷	Case report	1	34	100%	Prednisolone 10 mg BID + cyclophosphamide	PegIFN-2 α + RBV	Skin lesions healed. Weakness improved. No relapse in 6 mo	None reported		100%
Kiremitci, 2012 ⁸²	Case report	1	34	0%	Methylprednisolone 0.5 mg/kg/d started with AT	PegIFN α 2	Nodules resolved. Renal function normalized but the relapsed	None reported		0%

(continued)

Table 3. Cryoglobulinemia and vasculitis (continued)

Study	Type	n	Age	Male, %	Immunosuppression	AT	Outcomes	Adverse Effects	SVR, %	Clinical Response, %
Colucci, 2011 ¹²⁸	Case report	1	53	0%	Rituximab before and cyclosporin A concurrent with AT	PegIFN α \times 12 mo	SVR not achieved	No fever, pain or allergic reactions	0%	0%
Butterly, 2010 ¹²⁹	Case series	1	44	100%	Rituximab	PegIFN	No improvement in vasculitis	0%	0%	0%
Saadoun, 2010 ⁷¹	Prospective cohort	38	58	32%	Rituximab +/- concurrent steroids, other immunosuppressive agents or plasma exchange	PegIFN- α 2a or 2b + RBV \times 48 wks	Similar SVR (22/38 vs 33/55 in control). Shorter time to clinical remission Higher rates of CR (28/38 vs 40/55) and PR (9/38 vs 13/55). 3 Deaths (cirrhosis, liver carcinoma, unknown) (no diff compared to cntl)	AE from AT in 21 and from rituximab in 10. Treatment interrupted in 5/38 (cytopenia \times 2, depression, psoriasis flare, neuropathy flare) (5/55 in control)	58%	79%
Dammacco, 2010 ⁷²	RCT	22	63	32%	Rituximab + methylprednisolone prior to and during AT	PegIFN- α 2a or 2b + RBV \times 48 wks	SVR (13/22 vs 4/15 in control). Higher CR (12/22 vs 5/15). Lower PR (5/22 vs 5/15). Relapses (2/22 vs 3/15)	Cytopenias, fevers, other mild AEs	68%	77%
Terrier, 2009 ⁷³	Retrospective cohort	20	61	30%	Rituximab. Some also received CS or plasmapheresis	PegIFN- α 2b + RBV starting 1 mo after last rituximab. \times 12 mo (median)	Higher SVR (11/20 vs 0/12 in control). Higher clinical response of vasculitis: CR 16, PR 3, NR1, relapse 3 (7/12, 1/12, 4/12, 4/12 in Cntl)	Generally well tolerated	55%	80%
Ahmed, 2008 ⁸³	Case report	1	35	100%	Methylprednisolone before AT. Prednisone PO 40 mg/d started with AT	PegIFN α (\geq 3 mo) Added RBV after 3 mo	Renal function improved. Albumin still elevated (38 g/L)	None major		100%
Koziolek, 2007 ¹³⁰	Case report	1	38	0%	Prednisolone 1 mg/kg started ~3 mo before AT. Cryoprecipitate after starting AT	PegIFN + RBV	Arthralgias and proteinuria improved	Symptomatic anemia. RBV stopped		100%

(continued)

Table 3. Cryoglobulinemia and vasculitis (continued)

Study	Type	n	Age	Male, %	Immunosuppression	AT	Outcomes	Adverse Effects	SVR, %	Clinical Response, %
Saadoun, 2006 ¹³¹	Prospective cohort	4	N/A	N/A	Rituximab	pegIFN α -2b/IFN- α 2b + RBV $\times \geq 6$ mo	Clinical response in 1/4	Unclear		25%
Saadoun, Aids 2006 ¹³²	Retrospective cohort	2	47	50%	Case 7: IVIG (2 g/kg/mo) + corticosteroids Case 8: Corticosteroids only	INF- α + RBV $\times \geq 6$ mo	Case 7: relapse to IFN-RBV, no SVR, no response to IS Case 8: CR to IFN-RBV, SVR, no response to IS	None following immunosuppression	50%	50%
Neri, 2005 ¹³³	Case report	1	63	0%	Cyclophosphamide + prednisone	pegIFN- α 2b	Symptomatic improvement. Died 4 mo later of nephritic syndrome and sepsis. SVR not achieved	None	0%	0%
Mendez, 2001 ¹³⁴	Case report	2	46	100%	Case 4: plasmapheresis + IVIG Case 6: plasmapheresis + corticosteroids	IFN	Case 4: "Improved clinically and ... doing well." Case 6: Necrotizing vasculitis responded. Hepatitis and viremia persisted. Died of MI 7y later	None reported		100%
Cacoub, 2001 ¹³⁵	Case control	5	N/A	N/A	Prednisone (1 mg/kg/d) reduced to 10 mg/d. Plasma exchange $\times 12$	IFN- $\alpha \times 18-36$ mo	Complete recovery in 5/5 (except ESRD in 1). No deaths	None reported		100%
Mercie, 2000 ⁸⁴	case report	1	40	0%	Corticosteroid bolus monthly and "oral corticosteroids" (1 mg/kg/d) slowly tapered	IFN $\times 18$ mo	HCV relapsed. Favorable course of vasculitis without reactivation	None reported	0%	100%
Kiyomoto, 1999 ¹³⁶	Case report	1	69	0%	Cryofiltration + prednisolone 30 mg/d	IFN- α	Renal function deteriorated. Nephrotic syndrome recurred	Flu-like symptoms, pancytopenia. Fever caused a 1 wk interruption		0%
David, 1996 ¹³⁷	Case report	1	39	100%	Prednisone 100 mg/d + azathioprine $\times \sim 10$ d. Plasmapheresis + cyclophosphamide later added	IFN- $\alpha \times 8$ mo	No new symptoms while on IFN. Strength started improving after 5-6 mo	Hemorrhagic cystitis. Cyclophosphamide DCed		100%

with telaprevir, pegIFN and RBV concurrent with methylprednisolone and plasmapheresis. SVR was achieved, but the MPGN progressed to end-stage renal disease by 7 weeks after treatment. The case was also complicated by anemia requiring interruption of treatment and transfusions of packed red blood cells. In a prospective cohort study of telaprevir or boceprevir and pegIFN and RBV in four patients who had been treated for mixed cryoglobulinemic vasculitis with rituximab 1 month prior, two patients achieved partial response and two achieved complete response;⁷⁵ SVR was not reported.

In the only study addressing the use of an all-oral regimen, three out of four patients on rituximab treated with sofosbuvir with RBV or simeprevir achieved SVR12.⁷⁶ One patient on ustekinumab (a monoclonal antibody that targets IL-12 and IL-23) experienced a relapse of HCV.

Overall, IFN-based antiviral therapy appears to perform reasonably well in patients on immunosuppressive therapy for cryoglobulinemia/vasculitis. The major caveats to these conclusions are that the quality of evidence is low, represented mostly by case reports and retrospective observational studies. DAAs were shown to be able to achieve SVR in this population, but with only three studies addressing this subject—of which two used regimens containing both DAAs and IFN—it is impossible to know if similar results can be expected in clinical practice.

Glucocorticoids

Glucocorticoids have potent anti-inflammatory and immunosuppressive effects at higher doses. They inhibit leukocyte infiltration into sites of tissue damage and repress transcription of inflammatory cytokines.⁷⁷ Withdrawal of steroids can cause these inflammatory processes to rebound. Some have investigated the use of this phenomenon for the treatment of HCV infection with mixed effects.^{78–80}

The effect of steroids can be clouded by other immunosuppressive agents that are frequently administered concomitantly. Five case reports discuss high-dose steroids used in the absence of other immunosuppressive therapies and concomitantly with antiviral therapy (Table 4).^{81–85} Four studies reported on patients with MPGN and/or vasculitis; three of four patients achieved a favorable clinical response and one of two achieved SVR.^{81–84} Overall, SVR was achieved in three of four patients for which it was reported. No major adverse effects were reported.

Efe *et al*⁸⁶ reports the results of a retrospective study of patients with HCV infection and AIH. Thirteen patients received immunosuppression with prednisone at a dose of 20–40 mg/day. An unknown number of these patients received azathioprine as well. After 3–6 months of immunosuppression, levels of alanine transaminase and aspartate transaminase fell below twice the upper limit of normal, and antiviral therapy with IFN with or without RBV was initiated. SVR was achieved in 7/13 and no relapse of AIH was observed. A report of two patients with AIH and HCV treated with pegIFN- α 2b and RBV while taking 20 mg/day of prednisolone reported achievement of SVR and good clinical response for both.⁸⁵ Overall, the use of glucocorticoids with IFN-based regimens achieved SVR in 10 of 17 patients (59%).

Based on these reports, treatment of chronic HCV infection with IFN-based regimens in patients on immunosuppressive doses of corticosteroids appears as safe and as effective as in patients not on immunosuppression. This conclusion should be considered in light of the caveat that the data is sparse and

of low quality. A single case series accounts for 13 of 19 total patients in these studies. Furthermore, these conclusions have become less relevant with the advent of DAAs. Unfortunately, there are no reports of all-oral DAA regimens used in patients on glucocorticoids in the absence of other immunosuppressive agents.

Cytotoxic Chemotherapy for Cancer

Treatment of chronic HCV infection in patients on chemotherapy for cancer presents a unique challenge and opportunity. Cirrhosis and chronic hepatitis are reportedly three-fold more common in those with cancer than in the general population.⁸⁷ Studies in patients with hematological malignancies suggest the prevalence of chronic HCV infection may range between 1.5% and 32%, depending on the type of malignancy and the population studied.⁸⁸ Chronic infection with HCV is associated with 1.6-fold [lung cancer, non-Hodgkin's lymphoma (NHL)] to 48.6-fold (liver cancer) increased risk of cancer.⁸⁹ AASLD guidelines do not address treatment of HCV in patients with cancer other than to recommend against monitoring for HCV recurrence in patients who achieved SVR.⁵⁴ Large trials of antiviral therapy for HCV have excluded patients on chemotherapy, making the literature on this topic sparse.

Seven studies with a total of 11 patients describe IFN-based regimens administered concomitantly with cytotoxic chemotherapy for patients with cancer (Table 5). All but one is a case report. Six patients had solid tumors (colon, breast, HCC) and five suffered from hematologic malignancies [acute lymphoblastic leukemia (ALL), NHL, multiple myeloma (MM)]. In the largest study, 5-fluorouracil (5FU) was infused into the hepatic artery in four patients with HCC.⁹⁰ Partial response of the HCC was seen in all patients. SVR was not reported. Overall, three of five (60%) patients in whom SVR was reported achieved this end-point. In two studies, HCV VL was undetectable at an unknown time point and SVR was not explicitly reported.^{90,91} One study reported achieving early virologic response but antiviral therapy was ongoing.⁹²

Taken in aggregate, the studies reported positive clinical responses in 10 of 11 patients. In six patients with hematological malignancies, four (ALL in three, B-cell NHL in one) experienced remission. In a case report of MM, disease progressed to involve new compression fractures at 4 months after thalidomide was initiated.

Adverse events were generally mild and limited to those known to be associated with the agents used. Cytopenias were common in patients with hematological malignancies. In three studies (three patients total), therapy was interrupted or modified as a result. In one study of docetaxel and trastuzumab for breast cancer, grade 4 neutropenia and grade 3 hepatotoxicity caused a delay in antiviral therapy and chemotherapy.⁹²

While these reports give us some sense of possible outcomes, it is undoubtedly too little to give clinicians much confidence when contemplating the treatment of HCV in their patients on cytotoxic chemotherapy. The paucity of data on this topic is especially unfortunate given that cancer is a relatively prevalent disease and that cytotoxic chemotherapy has long been a mainstay of therapy. Significantly, no studies report the use of modern all-oral DAA regimens in patients on cytotoxic chemotherapy for cancer.

Table 4. Steroids

Study	Type	n	Age	Male, %	Reason for IS	Immunosuppression	AT	Outcomes	Adverse Effects	SVR, %	Clinical Response, %
Wu, 2013 ⁸¹	Case report	1	57	0%	Cryoglobulinemia - MPGN	Methylprednisolone 40 mg/d	PegIFN- α 2b + RBV	Thrombocytopenia resolved. Renal function improved. Cryoglobulins persistently high	None reported		100%
Kiremitci, 2012 ⁸²	Case report	1	34	0%	Cryoglobulinemia - MPGN, skin eruptions, pneumonitis	Methylprednisolone 0.5 mg/kg/d	PegIFN- α 2	Nodules resolved. Renal function normalized but the relapsed	None reported		0%
Ahmed, 2008 ⁸³	Case report	1	35	100%	MPGN type 1. Cryoglobulin negative	Methylprednisolone before AT. Prednisone 40 mg/d started with AT	PegIFN- α . RBV added after 3 mo	Renal function improved. SVR. Albumin still elevated (38 g/L)	None major	100%	100%
Mercie, 2000 ⁸⁴	Case report	1	40	0%	Churg Strauss	Corticosteroid bolus monthly and "oral corticosteroids" (1 mg/kg/d) slowly tapered	IFN \times 18 mo	HCV relapsed. Favorable course of vasculitis without reactivation	None reported	0%	100%
Oeda, 2012 ⁸⁵	Case report	2	50	0%	AIH + HCV	Prednisolone 30-40 mg/d prior to AT reduced to 20 mg/d when AT started	PegIFN- α 2b + RBV \times 24-48 wks	SVR in 2/2. ALT and IgG normalized in 2/2.	None reported	100%	100%
Efe, 2013 ⁸⁶	Case series	13	N/A	NA	AIH + HCV	Prednisone 20-40 mg/d +/- azathioprine	INF +/- RBV	HCV: SVR in 7/13, NR in 6/13	No relapse of AIH	54%	100%

Table 5. Cancer Chemotherapy

Study	Type	n	Age	Male, %	Reason for IS	Immunosuppression	AT	Outcomes	Adverse Effects	SVR, %	Clinical Response, %
Matovina-Briko, 2014 ⁹²	Case report	1	60	0%	Breast cancer	Docetaxel + trastuzumab × 1y and radiotherapy	IFN-α2a + RBV × 6 mo	EVR. No active disease, complications, or HCV	Grade 4 neutropenia and grade 3 hepatotoxicity × 1 wk (AT and chemo delayed)	100%	100%
Gentile, 2013 ¹³⁸	Case report	1	60	100%	Colon cancer (adjuvant)	XELOX (capecitabine + oxaliplatin)	IFN-α2a	SVR	Diarrhea and neuropathy (both grade 1). Cytopenias with nadirs WBC 2.38, Hb 10.5, PLT 81,000. No transaminitis	100%	100%
Ayyub, 2011 ¹³⁹	Case report	1	22	100%	ALL	Vincristine + 6-MP (Patient had been on MTX and dexamethasone)	PegIFN-α2a + RBV × 72 wks	SVR	Neutropenia requiring IFN reduction and filgrastim	100%	100%
Papaevangelou, 2010 ¹⁴⁰	Case report	2	9	100%	Pt 1: ALL Pt 3: B-NHL	Pt 1: ALL BFM 95 Pt 3: NHL BFM 95	IFN-α + RBV. 18-24 mo	SVR 1/2. Both patients in remission.	Pt 1: Fever after IFN. Pt 3 transient subclinical hypothyroid	50%	100%
Kasai, 2009 ⁹⁰	Prospective interventional study	4	68	75%	HCC	5FU - intraarterial to hepatic artery (250 mg/d) days 1-5 of each week	PegIFN-α2b + RBV × 8-20 wks	HCV VL undetectable in 4/4 at unclear time point. PR of HCC in 4/4. No deaths	Thrombocytopenia × 1. Leukopenia /anorexia × 1	100%	100%
Lakatos, 2006 ⁹¹	Case report	1	50	0%	Multiple myeloma	Thalimide begun 2 mo before IS	PegIFN-α2b + RBV × 12 mo	EVR, ETR. New compression fractures	None reported	0%	0%
Waldron, 1999 ¹⁴¹	Case report	1	11	100%	ALL (b-cell precursor)	Etoposide, Ara-C, cyclophosphamide, vincristine, prednisone × 24 wks	IFN-α	No SVR. ALL in remission 72 mo after	Neutropenia and thrombocytopenia requiring dose adjustments	0%	100%

Table 6. Other treatments for cancer

Study	Type	n	Age	Male, %	Reason for IS	Immunosuppression	AT	Outcomes	Adverse Effects	SVR, %	Clinical Response, %
Torres, 2015 ⁸⁸	Case-control	6	N/A	N/A	Various cancers	Trastuzumab, tamoxifen, letrozole	IFN +/- RBV +/- nitazoxanide	SVR in 3/6 (2/3 trastuzumab, 1/2 tamoxifen, 0/1 letrozole). Not sig different from pts in study not on IS	Not reported separately	50%	
Kyvermitakis, 2014 ⁹³	Case series	1	34	0%	Mycosis fungoides	Photopheresis and denileukin diftiox (diphtheria toxin + IL2)	IFN-a x 18 mo	Skin lesions and pruritis improved. Circulating peripheral CD4 +/CD26- clonal T cells fell from 96.1% to 50.9%. SVR not achieved	Headaches and non-compliance led to multiple interruptions of IFN	0%	100%
Davar, 2015 ⁹⁴	Case report	1	59	0%	Advanced melanoma	Pembrolizumab x 15 cycles	Ledipasivir + Sofosbuvir started after cycle 9 of pembrolizumab	Melanoma: "excellent PR." Undetectable HCV VL and normal ALT and AST after 6 additional cycles of pembrolizumab	None reported		100%

Other Immunosuppressive Agents in Cancer

In a study examining IFN-based antiviral therapy in the setting of various hormonal agents (trastuzumab, tamoxifen, letrozole), SVR was achieved in 3 of 6 patients (Table 6).⁸⁸ Kyvernitakis *et al*⁹³ describe the use of IFN in a patient on treatment with photopheresis and denileukin diftitox for mycosis fungoides; skin lesions improved in this study, but SVR was not achieved. One case report describes all-oral antiviral regimens in patients undergoing immunotherapy for cancer.⁹⁴ Pembrolizumab combined with ledipasvir and sofosbuvir in a patient with advanced melanoma led to “excellent” response, normal transaminases and undetectable VL at an unknown time point. It should be noted that although antiviral therapy was started, at 9 cycles into a 15-cycle course of pembrolizumab it was not completely clear if pembrolizumab was continued while the patient was treated for HCV infection. However, given the novelty of the case—immunotherapy given concomitantly with DAAs—we felt somewhat compelled to include it.

Trials of Immunosuppressive Agents for the Treatment of HCV Infection

Three interventional studies comprising 97 patients examined the use of thalidomide and cyclosporin A for the treatment of HCV infection (Table 7). SVR was achieved in 42/76 (55%) patients in the largest study, a non-randomized controlled trial of cyclosporin A and IFN- α 2b compared to IFN- α 2b alone.⁹⁵ There was no significant difference in discontinuation of therapy or adverse events. Two single-armed prospective interventional trials of chemotherapeutic agents and IFN for the treatment of HCV infection were unable to achieve SVR. In a trial of cyclosporin and IFN- α con-1, hypertension and neutropenia required dose reductions of cyclosporin and IFN respectively.⁹⁶ In a trial of thalidomide and pegIFN- α 2b with RBV, thalidomide was discontinued in 2 of 11 patients due to vasovagal syncope and delirium.⁹⁷ Overall, it appears that the addition of cytotoxic chemotherapy reduces the efficacy of IFN-based antiviral therapy.

TNF- α Inhibitors

TNF- α is an inflammatory cytokine involved in the expression of other pro-inflammatory cytokines. Inhibitors of TNF- α are routinely used for the treatment of autoimmune disorders, such as IBD, rheumatoid arthritis and psoriasis. These agents, however, have been associated with an increased risk of serious infectious diseases, but data regarding worsening of HCV infection are conflicting.^{98–101} In a review of 216 patients (260 patient-years of follow-up) with HCV infection treated with TNF- α inhibitors, these agents were withdrawn due to suspected worsening HCV infection only three times.⁹⁸

Five reports on TNF- α inhibitors describe etanercept being used with IFN-based treatments in a total of 25 patients (Table 8).^{13,102–105} Flares of underlying autoimmune disorders were rare—one patient had a flare of rheumatoid arthritis and one patient experienced a recurrence of neuralgia. A trial of etanercept in combination with IFN and RBV for the treatment of HCV achieved SVR in 8 of 19 patients (42%), which was somewhat higher than in the control group (8/25, 32%) who were treated with IFN and RBV only.¹⁰⁵ Two of 19 patients withdrew because of adverse effects, although nausea was less common than in a control group. Otherwise, SVR was

Table 7. Trials of chemotherapeutic agents for HCV infection

Study	Type	n	Age	Male, %	Immunosuppression	AT	Outcomes	Adverse Effects	SVR, %
Pardo-Yules, 2012 ¹⁴²	Prospective interventional study	11	49	55%	Thalidomide	PegIFN- α 2b + RBV \times 24–48 wks	Relapse - 2/11; NR - 9/11; SVR - 0/11	Thalidomide stopped in 2/11 2/2 vasovagal syncope and delirium. Mild neuropathy after stopping AT for no response	0%
Cotler, 2003 ⁹⁶	Prospective interventional study	10	46 [†]	70%	Cyclosporin A	IFN- α con-1 \times 24–48 wks	SVR in 0/10	No new renal dysfunction. Triglyceridemia was common. HTN requiring CSA dose reduction in 2/10. Neutropenia requiring reduction of IFN in 5/10. FLS in 9/10	0%
Inoue, 2003 ⁹⁵	Non-randomized controlled trial	76	52	68%	Cyclosporin A	IFN- α 2b	SVR in 42/76 (14/44 in INF only group)	AEs were not significantly greater than in the control group. No new renal dysfunction	55%

[†] Median

Table 8. TNF- α inhibitors

Study	Type	n	Age	Male, %	Immunosuppression	AT	Outcomes	Adverse Effects	SVR, %
Basu, 2016 ⁶⁶	Controlled trial	35	50	74%	Various TNF- α inhibitors	LDV + SOF + RBV \times 8 wks or LDV + SOF \times 12 wks	SVR12 in 34/35 (100% study retention)	Anemia to Hb < 8.5 in 2/35. Severities of other AE are unclear.	97%
Bartalesi, 2013 ¹⁰³	Case report	1	53	100%	Etanercept 50 mg 2 \times /wk then 1 \times /wk	PegIFN- α 2a + RBV	SVR. Psoriasis much improved (PASI 18.9 \rightarrow 3.0)	Recurrence of glossopharyngeal neuralgia requiring surgical nerve excision. Anemia for which the pt received EPO. Neutropenia (850/mm ³)	100%
Navarro, 2013 ¹³	Cohort study	3	47	100%	Etanercept	IFN + RBV	Psoriasis improved in 2/3. HCV VL became undetectable in 2/2 with VL measurements. AST and ALT improved in 3/3	No significant AEs. No sx of hepatitis while on IS	
Behnam, 2010 ¹⁰²	Case report	1	56	100%	Etanercept 50 mg/wk	IFN- α + RBV \times 24 wks	Psoriasis was stable. Liver enzymes and HCV VL decreased markedly	None reported	
Jazwinski, 2011 ¹⁰⁴	Case report	1	53	100%	Etanercept 50 mg/wk. Prednisone \times 6 d for RA flare	PegIFN- α + RBV \times 24 wks	SVR. RA flared after starting AT	RA flare	100%
Zein, 2005 ¹⁰⁵	Randomized controlled trial (phase 2)	19	44	90%	Etanercept 25 mg 2 \times /wk	IFN- α 2b \times 24-48 wks	SVR in 8/19 (8/25 in control patients on IFN + RBV only). Greater decline in fibrosis compared to control	2/19 withdrew 2/2 anemia and IFN allergic reaction. (1 withdrew from control). Other AEs similar except nausea was less common with etanercept	42%

reported only in two case reports. In a report of rheumatoid arthritis treated with etanercept concomitantly with pegIFN- α and RBV, SVR was achieved but initiation of antiviral therapy was followed by a flare of rheumatoid arthritis that required steroids.¹⁰⁴ A patient with psoriasis treated with etanercept concomitantly with pegIFN- α 2a and RBV achieved SVR and improvement in the symptoms of psoriasis, but glossopharyngeal neuralgia recurred and required surgical nerve excision.¹⁰³ Taken together, the results of these studies show that IFN-based treatments can be given to patients on TNF- α inhibitors, but flares of underlying autoimmune diseases can occur. Moreover, one study has an outsized influence on the results due to the absence of other studies with large numbers of patients.

In an abstract addressing all-oral DAA regimens, Basu *et al*⁶⁶ report the results of a controlled trial in which a predominantly male (26/35, 74%) and ethnically diverse group of patients on various TNF-inhibitors for IBD who were treated with ledipasvir and sofosbuvir for 12 weeks (n = 18) or in combination with RBV for 8 weeks (n = 17). All patients completed antiviral therapy and SVR12 was achieved in 34 of 35 total patients. Adverse effects were common and similar between the two groups, except for anemia, which was more common in the RBV group (8/17 vs 2/18). Overall, gastrointestinal discomfort and diarrhea were experienced by 15 and 4 patients respectively. This is an important trial both for its study design and because of the use of modern treatment regimens. Its findings should give clinicians greater confidence in administering these antiviral treatments to patients on TNF- α inhibitors.

Antimetabolites

Azathioprine is a purine analog and prodrug of mercaptopurine. These compounds inhibit DNA synthesis, particularly in leukocytes, and thus inhibit inflammation.¹⁰⁶ Three studies examined the use of azathioprine in patients treated with IFN-based regimens (Table 9). Results were mixed. In a case series of patients with IBD, one of three patients achieved SVR and two patients required steroids for flares of Crohn's disease.¹⁰⁷ In a case report of a 54-year-old man treated with azathioprine, prednisone, pegIFN and RBV for AIH-HCV overlap syndrome, AIH went into remission but HCV VL never reached undetectable levels.¹⁰⁸ The patient developed respiratory failure secondary to Pseudomonal pneumonia and both immunosuppression and antiviral therapies were discontinued.

Adverse effects from concomitant use of RBV and azathioprine can be severe. In a retrospective study of eight patients on IFN, RBV and azathioprine who developed severe pancytopenia, erythropoietin (EPO), packed red blood cells and granulocyte-colony stimulating factor (G-CSF) were required in seven, two, and five patients respectively.¹⁰⁹ Time to recovery ranged from 4 to 7 weeks.

Methotrexate inhibits the metabolism of folate, which is required for nucleoside synthesis. In addition to this canonical function, methotrexate may also exert a direct immunosuppressive effect by inhibiting cell adhesion molecules.¹¹⁰ One case report describes a patient treated with pegIFN- α 2a and RBV while on methotrexate for rheumatoid arthritis.¹¹¹ SVR was achieved but cytopenias (nadir white blood cell (WBC) count of 1.8, platelet (PLT) count of 68,000) and a rheumatoid arthritis flare required the methotrexate dose to be decreased and then increased. After completion of the patient's antiviral

Table 9. Antimetabolites

Study	Type	n	Age	Male, %	Reason for IS	Immunosuppression	AT	Outcomes	Adverse Effects	SVR, %
Noguchi, 2011 ¹¹¹	Case report	1	39	0%	RA	Methotrexate + bucillamine	PegIFN- α 2a + RBV	SVR achieved	MTX decreased 2/2 leukopenia (1.8) and thrombocytopenia (68,000). MTX then increased 2/2 RA flare	100%
Wan, 2009 ¹⁰⁸	Case report	1	54	100%	AIH + HCV	Azathioprine + prednisone taper	IFN- α 2b switched to PEG-IFN on day 7	No SVR. HCV always detectable. AIH in clinical remission	Pseudomonal PNA @ wk 20. AT and IS discontinued	0%
Peyrin-Biroulet, 2008 ¹⁰⁹	Case series	8	47	63%	IBD	Azathioprine	PegIFN- α 2b + RBV	AT or azathioprine was restarted in 8/8	Pancytopenia (all pts; selected for this) EPO in 7/8, G-CSF in 5/8, pRBCs in 2/8	
Scherzer, 2008 ¹⁰⁷	Case series	3	47	67%	Crohn's	Azathioprine	PegIFN- α 2a + RBV \times 24 wks	SVR, NR, relapse	Increased CD activity in 2/3 (required steroids)	33%

Table 10. 5-ASA derivatives

Study	Type	n	Age	Male, %	Reason for IS	Immunosuppression	AT	Outcomes	Adverse Effects	SVR, %
Hahn, 2015 ¹¹⁵	Case series	1	50	100%	RA	Hydroxychloroquine, methylprednisolone 8 mg QD, sulfasalazine	Sofosbuvir/ledipasvir/GS-9451 × 6 wks	SVR24	RA flare after completion of AT	100%
Mitoto, 1993 ¹¹²	Case report	1	34	100%	UC	Sulfasalazine for treatment of UC flare that followed initiation of IFN-α	IFN-α × ~2.5 mo. Restarted 1 wk after sulfasalazine was started	ALT decreased but not normalized	Initial administration of IFN-α caused a flare of UC. There was no recurrence after IS was started	
Allen, 2013 ¹¹³	Case series	7	53	56%	IBD	Mesalamine (+ azathioprine in 2/7 pts)	IFN + RBV × 3-12 mo	SVR in 4/7 (2/2 on mesalamine and AZA; 2/5 on mesalamine alone)	IBD flare in 1/7 patients. No treatment stopped because of cytopenia	67%
Alok, 2010 ¹¹⁴	Case report	1	58	100%	Crohn's	Mesalamine	PegIFN-α2a + RBV	SVR. Bowel symptoms exacerbated	Budesonide given for IBD flare 13 wks into AT. Loperamide given for worsening IBD symptoms (CRP wnl) 8 mo into AT. Anemia requiring reduction of ribavirin	100%
Scherzer, 2008 ¹⁰⁷	Case series	4	54	50%	Crohn's	Mesalamine	PegIFN-α2a + RBV × 48 wks	SVR in 2/4. Relapse in 2/4	Increased CD activity in 3/4 (required steroids + ABX + mesalamine; and steroids; and mesalamine)	50%

Table 11. Other immunosuppressive agents

Study	Type	n	Age	Male, %	Reason for IS	Immunosuppression	AT	Outcomes	Adverse Effects	SVR, %
Agha, 2013 ¹¹⁶	Prospective interventional study	8	30 ¹	63%	SSD	Hydroxyurea	PegIFN α 2a + RBV	SVR: 6/8 SSD: overall decrease in median transfusion and pain crises	"Well-tolerated" and "without relevant side effects." All completed the study	75%
Azhar, 2010 ¹¹⁸	Case report	1	40	0%	AIH + HCV	MMF	Consensus IFN + RBV	SVR Achieved. No hepatitis flares	Cytopenias requiring filgrastim and EPO	100%
Scherzer, 2008 ¹⁰⁷	Case series	1	56	100%	Crohn's	MMF	PegIFN- α 2a + RBV \times 48 wks	SVR	Increased CD activity requiring dilation of stenosis	100%
Cornberg, 2002 ¹¹⁷	Prospective cohort	38	45	79%	HCV (trial)	MMF \times 24 wks	IFN- α 2a \times 24 wks	Study discontinued due to inefficacy. After 12 wks of therapy, only 1/29 had negative HCV	No serious AEs. No signs of diminished liver function. Not worse than IFN- α monotherapy	100%

¹ Median

Table 12. Direct-acting agents with interferon

Study	Type	n	Age	Male, %	Reason for IS	Immunosuppression	AT	Outcomes	Adverse Effects	SVR, %
Saadoun, 2014 ⁷⁵	Prospective cohort	4	N/A	N/A	Mixed cryoglobulinemia vasculitis	Rituximab given 1 mo before AT	PegIFN- α + RBV \times 48 wks + telaprevir \times 12 wks or boceprevir \times 44 wks	PR in 2/4 and CR in 2/4	Not reported separately	
Humphries, 2014 ⁷⁴	Case report	1	59	100%	Type II cryoglobulinemia (manifesting as MPGN and skin ulcers)	Methylprednisolone 500 mg \times 2d and plasmapheresis \times 5	IFN, RBV, telaprevir \times 24 wks	PR. Progressed to ESRD on HD 7 wks after end of tx. SVR achieved	Anemia requiring transfusions, EPO, and interruption of IFN and RBV	100%

Table 13. All-oral DAA regimens

Study	Type	n	Age	Male, %	Reason for IS	Immunosuppression	AT	Outcomes	Adverse Effects	SVR, %
Basu, 2016 ⁶⁶	Randomized controlled trial	35	50	74%	IBD	TNF- α antagonists maintained for the entire duration of AT	LDV + SOF + RBV 1000 mg \times 8 wks or LDV + SOF \times 12 wks	SVR12 in 34/35 (100% study retention)	Hb < 8.5 in 2. Severities of other AEs are unclear	97%
Sise, 2016 ⁷⁶	Case series	5	N/A	N/A	Mixed cryoglobulinemia	Rituximab \times 4 pts Ustekinumab \times 1 pt	Sofosbuvir + ribavirin or sofosbuvir + simeprevir \times 12 wks	SVR12 in 3/4 pts on rituximab and 0/1 pts on ustekinumab (relapsed)	Not reported separately	60%
Hahn, 2015 ¹¹⁵	Case series	1	50	100%	Rheumatoid arthritis	Hydroxychloroquine, methylprednisolone 8 mg QD, sulfasalazine	sofosbuvir/ledipasvir/GS-9451 \times 6 wks	SVR24	RA flare 1 wk after completion of AT	100%
Davar, 2015 ⁹⁴	Case report	1	59	0%	Advanced melanoma	Pembrolizumab \times 15 cycles	Ledipasvir + Sofosbuvir started after cycle 9 of pembrolizumab	Melanoma: "excellent PR." Undetectable HCV VL and normal ALT and AST after 6 additional cycles of pembrolizumab	None reported	

therapy, she was started on a prednisolone taper and adalimumab for worsening rheumatological symptoms.

Few conclusions can be drawn from this limited evidence base, but these cases demonstrate that SVR is feasible with IFN-based regimens, although their use may be limited by adverse effects. Data supporting the use of all-oral regimens in patients undergoing antimetabolite therapy are needed to support recommendations in this population.

5-Aminosalicylic Acid (ASA) Derivatives

Like azathioprine, the 5-ASA derivatives sulfasalazine and mesalamine are used to reduce inflammation in IBD and various autoimmune diseases, often in combination with other immunosuppressive agents. In the four studies that examined their use in patients with IBD who were undergoing IFN-based antiviral regimens, SVR was achieved in 7 of 12 patients (Table 10).^{107,112–114} Two of the 12 patients were also on azathioprine; both achieved SVR. One case report describes a new diagnosis of ulcerative colitis due to a flare that closely followed initiation of IFN-based antiviral therapy.¹¹² SVR was not reported. Increased IBD activity during concomitant antiviral and immunosuppressive therapy was observed in 5 of 13 total patients. Severity of the IBD flares was variable; one patient required steroids, mesalamine and antibiotics, while another patient required budesonide.

In the setting of IBD, IFN-based antiviral therapy appears equally effective at achieving SVR. The frequency of IBD flares does seem high given that 5-ASA derivatives are typically administered for more mild disease. It would be helpful to compare the frequency of exacerbations against the frequency in patients on other agents for IBD. Unfortunately, this is limited by the sparseness of data for patients on other therapies for IBD.

One case report describes a man treated for rheumatoid arthritis with hydroxychloroquine, low-dose corticosteroids and sulfasalazine. Twenty-four weeks after a 6-week course of sofosbuvir, ledipasvir and GS-9451 (an HCV NS1 protease inhibitor), HCV VL was undetectable.¹¹⁵ The patient did, however, experience a flare of the rheumatoid arthritis at 1 week after completing the antiviral therapy.

Overall, the literature suggests that SVR can be achieved with all-oral DAA regimens; however, more data are needed to clarify the impact of concomitant 5-ASA treatment on treatment outcomes, and conversely the potential role of HCV therapy on autoimmune disease activity.

Other Immunosuppressive Agents

A number of studies report antiviral therapy used in the setting of immunosuppressant regimens that do not fit adequately within the groups above (Table 11). One single-armed interventional study of pegIFN- α 2a and RBV in patients with sickle cell disease on hydroxyurea achieved SVR in 6 of 8 total patients, while transfusions and pain crises decreased.¹¹⁶ Adverse effects were not described in detail.

Three studies described mycophenolic acid administered concomitantly with IFN. The largest of these was a single-armed prospective interventional trial of a 24-week course of mycophenolic acid and IFN- α 2a for the treatment of chronic HCV infection in 38 previous non-responders.¹¹⁷ The study was discontinued after an interim analysis at 12 weeks found that only 1 of 29 patients assessed at that point had undetectable VL. No patients experienced serious adverse effects or

diminished hepatic function. In a case report of mycophenolic acid administered concomitantly with consensus IFN and RBV to a patient with AIH and HCV infection, SVR was achieved.¹¹⁸ No hepatitis flares were observed but the patient did require filgrastim and EPO. In another study, a patient on mycophenolic acid for Crohn's disease was treated with pegIFN- α 2a and RBV.¹⁰⁷ SVR was achieved but the patient experienced increased IBD activity and required dilation of a stenotic region of bowel. Taken together, these studies show that IFN-based antiviral therapy can cause a range of side effects in patients on mycophenolate mofetil. Furthermore, as in the studies of cytotoxic chemotherapy applied as an adjunct to IFN for the treatment of HCV, adding mycophenolate mofetil does not increase effectiveness.

DAAs

The majority of the studies in this review examine the use of historical IFN-containing regimens. However, DAAs have supplanted these regimens for the treatment of chronic HCV infection.

Two studies investigate the use of historical regimens of telaprevir or boceprevir in combination with IFN (Table 12). In four patients who had received rituximab 1 month prior for the treatment of mixed cryoglobulinemia, SVR was not reported and adverse effects were not reported separately for these patients from the larger study population in either study.⁷⁵ In a patient undergoing plasmapheresis and 2 days of high-dose methylprednisolone for MPGN and skin ulcers secondary to cryoglobulinemia, SVR was achieved but renal dysfunction progressed to end-stage renal disease and severe anemia required transfusions, erythropoietin and interruption of IFN and RBV.⁷⁴

Four studies examined the use of all-oral regimens in 42 patients who were on an array of immunosuppressive agents (Table 13).^{66,76,94,115} SVR was achieved in 38 of 41 patients (92.6%) reportedly. Adverse effects included one patient with a flare of rheumatoid arthritis and two patients with anemia (hemoglobin, 8.5). One study describes a patient treated with ledipasvir and sofosbuvir while receiving immunotherapy for advanced melanoma;⁹⁴ SVR was not reported. In general, it appears that all-oral regimens can be very effective even when patients are on immunosuppressive medications. More data in larger cohorts are needed to strengthen the evidence base for the use of all-oral DAAs in patients undergoing immunosuppressive drug therapy; although this will likely represent a preferred strategy for treatment over IFN-based regimens, which have been associated with autoimmune disease flares requiring increased immunosuppression^{104,107,111,114,115} and serious adverse events, including death.^{71,105,108}

Discussion

Hepatitis C is the most common chronic bloodborne infection in the United States.¹¹⁹ In those with acute HCV infection, approximately 80% will develop chronic hepatitis C.¹²⁰ Untreated chronic infection can lead to liver fibrosis, cirrhosis, HCC, liver failure and need for liver transplant. Extra-hepatic complications include type-1 MPGN, cryoglobulinemia and vasculitis. The development of all-oral DAA regimens, which are more effective and more tolerable than IFN-based regimens, provide clinicians with the opportunity to prevent these negative outcomes in patients who are unsuitable for IFN-based therapy. Concomitant administration of immunosuppressive therapy may at first seem antithetical to the rationale

behind IFN-based regimens; however, a growing body of evidence has been reported that supports their efficacy and safety. Trials of antiviral therapy in patients coinfecting with HIV and HCV or on immunosuppressive therapy for solid organ transplant have demonstrated that treating HCV in immunocompromised patients can be effective at achieving SVR, albeit at lower rates than in patients with intact immune systems.^{31–34,121,122}

While virologic relapse after SVR was seldom reported in the studies we examined, experience from coinfecting patients also shows that recurrence of HCV after achieving SVR is rare. A recent systematic review of non-transplant patients who were treated and achieved SVR in the IFN era revealed a 5-year risk of recurrence of 15%, as compared to the 0.95% reported among monoinfected patients without a recognized risk factor (injection drug use, men who have sex with men or imprisonment) and the 10.67% reported among monoinfected patients with a recognized risk factor.¹²³ However, two of the four studies of coinfecting patients drew their subjects exclusively from populations with recognized risk factors (men who have sex with men and incarcerated patients). Indeed, all cases of recurrence were confirmed to be reinfection rather than late relapse. A separate study of six patients with lupus treated with pegIFN and RBV reported late relapse in two patients.¹²⁴

The key limitation to the development of guideline statements addressing HCV treatment in patients undergoing immunosuppressive drug therapy is the poor quality of evidence, with a predominance of retrospective cohorts and case series; only eight prospective interventional trials evaluating 185 patients were identified in this systematic review. Available data strongly suggest that all-oral DAA regimens are well tolerated and associated with similar rates of SVR as those reported in patients without immunosuppression, and are unlikely to precipitate autoimmune disease activity.^{19,125}

Conclusion

Patients on immunosuppressive therapy represent a neglected population that may stand to benefit from advances in antiviral therapy for HCV infection. While IFN-based regimens can be safe and effective in some settings, side effects are significant and efficacy is far from perfect. Furthermore, evidence is lacking in key areas, such as patients with cancer. DAAs have potential to greatly increase the number of patients treated for HCV, but there is scant data on the use of these agents in immunosuppressed patients outside of the transplant setting. Adequately powered studies, ideally prospective observational cohort or multicenter randomized controlled trials, are needed to further strengthen the evidence base to inform guidelines on optimal all-oral treatment regimens for patients with HCV who are undergoing immunosuppressive drug therapy.

Conflict of interest

None

Author contributions

Drafting of the manuscript (KO), contributing to the conception and design (KO, JKL), contributing to critical revisions of the manuscript (JKL).

References

- [1] Mohd Hanafiah K, Groeger J, Flaxman AD, Wiersma ST. Global epidemiology of hepatitis C virus infection: new estimates of age-specific antibody to HCV seroprevalence. *Hepatology* 2013;57:1333–1342. doi: 10.1002/hep.26141.
- [2] The Autoimmune Diseases Coordinating Committee, National Institutes of Health. Progress in autoimmune diseases research. NIH Publication, 2005.
- [3] Einav S, Koziel MJ. Immunopathogenesis of hepatitis C virus in the immunosuppressed host. *Transpl Infect Dis* 2002;4:85–92. doi: 10.1034/j.1399-3062.2002.t01-2-02001.x.
- [4] Schiano TD, Te HS, Thomas RM, Hussain H, Bond K, Black M. Results of steroid-based therapy for the hepatitis C-autoimmune hepatitis overlap syndrome. *Am J Gastroenterol* 2001;96:2984–2991. doi: 10.1111/j.1572-0241.2001.04672.x.
- [5] Fong TL, Valinluck B, Govindarajan S, Charboneau F, Adkins RH, Redeker AG. Short-term prednisone therapy affects aminotransferase activity and hepatitis C virus RNA levels in chronic hepatitis C. *Gastroenterology* 1994;107:196–199. doi: 10.1016/0016-5085(94)90077-9.
- [6] Magrin S, Craxi A, Fabiano C, Simonetti RG, Fiorentino G, Marino L, *et al*. Hepatitis C viremia in chronic liver disease: relationship to interferon-alpha or corticosteroid treatment. *Hepatology* 1994;19:273–279. doi: 10.1002/hep.1840190203.
- [7] Magy N, Cribier B, Schmitt C, Ellero B, Jaecq D, Boudjema K, *et al*. Effects of corticosteroids on HCV infection. *Int J Immunopharmacol* 1999;21:253–261. doi: 10.1016/S0192-0561(99)00005-3.
- [8] Yoshikawa M, Toyohara M, Yamane Y, Mimura M, Miyamoto Y, Ueda S, *et al*. Disappearance of serum HCV-RNA after short-term prednisolone therapy in a patient with chronic hepatitis C associated with autoimmune hepatitis-like serological manifestations. *J Gastroenterol* 1999;34:269–274. doi: 10.1007/s005350050256.
- [9] Bellary S, Schiano T, Hartman G, Black M. Chronic hepatitis with combined features of autoimmune chronic hepatitis and chronic hepatitis C: favorable response to prednisone and azathioprine. *Ann Intern Med* 1995;123:32–34. doi: 10.7326/0003-4819-123-1-199507010-00004.
- [10] Ballanti E, Conigliaro P, Chimenti MS, Kroegler B, Di Muzio G, Guarino MD, *et al*. Use of anti-tumor necrosis factor alpha therapy in patients with concurrent rheumatoid arthritis and hepatitis B or hepatitis C: a retrospective analysis of 32 patients. *Drug Dev Res* 2014;75 Suppl 1:S42–S45. doi: 10.1002/ddr.21193.
- [11] Costa L, Caso F, Atteno M, Giannitti C, Spadaro A, Ramonda R, *et al*. Long-term safety of anti-TNF- α in PsA patients with concomitant HCV infection: a retrospective observational multicenter study on 15 patients. *Clin Rheumatol* 2014;33:273–276. doi: 10.1007/s10067-013-2378-0.
- [12] Brunasso AM, Puntoni M, Gulia A, Massone C. Safety of anti-tumor necrosis factor agents in patients with chronic hepatitis C infection: a systematic review. *Rheumatology (Oxford)* 2011;50:1700–1711. doi: 10.1093/rheumatology/ker190.
- [13] Navarro R, Vilarrasa E, Herranz P, Puig L, Bordas X, Carrascosa JM, *et al*. Safety and effectiveness of ustekinumab and antitumor necrosis factor therapy in patients with psoriasis and chronic viral hepatitis B or C: a retrospective, multicenter study in a clinical setting. *Br J Dermatol* 2013;168:609–616. doi: 10.1111/bjd.12045.
- [14] Loras C, Gisbert JP, Minguez M, Merino O, Bujanda L, Saro C, *et al*. Liver dysfunction related to hepatitis B and C in patients with inflammatory bowel disease treated with immunosuppressive therapy. *Gut* 2010;59:1340–1346. doi: 10.1136/gut.2010.208413.
- [15] Mahale P, Kontoyiannis DP, Chemaly RF, Jiang Y, Hwang JP, Davila M, *et al*. Acute exacerbation and reactivation of chronic hepatitis C virus infection in cancer patients. *J Hepatol* 2012;57:1177–1185. doi: 10.1016/j.jhep.2012.07.031.
- [16] Ketikoglou I, Karatapanis S, Elefsiniotis I, Kafiri G, Moulakakis A. Extensive psoriasis induced by pegylated interferon alpha-2b treatment for chronic hepatitis B. *Eur J Dermatol* 2005;15:107–109.
- [17] Kartal ED, Alpat SN, Ozgunes I, Usluer G. Reversible alopecia universalis secondary to PEG-interferon alpha-2b and ribavirin combination therapy in a patient with chronic hepatitis C virus infection. *Eur J Gastroenterol Hepatol* 2007;19:817–820. doi: 10.1097/MEG.0b013e32818b27e5.
- [18] Yurci A, Guven K, Torun E, Gursoy S, Baskol M, Akgun H, *et al*. Pyoderma gangrenosum and exacerbation of psoriasis resulting from pegylated interferon alpha and ribavirin treatment of chronic hepatitis C. *Eur J Gastroenterol Hepatol* 2007;19:811–815. doi: 10.1097/MEG.0b013e32816e070b.
- [19] Feld JJ, Hoofnagle JH. Mechanism of action of interferon and ribavirin in treatment of hepatitis C. *Nature* 2005;436:967–972. doi: 10.1038/nature04082.
- [20] Cramp ME, Rossol S, Chokshi S, Carucci P, Williams R, Naoumov NV. Hepatitis C virus-specific T-cell reactivity during interferon and ribavirin treatment in chronic hepatitis C. *Gastroenterology* 2000;118:346–355. doi: 10.1016/S0016-5085(00)70217-4.

- [21] Cooper S, Erickson AL, Adams EJ, Kansopon J, Weiner AJ, Chien DY, *et al*. Analysis of a successful immune response against hepatitis C virus. *Immunity* 1999;10:439–449. doi: 10.1016/S1074-7613(00)80044-8.
- [22] Shoukry NH, Grakoui A, Houghton M, Chien DY, Ghayeb J, Reimann KA, *et al*. Memory CD8+ T cells are required for protection from persistent hepatitis C virus infection. *J Exp Med* 2003;197:1645–1655. doi: 10.1084/jem.20030239.
- [23] Grakoui A, Shoukry NH, Woollard DJ, Han JH, Hanson HL, Ghayeb J, *et al*. HCV persistence and immune evasion in the absence of memory T cell help. *Science* 2003;302:659–662. doi: 10.1126/science.1088774.
- [24] Ahlenstiel G, Titerence RH, Koh C, Edlich B, Feld JJ, Rotman Y, *et al*. Natural killer cells are polarized toward cytotoxicity in chronic hepatitis C in an interferon- α -dependent manner. *Gastroenterology* 2010;138:325–335. doi: 10.1053/j.gastro.2010.05.010.
- [25] Heim MH. 25 years of interferon-based treatment of chronic hepatitis C: an epoch coming to an end. *Nat Rev Immunol* 2013;13:535–542. doi: 10.1038/nri3463.
- [26] Schoggins JW, Wilson SJ, Panis M, Murphy MY, Jones CT, Bieniasz P, *et al*. A diverse range of gene products are effectors of the type I interferon antiviral response. *Nature* 2011;472:481–485. doi: 10.1038/nature09907.
- [27] Everson GT. Impact of immunosuppressive therapy on recurrence of hepatitis C. *Liver Transpl* 2002;8:S19–S27. doi: 10.1053/jlts.2002.35852.
- [28] Vento S, Cainelli F, Mirandola F, Cosco L, Di Perri G, Solbiati M, *et al*. Fulminant hepatitis on withdrawal of chemotherapy in carriers of hepatitis C virus. *Lancet* 1996;347:92–93. doi: 10.1016/S0140-6736(96)90212-3.
- [29] Nakamura Y, Motokura T, Fujita A, Yamashita T, Ogata E. Severe hepatitis related to chemotherapy in hepatitis B virus carriers with hematologic malignancies. Survey in Japan, 1987–1991. *Cancer* 1996;78:2210–2215. doi: 10.1002/(SICI)1097-0142(19961115)78:10<2210::AID-CNCR24>3.0.CO;2-0.
- [30] Fan FS, Tzeng CH, Hsiao KI, Hu ST, Liu WT, Chen PM. Withdrawal of immunosuppressive therapy in allogeneic bone marrow transplantation reactivates chronic viral hepatitis C. *Bone Marrow Transplant* 1991;8:417–420.
- [31] Kwo PY, Mantry PS, Coakley E, Te HS, Vargas HE, Brown R Jr, *et al*. An interferon-free antiviral regimen for HCV after liver transplantation. *N Engl J Med* 2014;371:2375–2382. doi: 10.1056/NEJMoa1408921.
- [32] Ciesek S, Proske V, Otto B, Pischke S, Costa R, Lütthegemann M, *et al*. Efficacy and safety of sofosbuvir/ledipasvir for the treatment of patients with hepatitis C virus re-infection after liver transplantation. *Transpl Infect Dis* 2016;18:326–332. doi: 10.1111/tid.12524.
- [33] Manns M, Samuel D, Gane EJ, Mutimer D, McCaughan G, Buti M, *et al*. Ledipasvir and sofosbuvir plus ribavirin in patients with genotype 1 or 4 hepatitis C virus infection and advanced liver disease: a multicentre, open-label, randomised, phase 2 trial. *Lancet Infect Dis* 2016;16:685–697. doi: 10.1016/S1473-3099(16)00052-9.
- [34] Poordad F, Schiff ER, Vierling JM, Landis C, Fontana RJ, Yang R, *et al*. Daclatasvir with sofosbuvir and ribavirin for Hepatitis C virus infection with advanced cirrhosis or post-liver transplantation recurrence. *Hepatology* 2016;63:1493–1505. doi: 10.1002/hep.28446.
- [35] Strader DB, Wright T, Thomas DL, Seeff LB, American Association for the Study of Liver Diseases. Diagnosis, management, and treatment of hepatitis C. *Hepatology* 2004;39:1147–1171. doi: 10.1002/hep.20119.
- [36] Lauer GM, Walker BD. Hepatitis C virus infection. *N Engl J Med* 2001;345:41–52. doi: 10.1056/NEJM200107053450107.
- [37] Andriani A, Bibas M, Callea V, De Renzo A, Chiurazzi F, Marcenò R, *et al*. Autoimmune hemolytic anemia during alpha interferon treatment in nine patients with hematological diseases. *Haematologica* 1996;81:258–260.
- [38] Fernandez-Soto L, Gonzalez A, Escobar-Jimenez F, Vazquez R, Ocete E, Olea N, *et al*. Increased risk of autoimmune thyroid disease in hepatitis C vs hepatitis B before, during, and after discontinuing interferon therapy. *Arch Intern Med* 1998;158:1445–1448. doi: 10.1001/archinte.158.13.1445.
- [39] García-Buey L, García-Monzón C, Rodríguez S, Borque MJ, García-Sánchez A, Iglesias R, *et al*. Latent autoimmune hepatitis triggered during interferon therapy in patients with chronic hepatitis C. *Gastroenterology* 1995;108:1770–1777. doi: 10.1016/0016-5085(95)90139-6.
- [40] Cacoub P, Ouzan D, Melin P, Lang JP, Rotily M, Fontanges T, *et al*. Patient education improves adherence to peg-interferon and ribavirin in chronic genotype 2 or 3 hepatitis C virus infection: a prospective, real-life, observational study. *World J Gastroenterol* 2008;14:6195–6203. doi: 10.3748/wjg.14.6195.
- [41] Zhu GQ, Zou ZL, Zheng JN, Chen DZ, Zou TT, Shi KQ, *et al*. Systematic review and network meta-analysis of randomized controlled trials: comparative effectiveness and safety of direct-acting antiviral agents for treatment-naïve hepatitis C genotype 1. *Medicine (Baltimore)* 2016;95:e3004. doi: 10.1097/MD.00000000000003004.
- [42] Gutierrez JA, Lawitz EJ, Poordad F. Interferon-free, direct-acting antiviral therapy for chronic hepatitis C. *J Viral Hepat* 2015;22:861–870. doi: 10.1111/jvh.12422.
- [43] Banerjee D, Reddy KR. Review article: safety and tolerability of direct-acting anti-viral agents in the new era of hepatitis C therapy. *Aliment Pharmacol Ther* 2016;43:674–696. doi: 10.1111/apt.13514.
- [44] Charlton M, Everson GT, Flamm SL, Kumar P, Landis C, Brown RS Jr, *et al*. Ledipasvir and sofosbuvir plus ribavirin for treatment of HCV infection in patients with advanced liver disease. *Gastroenterology* 2015;149:649–659. doi: 10.1053/j.gastro.2015.05.010.
- [45] Wyles DL, Rodriguez-Torres M, Lawitz E, Shiffman ML, Pol S, Herring RW, *et al*. All-oral combination of ledipasvir, velparvir, tegobuvir, and ribavirin in treatment-naïve patients with genotype 1 HCV infection. *Hepatology* 2014;60:56–64. doi: 10.1002/hep.27053.
- [46] Zeuzem S, Berg T, Gane E, Ferenci P, Foster GR, Fried MW, *et al*. Simeprevir increases rate of sustained virologic response among treatment-experienced patients with HCV genotype-1 infection: a phase IIB trial. *Gastroenterology* 2014;146:430–441 e436.
- [47] Sulkowski MS, Eron JJ, Wyles D, Trinh R, Lalezari J, Wang C, *et al*. Ombitasvir, paritaprevir co-dosed with ritonavir, dasabuvir, and ribavirin for hepatitis C in patients co-infected with HIV-1: a randomized trial. *JAMA* 2015;313:1223–1231. doi: 10.1001/jama.2015.1328.
- [48] Wang CS, Ko HH, Yoshida EM, Marra CA, Richardson K. Interferon-based combination anti-viral therapy for hepatitis C virus after liver transplantation: a review and quantitative analysis. *Am J Transplant* 2006;6:1586–1599. doi: 10.1111/j.1600-6143.2006.01362.x.
- [49] Chalasani N, Manzarbeitia C, Ferenci P, Vogel W, Fontana RJ, Voigt M, *et al*. Peginterferon alfa-2a for hepatitis C after liver transplantation: two randomized, controlled trials. *Hepatology* 2005;41:289–298. doi: 10.1002/hep.20560.
- [50] Oton E, Barcena R, Moreno-Planas JM, Cuervas-Mons V, Moreno-Zamora A, Barrios C, *et al*. Hepatitis C recurrence after liver transplantation: Viral and histologic response to full-dose PEG-interferon and ribavirin. *Am J Transplant* 2006;6:2348–2355. doi: 10.1111/j.1600-6143.2006.01470.x.
- [51] Neumann U, Puhl G, Bahra M, Berg T, Langrehr JM, Neuhaus R, *et al*. Treatment of patients with recurrent hepatitis C after liver transplantation with peginterferon alfa-2B plus ribavirin. *Transplantation* 2006;82:43–47. doi: 10.1097/01.tp.0000225827.18034.be.
- [52] Angelico M, Petrolati A, Lionetti R, Lenci I, Burra P, Donato MF, *et al*. A randomized study on Peg-interferon alfa-2a with or without ribavirin in liver transplant recipients with recurrent hepatitis C. *J Hepatol* 2007;46:1009–1017. doi: 10.1016/j.jhep.2006.12.017.
- [53] Samuel D, Bizollon T, Feray C, Roche B, Ahmed SN, Lemonnier C, *et al*. Interferon-alpha 2b plus ribavirin in patients with chronic hepatitis C after liver transplantation: a randomized study. *Gastroenterology* 2003;124:642–650. doi: 10.1053/gast.2003.50095.
- [54] Available at: <http://www.hcvguidelines.org>.
- [55] Poordad F, Schiff ER, Vierling JM, Landis C, Fontana RJ, Yang R, *et al*. Daclatasvir with sofosbuvir and ribavirin for hepatitis C virus infection with advanced cirrhosis or post-liver transplantation recurrence. *Hepatology* 2016;63:1493–1505. doi: 10.1002/hep.28446.
- [56] Fontana RJ, Brown RS Jr, Moreno-Zamora A, Prieto M, Joshi S, Londoño MC, *et al*. Daclatasvir combined with sofosbuvir or simeprevir in liver transplant recipients with severe recurrent hepatitis C infection. *Liver Transpl* 2016;22:446–458. doi: 10.1002/lt.24416.
- [57] Fabrizi F, Penatti A, Messa P, Martin P. Treatment of hepatitis C after kidney transplant: a pooled analysis of observational studies. *J Med Virol* 2014;86:933–940. doi: 10.1002/jmv.23919.
- [58] Kidney Disease: Improving Global Outcomes (KDIGO) Transplant Work Group. KDIGO clinical practice guideline for the care of kidney transplant recipients. *Am J Transplant* 2009;9 Suppl 3:S1–S155. doi: 10.1111/j.1600-6143.2009.02834.x.
- [59] Huard G, Kim B, Patel A, Aljarallah B, Perumalswami P, Odin JA, *et al*. Early safety and efficacy profiles of Renal Transplant Recipients with chronic hepatitis C treated with Sofosbuvir and Ribavirin. The 65th Annual Meeting of the American Association for the Study of Liver Diseases: The Liver Meeting 2014. Boston, Massachusetts 2014.
- [60] Lin MV, Sise ME, Pavlakis M, Hanifi JM, Rutherford AE, Elias N, *et al*. LP42: Safety and efficacy of novel antivirals in kidney transplant recipients with chronic hepatitis C virus (HCV) infection. *J Hepatol* 2015;62:S284–S285. doi: 10.1016/S0168-8278(15)30196-3.
- [61] Bonacci M, Londoño MC, Esforzado N, Forns X, Sotoca JM, Campistol JM. Antiviral treatment with sofosbuvir and simeprevir in a kidney transplant recipient with HCV-decompensated cirrhosis: viral eradication and removal from the liver transplant waiting list. *Transpl Int* 2015;28:1345–1349. doi: 10.1111/tri.12622.
- [62] Kamar N, Marion O, Rostaing L, Cointault O, Ribes D, Lavayssière L, *et al*. Efficacy and safety of sofosbuvir-based antiviral therapy to treat hepatitis C virus infection after kidney transplantation. *Am J Transplant* 2016;16:1474–1479. doi: 10.1111/ajt.13518.
- [63] Colombo M, Aghemo A, Liu H, Dvory-Sobol H, Hyland RH, Yun C, *et al*. Ledipasvir/Sofosbuvir (LDV/SOF) for 12 or 24 Weeks Is Safe and Effective

- in Kidney Transplant Recipients with Chronic Genotype 1 or 4 HCV Infection. International Liver Congress. Barcelona, Spain 2016.
- [64] Giardini C, Galimberti M, Lucarelli G, Polchi P, Angelucci E, Baronciani D, *et al*. Alpha-interferon treatment of chronic hepatitis C after bone marrow transplantation for homozygous beta-thalassemia. *Bone Marrow Transplant* 1997;20:767–772. doi: 10.1038/sj.bmt.1700968.
- [65] Varma A, Saliba RM, Torres HA, Afrough A, Hosing C, Khouri IF, *et al*. Outcomes in hepatitis C virus seropositive lymphoma and myeloma patients after autologous stem cell transplantation. *Bone Marrow Transplant* 2016; 51:999–1001. doi: 10.1038/bmt.2016.28.
- [66] Basu P. Sofosbuvir, Ledipasvir in IBD treated patients with advanced biologics including Ribavirin eradicating Chronic Hepatitis C. SOLATAIRE C Trial. A multi-center clinical prospective pilot study. APASL 2016:2016.
- [67] Dustin LB, Rice CM. Flying under the radar: the immunobiology of hepatitis C. *Annu Rev Immunol* 2007;25:71–99. doi: 10.1146/annurev.immunol.25.022106.141602.
- [68] Dammacco F, Sansonno D. Therapy for hepatitis C virus-related cryoglobulinemic vasculitis. *N Engl J Med* 2013;369:1035–1045. doi: 10.1056/NEJMra1208642.
- [69] Pietrogrande M, De Vita S, Zignego AL, Pioletti P, Sansonno D, Sollima S, *et al*. Recommendations for the management of mixed cryoglobulinemia syndrome in hepatitis C virus-infected patients. *Autoimmun Rev* 2011;10:444–454. doi: 10.1016/j.autrev.2011.01.008.
- [70] Saadoun D, Delluc A, Piette JC, Cacoub P. Treatment of hepatitis C-associated mixed cryoglobulinemia vasculitis. *Curr Opin Rheumatol* 2008;20:23–28. doi: 10.1097/bor.0b013e3282f1330c.
- [71] Saadoun D, Resche Rigon M, Sene D, Terrier B, Karras A, Perard L, *et al*. Rituximab plus Peg-interferon-alpha/ribavirin compared with Peg-interferon-alpha/ribavirin in hepatitis C-related mixed cryoglobulinemia. *Blood* 2010;116:326–334; quiz 504–505. doi: 10.1182/blood-2009-10-248518.
- [72] Dammacco F, Tucci FA, Lauletta G, Gatti P, De Re V, Conteduca V, *et al*. Pegylated interferon-alpha, ribavirin, and rituximab combined therapy of hepatitis C virus-related mixed cryoglobulinemia: a long-term study. *Blood* 2010;116:343–353. doi: 10.1182/blood-2009-10-245878.
- [73] Terrier B, Saadoun D, Sène D, Sellam J, Pérard L, Coppéré B, *et al*. Efficacy and tolerability of rituximab with or without PEGylated interferon alfa-2b plus ribavirin in severe hepatitis C virus-related vasculitis: a long-term followup study of thirty-two patients. *Arthritis Rheum* 2009;60:2531–2540. doi: 10.1002/art.24703.
- [74] Humphries K, Darling JM, Barritt AS. 4th. Membranoproliferative glomerulonephritis, type II cryoglobulinemia and triple therapy for hepatitis C: a case series and review of the literature. *Dig Dis Sci* 2014;59:2007–2012. doi: 10.1007/s10620-014-3085-7.
- [75] Saadoun D, Resche Rigon M, Thibault V, Longuet M, Pol S, Blanc F, *et al*. Peg-IFN α /ribavirin/protease inhibitor combination in hepatitis C virus associated mixed cryoglobulinemia vasculitis: results at week 24. *Ann Rheum Dis* 2014;73:831–837. doi: 10.1136/annrheumdis-2012-202770.
- [76] Sise ME, Bloom AK, Wisocky J, Lin MV, Gustafson JL, Lundquist AL, *et al*. Treatment of hepatitis C virus-associated mixed cryoglobulinemia with direct-acting antiviral agents. *Hepatology* 2016;63:408–417. doi: 10.1002/hep.28297.
- [77] Coutinho AE, Chapman KE. The anti-inflammatory and immunosuppressive effects of glucocorticoids, recent developments and mechanistic insights. *Mol Cell Endocrinol* 2011;335:2–13. doi: 10.1016/j.mce.2010.04.005.
- [78] McHutchison JG, Ponnudurai R, Bylund DL, Anguiano A, Pockros PJ, Mondala T, *et al*. Prednisone withdrawal followed by interferon alpha for treatment of chronic hepatitis C infection: results of a randomized controlled trial. *J Clin Gastroenterol* 2001;32:133–137. doi: 10.1097/00004836-200102000-00008.
- [79] Liaw YF, Sheen IS, Lin SM, Chen TJ, Chu CM. Effects of prednisolone pretreatment in interferon alpha therapy for patients with chronic non-A, non-B (C) hepatitis. *Liver* 1993;13:46–50. doi: 10.1111/j.1600-0676.1993.tb00604.x.
- [80] Guilera M, Fornis X, Torras X, Enriquez J, Coll S, Solà R, *et al*. Pre-treatment with prednisolone does not improve the efficacy of subsequent alpha interferon therapy in chronic hepatitis C. *J Hepatol* 2000;33:135–141. doi: 10.1016/S0168-8278(00)80170-1.
- [81] Wu H, Zou HB, Xu Y, Zhang L, Du YJ, Yu JY, *et al*. Hepatitis C virus-related heat-insoluble cryoglobulinemia and thrombotic microangiopathy. *Am J Med Sci* 2013;346:345–348. doi: 10.1097/MAJ.0b013e328318293cdee.
- [82] Kiremitci S, Calayoglu R, Ensari A, Erbay B. Pathologist's puzzle: Membranoproliferative glomerulonephritis-like features in cryoglobulinemic glomerulonephritis. *Pathol Res Pract* 2012;208:254–258. doi: 10.1016/j.prp.2012.01.006.
- [83] Ahmed MS, Wong CF, Shawki H, Kapoor N, Pandya BK. Rapidly deteriorating renal function with membranoproliferative glomerulonephritis Type 1 associated with hepatitis C treated successfully with steroids and antiviral therapy: a case report and review of literature. *Clin Nephrol* 2008;69:298–301. doi: 10.5414/CNP69298.
- [84] Mercier P, Viillard JF, Faure I, Trimoulet P, Vital A, Lifermann F, *et al*. Hepatitis C virus infection with and without cryoglobulinemia as a case of Churg-Strauss syndrome. *J Rheumatol* 2000;27:814–817.
- [85] Oeda S, Mizuta T, Isoda H, Kuwashiro T, Oza N, Iwane S, *et al*. Efficacy of pegylated interferon plus ribavirin in combination with corticosteroid for two cases of combined hepatitis C and autoimmune hepatitis. *Clin J Gastroenterol* 2012;5:141–145. doi: 10.1007/s12328-012-0295-4.
- [86] Efe C, Heurgué-Berlot A, Ozasian E, Purnak T, Thiéfn G, Simsek H, *et al*. Late autoimmune hepatitis after hepatitis C therapy. *Eur J Gastroenterol Hepatol* 2013;25:1308–1311. doi: 10.1097/MEG.0b013e328361c704.
- [87] Edwards BK, Noone AM, Mariotto AB, Simard EP, Boscoe FP, Henley SJ, *et al*. Annual Report to the Nation on the status of cancer, 1975–2010, featuring prevalence of comorbidity and impact on survival among persons with lung, colorectal, breast, or prostate cancer. *Cancer* 2014;120:1290–1314. doi: 10.1002/cncr.28509.
- [88] Torres HA, Mahale P, Blechacz B, Miller E, Kaseb A, Herlong HF, *et al*. Effect of hepatitis C virus infection in patients with cancer: addressing a neglected population. *J Natl Compr Canc Netw* 2015;13:41–50.
- [89] Allison RD, Tong X, Moorman AC, Ly KN, Rupp L, Xu F, *et al*. Increased incidence of cancer and cancer-related mortality among persons with chronic hepatitis C infection, 2006–2010. *J Hepatol* 2015;63:822–828. doi: 10.1016/j.jhep.2015.04.021.
- [90] Kasai K, Kuroda H, Ushio A, Sawara K, Takikawa Y, Suzuki K. Evaluation of newly developed combination therapy of intra-arterial 5-fluorouracil and systemic pegylated interferon alpha-2b for advanced hepatocellular carcinoma with portal venous invasion: preliminary results. *Hepatol Res* 2009; 39:117–125. doi: 10.1111/j.1872-034X.2008.00414.x.
- [91] Lakatos PL, Fekete S, Horanyi M, Fischer S, Abonyi ME. Development of multiple myeloma in a patient with chronic hepatitis C: A case report and review of the literature. *World J Gastroenterol* 2006;12:2297–2300. doi: 10.3748/wjg.v12.i14.2297.
- [92] Matovina-Brko G, Ruzic M, Fabri M, Popovic L, Kolarov-Bjelobrk I, Trifunovic J, *et al*. Treatment of acute hepatitis C in breast cancer patient: a case report. *J Chemother* 2014;26:180–183. doi: 10.1179/1973947813Y.0000000129.
- [93] Kyvernitakis A, Duvic M, Mahale P, Torres HA. Interferon-based treatment for patients with mycosis fungoides and hepatitis C virus infection: a case series. *Am J Clin Dermatol* 2014;15:451–456. doi: 10.1007/s40257-014-0084-6.
- [94] Davar D, Wilson M, Pruckner C, Kirkwood JM. PD-1 blockade in advanced melanoma in patients with hepatitis C and/or HIV. *Case Rep Oncol Med* 2015;2015:737389. doi: 10.1155/2015/737389.
- [95] Inoue K, Sekiyama K, Yamada M, Watanabe T, Yasuda H, Yoshida M. Combined interferon α 2b and cyclosporin A in the treatment of chronic hepatitis C: controlled trial. *Reumatismo* 2005;57:128–129.
- [96] Cotler SJ, Morrissey MJ, Wiley TE, Layden TJ, Jensen DM. A pilot study of the combination of cyclosporin A and interferon alfacon-1 for the treatment of hepatitis C in previous nonresponder patients. *J Clin Gastroenterol* 2003; 36:352–355. doi: 10.1097/00004836-200304000-00014.
- [97] Pardo M, Castillo I, Navas S, Carreño V. Treatment of chronic hepatitis C with cirrhosis with recombinant human granulocyte colony-stimulating factor plus recombinant interferon-alpha. *J Med Virol* 1995;45:439–444. doi: 10.1002/jmv.1890450415.
- [98] Pompili M, Biolato M, Miele L, Grieco A. Tumor necrosis factor- α inhibitors and chronic hepatitis C: a comprehensive literature review. *World J Gastroenterol* 2013;19:7867–7873. doi: 10.3748/wjg.v19.i44.7867.
- [99] Bongartz T, Sutton AJ, Sweeting MJ, Buchan I, Matteson EL, Montori V. Anti-TNF antibody therapy in rheumatoid arthritis and the risk of serious infections and malignancies: systematic review and meta-analysis of rare harmful effects in randomized controlled trials. *JAMA* 2006;295:2275–2285. doi: 10.1001/jama.295.19.2275.
- [100] Costenbader KH, Glass R, Cui J, Shadick N. Risk of serious infections and malignancies with anti-TNF antibody therapy in rheumatoid arthritis. *JAMA* 2006;296:2201; author reply 2203–2204. doi: 10.1001/jama.296.18.2202.
- [101] Breedveld FC, Weisman MH, Kavanaugh AF, Cohen SB, Pavelka K, van Vollenhoven R, *et al*. The PREMIER study: A multicenter, randomized, double-blind clinical trial of combination therapy with adalimumab plus methotrexate versus methotrexate alone or adalimumab alone in patients with early, aggressive rheumatoid arthritis who had not had previous methotrexate treatment. *Arthritis Rheum* 2006;54:26–37. doi: 10.1002/art.21519.
- [102] Behnam SE, Hindiyyeh R, Fife DJ, Jeffes EW 3rd, Wu JJ. Etanercept as prophylactic psoriatic therapy before interferon-alpha and ribavirin treatment for active hepatitis C infection. *Clin Exp Dermatol* 2010;35:397–398. doi: 10.1111/j.1365-2230.2009.03476.x.
- [103] Bartalesi F, Salomoni E, Cavallo A, Corti G, Pimpinelli N, Bartoloni A, *et al*. Chronic hepatitis C virus hepatitis and psoriasis: no longer a contraindication to interferon use in the era of biological agents? *Scand J Infect Dis* 2013;45:320–323. doi: 10.3109/00365548.2012.720026.

- [104] Jazwinski AB, Jezsik J, Ardoin SP, McCallum RM, Tillmann HL. Etanercept treatment to enable successful hepatitis C virus clearance in a patient with rheumatoid arthritis. *Gastroenterol Hepatol (N Y)* 2011;7:772-774.
- [105] Zein NN, Etanercept Study Group. Etanercept as an adjuvant to interferon and ribavirin in treatment-naïve patients with chronic hepatitis C virus infection: a phase 2 randomized, double-blind, placebo-controlled study. *J Hepatol* 2005;42:315-322. doi: 10.1016/j.jhep.2004.11.025.
- [106] Maltzman JS, Koretzky GA. Azathioprine: old drug, new actions. *J Clin Invest* 2003;111:1122-1124. doi: 10.1172/JCI200318384.
- [107] Scherzer TM, Stauer K, Novacek G, Steindl-Munda P, Schumacher S, Hofer H, *et al*. Efficacy and safety of antiviral therapy in patients with Crohn's disease and chronic hepatitis C. *Aliment Pharmacol Ther* 2008;28:742-748. doi: 10.1111/j.1365-2036.2008.03779.x.
- [108] Wan DW, Marks K, Yantiss RK, Talal AH. Autoimmune hepatitis in the HIV-infected patient: a therapeutic dilemma. *AIDS Patient Care STDS* 2009;23:407-413. doi: 10.1089/apc.2008.0149.
- [109] Peyrin-Biroulet L, Cadranet JF, Noursbaum JB, Oussalah A, Seddik M, Canva V, *et al*. Interaction of ribavirin with azathioprine metabolism potentially induces myelosuppression. *Aliment Pharmacol Ther* 2008;28:984-993. doi: 10.1111/j.1365-2036.2008.03812.x.
- [110] Wessels JA, Huizinga TW, Guchelaar HJ. Recent insights in the pharmacological actions of methotrexate in the treatment of rheumatoid arthritis. *Rheumatology (Oxford)* 2008;47:249-255. doi: 10.1093/rheumatology/kem279.
- [111] Noguchi O, Gibo Y. Induction of clinical remission with adalimumab-methotrexate combination therapy in a patient with rheumatoid arthritis and concomitant hepatitis C virus infection. *Mod Rheumatol* 2011;21:696-700. doi: 10.3109/s10165-011-0469-9.
- [112] Mitoro A, Yoshikawa M, Yamamoto K, Mimura M, Yoshikawa Y, Shiroy A, *et al*. Exacerbation of ulcerative colitis during alpha-interferon therapy for chronic hepatitis C. *Intern Med* 1993;32:327-331. doi: 10.2169/internalmedicine.32.327.
- [113] Allen AM, Kim WR, Larson J, Loftus EV Jr. Efficacy and safety of treatment of hepatitis C in patients with inflammatory bowel disease. *Clin Gastroenterol Hepatol* 2013;11:1655-1660. e1651.
- [114] Gupta A, Sitrin MD. Concomitant therapy of Crohn's disease and hepatitis C with budesonide and antivirals. *Gastroenterol Hepatol (N Y)* 2010;6:525-527.
- [115] Hahn KJ, Kohli A, Sims Z, Kottlilil S. Durable sustained virologic response after oral directly acting antiviral therapy despite immunosuppressive treatment. *Open Forum Infect Dis* 2015;2:ofv091.
- [116] Agha A, Chakik R, Abdulhadi Ali MM, Alsaadi D, Sammito G, Giannini EG. Peg-interferon alpha-2a and low-dose ribavirin for treatment of hepatitis C virus infection in patients with sickle-cell anemia in Saudi Arabia. *Ann Saudi Med* 2013;33:610-613.
- [117] Cornberg M, Hinrichsen H, Teuber G, Berg T, Naumann U, Falkenberg C, *et al*. Mycophenolate mofetil in combination with recombinant interferon alfa-2a in interferon-nonresponder patients with chronic hepatitis C. *J Hepatol* 2002;37:843-847. doi: 10.1016/S0168-8278(02)00300-8.
- [118] Azhar A, Niazi MA, Tufail K, Malek AH, Balasubramanian M, Araya V. A new approach for treatment of hepatitis C in hepatitis C-autoimmune hepatitis overlap syndrome. *Gastroenterol Hepatol (N Y)* 2010;6:233-236.
- [119] CDC. *Blood Safety*. 2013.
- [120] Wilkins T, Akhtar M, Gititu E, Jalluri C, Ramirez J. Diagnosis and management of hepatitis C. *Am Fam Physician* 2015;91:835-842.
- [121] Chung RT, Andersen J, Volberding P, Robbins GK, Liu T, Sherman KE, *et al*. Peginterferon Alfa-2a plus ribavirin versus interferon alfa-2a plus ribavirin for chronic hepatitis C in HIV-coinfected persons. *N Engl J Med* 2004;351:451-459. doi: 10.1056/NEJMoa032653.
- [122] Mehta SH, Lucas GM, Mirel LB, Torbenson M, Higgins Y, Moore RD, *et al*. Limited effectiveness of antiviral treatment for hepatitis C in an urban HIV clinic. *AIDS* 2006;20:2361-2369. doi: 10.1097/QAD.0b013e32801086da.
- [123] Simmons B, Saleem J, Hill A, Riley RD, Cooke GS. Risk of late relapse or reinfection with hepatitis C virus after achieving a sustained virological response: a systematic review and meta-analysis. *Clin Infect Dis* 2016;62:683-694. doi: 10.1093/cid/civ948.
- [124] Chen MH, Chen MH, Tsai CY, Chou CT, Lin HY, Huang DF, *et al*. Incidence and antiviral response of hepatitis C virus reactivation in lupus patients undergoing immunosuppressive therapy. *Lupus* 2015;24:1029-1036. doi: 10.1177/0961203315571465.
- [125] Belda O, Targett-Adams P. Small molecule inhibitors of the hepatitis C virus-encoded NS5A protein. *Virus Res* 2012;170:1-14. doi: 10.1016/j.virusres.2012.09.007.
- [126] Zaidan M, Mariotte E, Galicier L, Arnulf B, Meignin V, Vérine J, *et al*. Vasculitic emergencies in the intensive care unit: A special focus on cryoglobulinemic vasculitis. *Ann Intensive Care* 2012;2:31. doi: 10.1186/2110-5820-2-31.
- [127] Rodrigo D, Perera R, de Silva J. Classic polyarteritis nodosa associated with hepatitis C virus infection: a case report. *J Med Case Rep* 2012;6:305. doi: 10.1186/1752-1947-6-305.
- [128] Colucci G, Manno C, Grandaliano G, Schena FP. Cryoglobulinemic membranoproliferative glomerulonephritis: beyond conventional therapy. *Clin Nephrol* 2011;75:374-379. doi: 10.5414/CNP75374.
- [129] Butterly SJ, Pillans P, Horn B, Miles R, Sturtevant J. Off-label use of rituximab in a tertiary Queensland hospital. *Intern Med J* 2010;40:443-452. doi: 10.1111/j.1445-5994.2009.01988.x.
- [130] Koziolok MJ, Scheel A, Bramlage C, Groene HJ, Mueller GA, Strutz F. Effective treatment of hepatitis C-associated immune-complex nephritis with cryoprecipitate apheresis and antiviral therapy. *Clin Nephrol* 2007;67:245-249. doi: 10.5414/CNP67245.
- [131] Saadoun D, Resche-Rigon M, Thibault V, Piette JC, Cacoub P. Antiviral therapy for hepatitis C virus-associated mixed cryoglobulinemia vasculitis: a long-term followup study. *Arthritis Rheum* 2006;54:3696-3706. doi: 10.1002/art.22168.
- [132] Saadoun D, Aaron L, Resche-Rigon M, Pialoux G, Piette JC, Cacoub P. Cryoglobulinaemia vasculitis in patients coinfecting with HIV and hepatitis C virus. *AIDS* 2006;20:871-877. doi: 10.1097/01.aids.0000218551.62210.b5.
- [133] Neri S, Pulvirenti D, Mauceri B, Ignaccolo L, Azzolina R. A case of progression from type II cryoglobulinaemia to Waldenström's macroglobulinaemia in a patient with chronic hepatitis C. *Clin Exp Med* 2005;5:40-42. doi: 10.1007/s10238-005-0062-7.
- [134] Méndez P, Saeian K, Reddy KR, Younossi ZM, Kerdel F, Badalamenti S, *et al*. Hepatitis C, cryoglobulinemia, and cutaneous vasculitis associated with unusual and serious manifestations. *Am J Gastroenterol* 2001;96:2489-2493. doi: 10.1016/S0002-9270(01)02622-3.
- [135] Cacoub P, Maisonobe T, Thibault V, Gatel A, Servan J, Musset L, *et al*. Systemic vasculitis in patients with hepatitis C. *J Rheumatol* 2001;28:109-118.
- [136] Kiyomoto H, Hitomi H, Hosotani Y, Hashimoto M, Uchida K, Kurokouchi K, *et al*. The effect of combination therapy with interferon and cryofiltration on mesangial proliferative glomerulonephritis originating from mixed cryoglobulinemia in chronic hepatitis C virus infection. *Ther Apher* 1999;3:329-333. doi: 10.1046/j.1526-0968.1999.00196.x.
- [137] David WS, Peine C, Schlesinger P, Smith SA. Nonsystemic vasculitic mononeuropathy multiplex, cryoglobulinemia, and hepatitis C. *Muscle Nerve* 1996;19:1596-1602. doi: 10.1002/(SICI)1097-4598(199612)19:12<1596::AID-MUS9>3.3.CO;2-6.
- [138] Gentile J, De Stefano A, Di Flumeri G, Buonomo AR, Carlomagno C, Morisco F, *et al*. Concomitant interferon-alpha and chemotherapy in hepatitis C and colorectal cancer: a case report. *In Vivo* 2013;27:527-529.
- [139] Ayyub M, El-Moursy SA, Al-Abbas F. Outcome of combination antiviral therapy in chronic hepatitis C virus infection during therapy of acute lymphoblastic leukemia. *Saudi J Gastroenterol* 2011;17:283-286. doi: 10.4103/1319-3767.82586.
- [140] Papaevangelou V, Varsami M, Papadakis V, Zellos A, Parcharidou A, Pappayri S, *et al*. Hepatitis C treatment concomitant to chemotherapy as "salvage" therapy in children with hematologic malignancies. *Pediatr Infect Dis J* 2010;29:277-280. doi: 10.1097/INF.0b013e3181c2115a.
- [141] Waldron P. Interferon treatment of chronic active hepatitis C during therapy of acute lymphoblastic leukemia. *Am J Hematol* 1999;61:130-134. doi: 10.1002/(SICI)1096-8652(199906)61:2<130::AID-AJH10>3.0.CO;2-M.
- [142] Pardo-Yules B, Gallego-Durán R, Eslam M, García-Collado C, Grande L, Paradis C, *et al*. Thalidomide with peginterferon alfa-2b and ribavirin in the treatment of non-responders genotype 1 chronic hepatitis C patients: proof of concept. *Rev Esp Enferm Dig* 2011;103:619-625. doi: 10.4321/S1130-01082011001200003.