

Acute Hepatic Phenotype of Wilson Disease: Clinical Features of Acute Episodes and Chronic Lesions Remaining in Survivors

Hisao Hayashi¹, Yasuaki Tatsumi¹, Shinsuke Yahata², Hiroki Hayashi³, Kenji Momose⁴, Ryohei Isaji⁵, Youji Sasaki⁵, Kazuhiko Hayashi⁶, Shinya Wakusawa^{*7} and Hidemi Goto⁶

¹Department of Medicine, Aichi-Gakuin University School of Pharmacy, Nagoya, Japan; ²Department of Gastroenterology, Hyogo Prefectural Kakogawa Medical Center, Kakogawa, Japan; ³Department of Gastroenterology, Kita-Harima Medical Center, Ono, Japan; ⁴Department of Gastroenterology, Kobe University School of Medicine, Kobe, Japan; ⁵Department of Gastroenterology, Konan Kosei Hospital, Konan, Japan; ⁶Department of Gastroenterology and Hepatology, Nagoya University Graduate School of Medicine, Nagoya, Japan; ⁷Department of Medical Laboratory Sciences, Nagoya University Graduate School of Medicine, Nagoya, Japan

Abstract

Background and Aims: Wilson disease (WD) is an inherited disorder of copper metabolism, and an international group for the study of WD (IGSW) has proposed three phenotypes for its initial presentation: acute hepatic, chronic hepatic, and neurologic phenotypes. Characterization of the acute hepatic phenotype may improve our understanding of the disease. **Methods:** Clinical features of 10 WD patients with the acute hepatic phenotype and characteristics of chronic lesions remaining in survivors were assessed by the European Association for the Study of the Liver (EASL) guidelines. **Results:** All six patients younger than 30 years had survived an acute episode of hemolytic anemia with residual liver disease of cirrhosis or chronic hepatitis. The acute episode was self-limiting in two of the four patients over the age of 30 years and progressed to acute liver failure in the other two patients. One of the two survivors had residual liver disease of chronic hepatitis, while the other had chronic hepatitis and neurologic disease. Neurologic disease remained in a patient who successfully received a liver transplantation. During acute episodes, serum levels of aspartate aminotransferase (AST) and alanine aminotransferase (ALT) changed rapidly along with anemia. Liver-specific ALT levels were age-dependently correlated with hemoglobin (Hb) concentrations. Enzyme reduction was milder for AST than ALT, which resulted in a high AST/ALT ratio in the anemic stage. The anemic stage in two patients transformed to acute liver failure. **Conclusions:** All survivors of an acute episode of the acute hepatic phenotype had residual liver disease or both liver and neurologic diseases. The rapid changes in liver enzymes during the acute episode and the liver and neurologic

diseases remaining in survivors may provide a better understanding of WD.

© 2015 The Second Affiliated Hospital of Chongqing Medical University. Published by XIA & HE Publishing Ltd. All rights reserved.

Introduction

The cloning of *ATP7B*, the gene responsible for Wilson disease (WD), confirmed that the primary defect is in the intra-hepatic transport of copper, which is associated with a complete block of the physiological biliary secretion of copper.¹⁻⁵ The liver pathology of an individual with disease-causing *ATP7B* mutations is always progressive, from almost normal to cirrhosis.⁶ With the progression of copper toxicosis, extra-hepatic organ damage is inevitable in patients when not treated. Complications include copper-induced Coombs-negative hemolysis and neurological diseases associated with copper accumulation.^{4,5} An acute episode of hemolysis is self-limiting in most patients but may be transformed to acute liver failure (ALF) in some patients. These complex clinical features may delay a definitive diagnosis of primary liver disease of WD. Therefore, an international group for the study of WD (IGSW) proposed three phenotypes as the first presentation of WD: acute hepatic, chronic hepatic, and neurologic phenotypes.⁷

The standard liver function tests of serum aspartate aminotransferase (AST) and alanine aminotransferase (ALT) are widely applied in the diagnosis of acute and chronic liver disease. In WD, those levels are controlled by multiple factors: histological stage-dependent changes,⁸ marked reduction by relieved oxidative stress,⁹ selective increase of AST from erythrocytes in hemolysis,¹⁰ etc. Therefore, the state of these liver enzymes has yet to be determined in the diagnosis of WD. The IGSW did not include AST and ALT levels in the scoring system for the diagnosis of WD.⁷ On the other hand, the AST/ALT ratios were found to be greater than 4.0 in six cases of WD ALF.¹¹ The low levels of AST and ALT and the discrepancy between the two liver enzymes were also reported in two patients with WD ALF.¹² These observations were confirmed in 16 patients.¹³ The European Association for the Study of the Liver (EASL) clinical practice guidelines recommend an AST/ALT ratio of more than 2.2 as

Keywords: Aminotransferase; Neurologic disease; Liver disease; Hemoglobin.
Abbreviations: ALF, acute liver failure; ALT, alanine aminotransferase; AST, aspartate aminotransferase; CNS, central nervous system; CP, ceruloplasmin; EASL, European Association for the Study of the Liver; GI, gastrointestinal; Hb, hemoglobin; HE, hematoxylin & eosin; IGSW, international group for the study of Wilson disease; K-F rings, Kayser Fleisher rings; WD, Wilson disease.

Received: 29 September 2015; Revised: 27 November 2015; Accepted: 29 November 2015

* DOI: 10.14218/JCTH.2015.00032.

*Correspondence to: Shinya Wakusawa, Department of Medical Laboratory Sciences, Nagoya University Graduate School of Medicine, 1-1-20 Daiko-minami, Higashi-ku, Nagoya 461-8673, Japan. Tel: +81-719-1558, Fax: +81-719-1558, E-mail: wakusawa@met.nagoya-u.ac.jp

a reliable index for the differential diagnosis of WD ALF from nonWD ALF.¹⁴

Characterizing the profiles of the standard liver function tests of AST and ALT and clarifying their relationship with other biochemical parameters in the acute hepatic phenotype are essential for a better understanding of WD by hepatologists who are responsible for its diagnosis and treatment.

Methods

This study was approved by the review boards evaluating research involving human subjects at the Aichi Gakuin University School of Pharmacy and participating hospitals.

Patients

Ten patients with the acute hepatic phenotype of WD were enrolled in this study. The diagnosis and phenotype classification of WD were based on the ISGW proposals with modification.⁷ The entry criterion of this study was not only a previously apparently healthy subject, as defined in the original classification, but also an asymptomatic patient with a past history of WD. All patients received the ATP7B test. A long-range polymerase chain reaction was applied to the 21 exons and their boundaries of the *ATP7B* gene.¹⁵ The clinical features of patients Y-1, Y-6, and O-2 were separately reported elsewhere.¹⁵⁻¹⁷

Close observation of patients

Close observation of patients revealed that acute symptoms naturally resolved in the majority of patients and transformed to a fatal condition of ALF in a minority of patients over the 6 week observation period. Therefore, this study focused on characterizing the clinical features of survivors from the acute episode of the acute hepatic phenotype, and some data from patients who progressed to ALF were excluded from the analysis. The clinical features of patients studied included the hemoglobin (Hb) concentration and serum levels of ceruloplasmin (CP), albumin, total bilirubin, AST, and ALT.

Staging of acute hepatic phenotype, subgroups of patients, and chronic diseases

Short-term changes in biochemical parameters of the acute hepatic phenotype were evaluated in the pre-anemic [stage 1], anemic [stage 2], and anemia recovery [stage 3] stages of survivors with nontransplantation treatment. Stages 1 and 2 were available in patients with ALF.

Because the biochemical parameters and chronic diseases remaining in survivors and their final diagnoses were age-dependent, comparative studies were performed between two subgroups: six patients younger than the age of 30 years and four patients older than 30.

The clinical features and biochemical parameters of three patients in the pre-anemic stage were pathological, indicating that these patients were affected by chronic diseases of WD. Based on a hypothesis that chronic diseases of WD present before the onset of the acute episode reappeared at the recovery stage of survivors with nontransplantation treatment, the AST and ALT levels in the recovery stage were alternative parameters of chronic liver disease. On combining biochemical parameters with histological information, the

disease states of survivors were assessed using the EASL guidelines.¹⁴

Liver histology and alternative liver imaging

Liver biopsy, when permitted, was performed in the recovery stage. A removed liver was available for histological study in a patient who received orthotopic liver transplantation. Standard histology of the liver included hematoxylin & eosin (HE) stain, Azan stain, and rhodanine stain for copper. For two patients in whom liver specimens were not available, the liver histology was alternatively replaced with a liver image using either computed tomography (CT) or magnetic resonance imaging (MRI) on admission.

Statistical analysis

The Student's t-test was used to determine statistical differences in the biochemical parameters. Statistically, $p < 0.01$ or $p < 0.05$ was considered significant. The correlation between Hb concentration and serum level of ALT was determined in the two subgroups. All statistical analyses were performed using Microsoft Excel 2010.

Results

Clinical features of patients with the acute hepatic phenotype

Clinical features of the six younger and four older patients on admission are summarized in Table 1. The ages of the younger patients ranged between 6 and 24 years, while the ages of the older patients ranged between 32 and 53 years. Clinical information before the acute episode (Stage 1) was available in three patients. A 6-year-old female patient revisited the hospital for jaundice after a 2 month observation period for chronic active hepatitis of unknown etiology.¹⁶ A 24-year-old male patient revisited the hospital for the resumption of penicillamine treatment for WD after a 5 year interruption. One month later, he developed severe hemolytic jaundice.¹⁷ A 36-year-old female patient with WD favorably treated with a zinc regimen had received steroid therapy for sterilization, followed by an acute episode of hemolytic jaundice.^{15,17} The anemic stage (Stage 2) on admission was noted in three younger patients and two older patients, and the recovery stage from anemia (Stage 3) was noted in one younger and one older patient. Serum levels of CP on admission were low in all except one patient, and serum levels of albumin were all low. There were no differences in CP or albumin between the two subgroups. All patients had Kayser-Fleischer (K-F) rings.

All patients, except one, were homozygous or compound heterozygous for *ATP7B* mutations responsible for WD copper toxicosis. A 32-year-old female was heterozygous for the *ATP7B* mutation. She received a diagnostic score of 7 points on the standard tests for WD: serum CP, 10 mg/dL (1); serum Cu, 88 µg/dL (0); urinary Cu, 1,770 µg/day (2); Coombs test <10 (1); positive K-F rings (2); positive histochemical rhodanine test (1).⁷ All six younger patients survived the acute episode after conservative treatment, including short-term penicillamine. In contrast, two of the four older patients survived after the conservative treatment, and two other older patients developed ALF. A patient affected by ALF, which is otherwise fatal, successfully received an orthotopic liver

Table 1. Clinical features of patients with the acute hepatic phenotype of Wilson disease on admission and short-term treatment during the acute episode

Patients	Age/sex	Stage ^{*1}	CP (mg/dL) (20>) ^{*2}	Alb (g/dL) (3.5>) ^{*2}	K-F rings	ATP7B-1	ATP7B-2	Anti-Cu regimen ^{*3}
Y-1 ^{*3}	6/F	1	8.0	3.4	Yes	2333G>T, homozygote		Low-D of Pc for a week
Y-2	9/F	3	1.0	2.9	Yes	2785A>G	3104G>T	Low-D of Pc for 2 weeks
Y-3	11/M	2	2.5	2.3	Yes	3787delG, homozygote		Low-D of Pc for 2 weeks
Y-4	17/M	2	9.0	3.2	Yes	2871delC	3643G>T	Non
Y-5	18/F	2	5.0	3.3	Yes	2621C>T	2650del3	Low-D of Pc for 2 weeks
Y-6 ^{*4}	24/M	1	21.9	3.2	Yes	1708-5T>G, homozygote		Full-D of Pc for 4 weeks
		Mean	7.9	3.1				
		SD	7.5	0.4				
O-1	32/F	3	11.8	3.1	Yes	2871delC	None	Low-D of Pc for 4 weeks
O-2 ^{*4}	36/F	1	12.6	3.4	Yes	3800A>C	Exon5-9, 3837bpdel	Under maintenance therapy with Zn
O-3	40/M	2	6.9	2.1	Yes	2659delG	4007T>C	Low-D of Pc for 2 weeks
O-4	53/F	2	7.9	1.6	Yes	1708-5T>G	2755C>G	Non
		Mean	9.8	2.6				
		SD	2.8	0.8				

Alb, albumin; CP, ceruloplasmin; F, female; K-F, Kayser Fleischer; low-D, low-dose; M, male; O, older patient; Pc, penicillamine; Y, younger patient.

*¹ Stage 1: pre-anemic, 2: anemic, and 3: anemia recovery, on patient's first consultation, followed by blood sampling.

*² Normal ranges are expressed in parenthesis.

*³ As previously reported by Kajita M, *et al.*,¹⁶ the patient had chronic active hepatitis of unknown etiology before the onset of the acute hepatic phenotype.

*⁴ The patients were previously reported by Tatsumi Y, *et al.*^{15,17}

Serum levels of ceruloplasmin (Cp) were low except for one patient. Albumin concentrations were low, and Kayser-Fleischer rings were detected in all patients. One patient was heterozygous for ATP7B mutation. The acute episode of the acute hepatic phenotype transformed to acute liver failure in 2 patients (O-2 and 4). One of them died, and the other was saved by liver transplantation.

transplantation. Another patient showed a fatal course, with no opportunity for transplantation.

Rapid changes of biochemical parameters in the three stages

Figures 1 and 2 illustrate the rapid changes in biochemical parameters over 1 month acute episodes in two survivors representative of the two subgroups of younger and older patients, respectively. These figures show marked changes in the biochemical parameters of Hb, bilirubin, and ALT in the pre-anemic, anemic, and anemia recovery stages. The ALT profile of the younger patient was characterized by rapid changes of high pre-anemic, low anemic, and high recovery stage levels (Fig. 1). These of the older patient remained almost normal during the acute episode (Fig. 2). The pre-anemic ALT levels of the three patients were all pathologically high. Regarding two patients for whom complete data on the three stages were available, there were no changes between their levels in pre-anemic and recovery stages, being 185 vs. 160 and 179 vs. 151 IU/L, respectively.

Comparisons of the biochemical parameters between the anemic and chronic stages

The biochemical parameters in the anemic and chronic stages of the younger and older patients are summarized in Table 2. Hb was lower in the anemic stage than in the chronic stage in both the younger and older patients. Total bilirubin did not

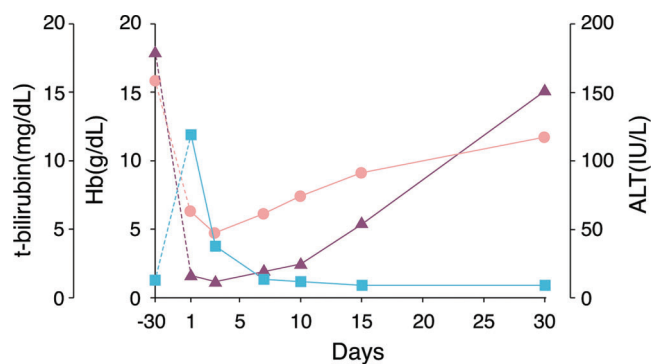


Fig. 1. Rapid changes of Hb, bilirubin, and ALT in a younger patient with the acute hepatic phenotype of Wilson disease. A 17-year-old male patient revisited our hospital 5 years after the discontinuation of penicillamine treatment for Wilson disease (WD). At 1 month after the resumption of drug therapy at a maintenance dose, the patient developed acute hemolytic jaundice characterized by severe anemia and a reduction in serum alanine aminotransferase (ALT) level. The hemoglobin (Hb) concentration changed in parallel with the serum ALT level. A high ALT level recurred in the recovery stage. No disturbance of consciousness was noted. These findings suggest that anemia induced the transient reduction of ALT levels, and his underlying chronic liver disease manifested twice, before the acute episode and in the recovery stage. We postulated that this patient with WD was complicated by copper-induced hemolysis.
Hb: ●—●, total bilirubin (t-bilirubin): ■—■, ALT: ▲—▲.

change between the two stages. Therefore, there were no differences in Hb or bilirubin between the younger and older patients, suggesting these parameters were not age-dependent. Both AST and ALT were lower in the anemic

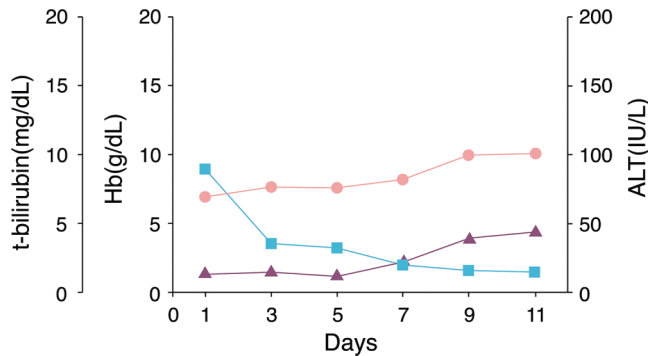


Fig. 2. Changes of Hb, bilirubin, and ALT in an older patient with the acute hepatic phenotype of Wilson disease. A 40-year-old male patient was admitted for jaundice and finger tremor. Based on blood tests, the acute clinical features of a hemolytic episode of Wilson disease (WD) with a reduced hemoglobin (Hb) level and indirect hyperbilirubinemia were observed. Brain images were consistent with the lenticular degeneration of WD. Anemia and jaundice spontaneously resolved within 2 weeks. Consciousness was normal throughout the course, but finger tremor remained in the recovery stage. The serum alanine aminotransferase (ALT) level increased from the lower to upper limits of the normal range. Liver biopsy in the recovery stage showed histochemical copper-positive precirrhosis. We postulate that this patient with WD was double-complicated by hemolysis and central nervous system (CNS) disorder. Hemolysis was self-limited, while CNS complication remained.
Hb: ●—●, total bilirubin (t-bilirubin): ■—■, ALT: ▲—▲.

stage than in the chronic stage of the younger patients (AST: 75 ± 34 vs. 144 ± 40 IU/L and ALT: 22 ± 14 vs. 136 ± 32 IU/L, respectively), but not in the older patients (AST: 76 ± 34 vs. 74 ± 40 IU/L and ALT: 31 ± 19 vs. 42 ± 9 IU/L, respectively), probably because these enzyme levels in the chronic stage were high enough to change in the younger patients, but not in the older patients. The serum levels of AST and ALT in the anemic stage were not different between the younger and older patients (AST: 75 ± 34 vs. 76 ± 34 IU/L and ALT: 22 ± 14

vs. 31 ± 19 IU/L, respectively), but these parameters in the chronic stage were different in ALT (136 ± 32 vs. 42 ± 9 IU/L) but not in AST (144 ± 40 vs. 74 ± 40 IU/L). Therefore, ALT levels in the chronic stage were age-dependent, but those in the anemic stage were not. AST/ALT ratios of younger patients were higher in the anemic stage than in the chronic stage. These levels in older patients were not different between the two stages. All the patients, except for one who died from ALF, had ratios over 2.2, an index of the differential diagnosis of WD ALF from nonWD ALF.¹⁴ The ratios of the two patients showing transformation to ALF were 1.7 and 2.6, respectively.

Relationship between Hb concentration and serum level of ALT

Anemia was closely associated with reduced ALT levels regardless of patient age (7.1 ± 2.4 g/dL in Hb vs. 24 ± 17 IU/L in ALT), but the response was different in the two age groups. There was a close correlation between Hb and ALT in the younger patients: $ALT = 15.6 \times Hb - 69.9$, $r = 0.85$ (Fig. 3). There was also a close correlation in older patients when end-stage ALF patients were excluded: $ALT = 5.7 \times Hb - 19.5$, $r = 0.88$ (Fig. 4). Correlations were less marked between Hb and AST.

Residual disease in survivors and alternative diagnosis for their life-long treatment

Table 3 summarizes the structure of the livers remaining in survivors and the removed one at transplant, presentations by EASL guidelines¹⁴, and residual disease in survivors. All patients appeared with hemolytic jaundice or its recovery stage. One older patient suffered from finger tremor at the first presentation. The liver specimens obtained from seven patients in the recovery stage all showed advanced liver

Table 2. Biochemical parameters during the acute episode of the acute hepatic phenotype

Patients	Hb (g/dL)		T-Bilirubin (mg/dL)		AST (IU/L)		ALT (IU/L)		AST/ALT Ratio	
	Anemic	Chronic	Anemic	Chronic	Anemic	Chronic	Anemic	Chronic	Anemic	Chronic
Younger (n=6)	6.7 ± 2.4	12.8 ± 0.5	7.6 ± 3.6	1.4 ± 0.8	75 ± 34	144 ± 40	22 ± 14	136 ± 32	3.9 ± 1.2	1.1 ± 0.2
Anemic vs. chronic	$p < 0.01$		$p < 0.05$		$p < 0.05$		$p < 0.01$		$p < 0.01$	
Older (n=4)	7.0 ± 1.4	11.8 ± 0.9	12.2 ± 6.5	1.7 ± 1.0	76 ± 34	74 ± 40	31 ± 19	42 ± 9	$3.0 \pm 1.5^*$	1.7 ± 0.6
Anemic vs. chronic	$p < 0.05$		Nd		Nd		Nd		Nd	
Younger vs. older	Nd	Nd	Nd	Nd	Nd	Nd	Nd	$p < 0.01$	Nd	Nd

ALF, acute liver failure; ALT, alanine aminotransferase; AST, aspartate aminotransferase; Hb, hemoglobin; nd, no significant difference.

* The AST/ALT ratios were 1.7 and 2.6 in the anemic stage of the 2 patients showing transformation to ALF.

Biochemical parameters rapidly changed during the acute episode so that assessments were done at the 3 stages of pre-anemic, anemic, and anemia recovery. The data of chronic stages were defined as either pre-anemic or anemia recovery, or their mean. There were no data on anemia recovery in the 2 patients showing transformation to ALF.

Hb concentrations and serum levels of total bilirubin showed rapid changes during the acute episode of hemolytic jaundice as if anemia and jaundice were synchronized with the profiles of the liver enzymes of AST and ALT. Hb concentrations were different between the anemic and chronic stages in both the younger and older patient groups, while total bilirubin levels were different between the anemic and chronic stages in the younger patient group. AST and ALT levels were different between the anemic and chronic stages in the younger patient group. ALT levels in the chronic stage were different between younger and older patient groups. AST/ALT ratios of the younger patient group were lower in the anemic stage than in the chronic stage, but they were not different in the older patient group.

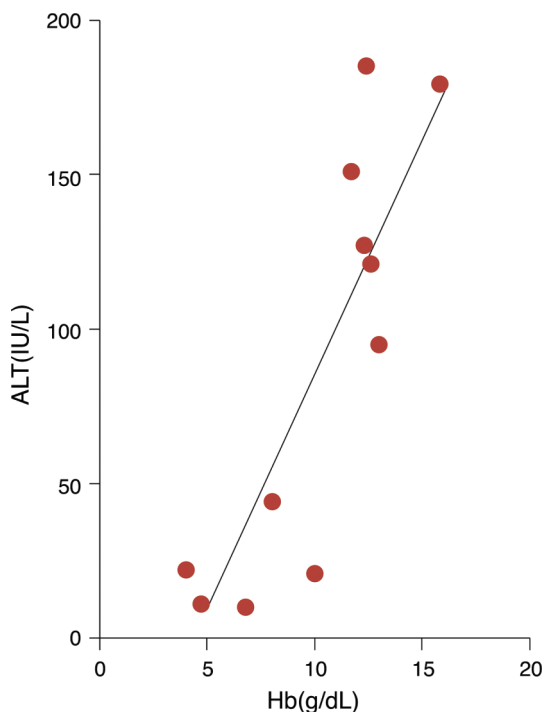


Fig. 3. A close correlation between Hb and ALT in the younger patients. Liver disease activity expressed by serum alanine aminotransferase (ALT) levels was suggested to be hemoglobin (Hb)-dependent during acute episodes of the acute hepatic phenotype in the younger patients. Reduced levels of ALT were always associated with severe anemia after hemolysis, probably due to transient hypoxia.
 $ALT = 15.6 \times Hb - 69.9$, $r = 0.85$.

disease, such as cirrhosis, precirrhosis, or precirrhosis with chronic active hepatitis (Fig. 5). Rhodanine stain was positive in all liver tissues for histochemical copper. There were no traces of acute episodes of hemolytic jaundice in their livers. Liver images of two other patients were also consistent with chronic liver disease. The removed liver in the transplant patient showed cirrhosis with severe cholestasis.

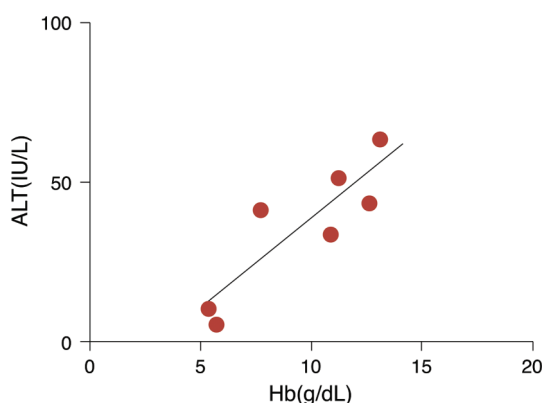


Fig. 4. A close correlation between Hb and ALT in the older patients. Liver disease activity expressed by serum alanine aminotransferase (ALT) levels was also hemoglobin (Hb)-dependent during acute episodes of the acute hepatic phenotype in the older patients when data on the terminal state of acute hepatic failure were excluded. ALT levels were relatively low and their changes were mild in relation to the severity of anemia compared with the younger patients.
 $ALT = 5.7 \times Hb - 19.5$, $r = 0.88$.

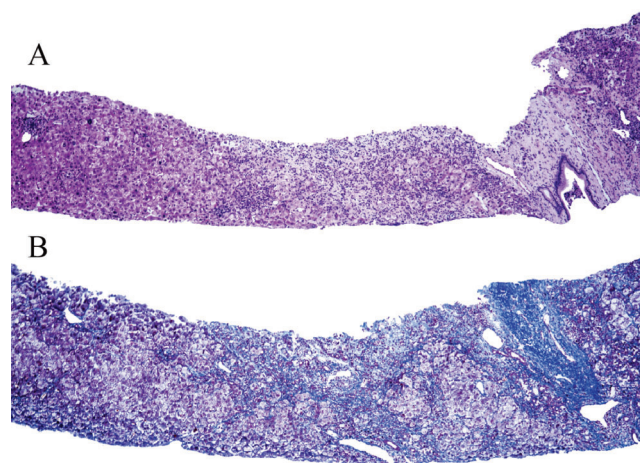


Fig. 5. Liver specimen of a survivor obtained in the recovery stage of the self-limiting acute episode of the acute hepatic phenotype. Upper hematoxylin & eosin (HE) stain: The liver tissue was separated into two parts by a wide mesenchymal band. Adjacent parenchyma was affected by mononuclear cell infiltration. In total, there were three fibrous bands transversely located in the cylindrical tissue obtained by needle biopsy. Lower Azan stain: In addition to a wide fibrous band, there was another fibrotic lesion widely distributed in the parenchyma. Some aggregated hepatocytes were surrounded by such fibrous bands. No cholestasis remained. We postulate that these hepatic lesions had developed since birth in this patient. Bar indicates 300 μ m.

Acute hepatic phenotypes of the IGSW proposal⁷ in seven patients were divided by the two terms of liver disease-hemolysis during the acute episode and liver disease-cirrhosis or chronic hepatitis in the anemia recovery stage based on the EASL guidelines.¹⁴ Liver disease-hemolysis was self-limiting, and neurologic disease remained in one patient. In two patients, liver disease-hemolysis transformed to liver disease-ALF. One recipient of orthotropic liver transplant had a residual symptom of dysarthria at the examination on discharge. WD, WD with central nervous system (CNS) complication, or liver recipient with CNS complication was an alternative diagnosis for the life-long treatment of the survivors.

Discussion

Although this study was preliminary, as the number of patients was limited, there were three important findings regarding the acute hepatic phenotype of WD: the acute episode of this phenotype was not always associated with a poor prognosis, transient reductions of Hb during the acute episode were associated with an age-dependent reduction in the level of the liver-specific enzyme ALT, and residual disease remained in the liver, CNS, or both the liver and CNS of survivors from the acute episode.

The acute episode of this phenotype may be induced by sudden release of copper into the circulation by variable triggers.^{4,5,18} Two of the three patients whose information on pre-anemic stages was available had received a full dose of penicillamine and steroids for sterilization therapy, respectively. Eight of the 10 patients survived the acute episode beyond a month after developing jaundice or anemia, or a combination of both. Two patients ultimately developed ALF. In addition to the differential diagnosis of ALF from self-limiting disease,¹⁹ analyses of the rapid changes of serum

Table 3. Phenotypes by IGSW, liver structures, presentations by EASL, and residual diseases in survivors

Patients	Phenotypes by IGSW	Liver structures [liver imaging]	The 1 st /2 nd presentations by EASL [no definition in the system]	Residual diseases in survivors
Y-1	Acute hepatic	Pre-LC \subseteq CAH	LD-hemolysis/LD-CH	WD
Y-2	Acute hepatic	[Pre-LC]	LD-hemolysis/LD-CH	WD
Y-3	Acute hepatic	LC	LD-hemolysis/LD-LC	WD
Y-4	Acute hepatic	Pre-LC	LD-hemolysis/LD-CH	WD
Y-5	Acute hepatic	LC	LD-hemolysis/LD-LC	WD
Y-6	Acute hepatic	LC	LD-hemolysis/LD-LC	WD
O-1	Acute hepatic	Pre-LC \subseteq CAH	LD-hemolysis/LD-CH	WD
O-2	Acute hepatic	[LC]	LD-hemolysis/LD-ALF	
O-3	Acute hepatic	Pre-LC	LD-hemolysis*/Neurologic disease	WD with CNS-C
O-4	Acute hepatic	LC	LD-hemolysis/LD-ALF*/[post LT*]	Recipient with CNS-C


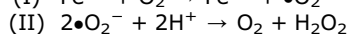
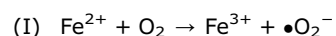
ALF, acute liver failure; CAH, chronic active hepatitis; CNS-C, central nervous system complication; CH, chronic hepatitis; EASL, European Association for the Study of the Liver; IGSW, international group for the study of Wilson disease; LC, liver cirrhosis; LD, liver disease; LT, liver transplantation; O, older patient; WD, Wilson disease; Y, younger patient. *Neurological symptoms of finger tremor or dysarthria due to copper toxicosis were found.

When WD is defined as a chronic liver disease due to ATP7B dysfunction, the acute hepatic phenotype may be a pathological condition of WD acutely complicated by hemolysis. Some aged patients with the acute hepatic phenotype may have an additional chronic complication of neurologic disease. Their recovery state from hemolysis may be alternatively WD, WD with CNS complication, and CNS disorder remained in a recipient of orthotopic liver transplant.

AST and ALT levels and their relationships with the marked reduction of Hb concentrations in the survivors may also be important.

Rapid changes of serum ALT levels, which are more reliable parameters of liver cell necrosis than those of AST with an erythrocyte fraction in acute hemolysis, were age-dependent and closely associated with the severity of anemia or reduction of the Hb concentration. Because our younger patients were found in the early stage of the decreasing phase,⁸ AST and ALT profiles showed marked changes as compared with these of older patients. Similar observations were reported in Germany.¹² Serum ALT levels were markedly reduced in two patients with the ALF of WD. Discrepant changes of AST and ALT were also observed in these patients, and these observations were confirmed in the 16 patients with WD ALF,¹³ which resulted in the EASL guidelines.¹⁴ The high ratios of AST/ALT were observed in the anemic stage of all patients and not specific to the two patients showing transformation to ALF in this study. The second anemic stage may be sustained in patients showing transformation to ALF without recovery from hyperbilirubinemia and the high AST/ALT state.

The reduction of serum ALT levels is known to be a favorable effect of anemia on chronic hepatitis C. Severe post-gastrointestinal (GI) bleeding anemia was reported to reduce transiently AST and ALT levels of patients with hepatitis C virus (HCV)-chronic hepatitis and cirrhosis.²⁰ This effect disappeared in a few weeks when anemia was ameliorated. The synchronized reduction of Hb concentration and ALT activity may represent a relief from oxidative stress caused by ferrous ion (I), super oxide dismutase (SOD) (II), and the Fenton reaction (III).^{21,22}



Cuprous ions may have a similar potential to ferrous ions in the system. Considering that the acute episode of acute hepatic WD is associated with pathological conditions rich in

both cuprous ions released from stored copper and ferrous ions derived from Hb iron, the main player in oxidative stress may be hypoxia secondary to reduced levels of Hb to carry oxygen to the body tissues. Severe anemia occurring post-hemolysis may suppress the production of reactive oxygen species, even under a pathological condition rich in both cuprous and ferrous ions.^{21,22} It may be important to note the different anemic effects of GI bleeding and hemolysis on the levels of AST and ALT. GI bleeding induces a marked parallel reduction of both enzymes,²⁰ while hemolytic anemia has a similar potential to reduce ALT levels and to modify AST levels by increasing the erythrocyte fraction.¹⁰ The erythrocyte AST may also play an important role in the differential diagnosis of WD ALF from nonWD ALF.¹¹⁻¹⁴ The roles of the oxygen-carrier protein Hb in the acute phenotype of WD should be clarified in the near future.

The anemic stage associated with hypoalbuminemia, hyperbilirubinemia, and liver enzyme reduction was sustained without recovery from anemia in the two patients transformed to ALF. The transient hypoxia-induced relief of hepatocytes from oxidative stress may reduce serum AST and ALT levels,^{9,20} but hypoxia per se may not improve liver function, such as protein synthesis and bilirubin transport, which need large amounts of energy. A poor prognosis for patients with acute hepatic phenotype should be predicted according to King's score system,¹⁹ followed by prompt transfer to a liver center for transplantation.

All survivors had residual disease in the liver or both the liver and CNS. Our older patients were in the late stage of the decreasing phase of the AST and ALT levels,⁸ and their liver disease was almost masked by a normal range of liver enzymes. Our survivors, even with biochemically masked disease, were treated by anticopper regimens under an alternative diagnosis: WD, WD with CNS complication, and CNS complication in an orthotopic liver recipient (Table 3). The acute episode of the acute hepatic phenotype was a particular complication affecting patients with WD or WD with CNS complication.

Conclusions

Elucidation of the Hb-dependent reduction of serum ALT levels during the acute episode of acute hepatic WD and identification of diseases remaining in the survivors from the acute episode may improve our understanding of the primary hepatic copper toxicosis of WD and its extrahepatic complications.

Conflict of interest

None.

Author contributions

Conception and design (HH, SW), provision of study materials or patients (SY, HH, KM, RI, YS), gene analysis (YT, SW), data analysis and interpretation (HH, KH, SW, HG), manuscript writing and final approval of manuscript (all authors).

References

- [1] Bull PC, Thomas GR, Rommens JM, Forbes JR, Cox DW. The Wilson disease gene is a putative copper transporting P-type ATPase similar to the Menkes gene. *Nat Genet* 1993;5:327–337. doi: 10.1038/ng1293-327.
- [2] Petrukhin K, Fischer SG, Pirastu M, Tanzi RE, Chernov I, Devoto M, *et al*. Mapping, cloning and genetic characterization of the region containing the Wilson disease gene. *Nat Genet* 1993;5:338–343. doi: 10.1038/ng1293-338.
- [3] Yamaguchi Y, Heiny ME, Gitlin JD. Isolation and characterization of a human liver cDNA as a candidate gene for Wilson disease. *Biochem Biophys Res Commun* 1993;197:271–277. doi: 10.1006/bbrc.1993.2471.
- [4] Gitlin JD. Wilson disease. *Gastroenterology* 2003;125:1868–1877. doi: 10.1053/j.gastro.2003.05.010.
- [5] Roberts EA, Schilsky ML. Diagnosis and treatment of Wilson disease: An update. *Hepatology* 2008;47:2098–2111. doi: 10.1002/hep.22261.
- [6] Stromeyer FW, Ishak KG. Histology of the liver in Wilson's disease: a study of 34 cases. *Am J Clin Pathol* 1980;73:12–24.
- [7] Ferenci P, Caca K, Loundianos G, Mieli-Vergani G, Tanner S, Sternlieb I, *et al*. Diagnosis and phenotypic classification of Wilson disease. *Liver Int* 2003;23:139–142. doi: 10.1034/j.1600-0676.2003.00824.x.
- [8] Katano Y, Hayashi K, Hattori A, Tatsumi Y, Ueyama J, Wakusawa S, *et al*. Biochemical staging of the chronic hepatic lesions of Wilson disease. *Nagoya J Med Sci* 2014;76:139–148.
- [9] Shiono Y, Wakusawa S, Hayashi H, Takikawa T, Yano M, Okada T, *et al*. Iron accumulation in the liver of male patients with Wilson's disease. *Am J Gastroenterol* 2001;96:3147–3151. doi: 10.1111/j.1572-0241.2001.05269.x.
- [10] Lippi G, Salvagno GL, Montagnana M, Brocco G, Guidi GC. Influence of hemolysis on routine clinical chemistry testing. *Clin Chem Lab Med* 2006;44:311–316. doi: 10.1515/CCLM.2006.054.
- [11] Berman DH, Leventhal RI, Gavaler JS, Cadoff EM, Van Thiel DH. Clinical differentiation of acute Wilsonian hepatitis from other causes of hepatic failure. *Gastroenterology* 1991;100:1129–1134.
- [12] Herrmann S, Hofmann W, Theilmann L. Acute liver failure as the initial manifestation of Wilson disease. *Med Klin (Munich)* 1995;90:456–461.
- [13] Korman JD, Vollenberg I, Baiko J, Webster J, Schiodt FV, Squires RH Jr, *et al*. Screening for Wilson disease in acute liver failure: a comparison of currently available diagnostic tests. *Hepatology* 2008;48:1167–1174. doi: 10.1002/hep.22446.
- [14] European Association for Study of Liver. EASL Clinical practice guidelines: Wilson disease. *J Hepatol* 2012;56:671–685. doi: 10.1016/j.jhep.2011.11.007.
- [15] Tatsumi Y, Shinohara T, Imoto M, Wakusawa S, Yano M, Hayashi K, *et al*. The potential of the international scoring system for diagnosis of Wilson disease to differentiate Japanese patients who need anti-copper treatment. *Hepatol Res* 2011;41:887–896. doi: 10.1111/j.1872-034X.2011.00835.x.
- [16] Kajita M, Tanaka A, Nakagawa T. A six-year-old girl with Wilsonian hemolytic episode. *Jpn J Pediatr* 1991;44:2445–2454 (in Japanese).
- [17] Tatsumi Y, Hattori A, Hayashi H, Ikoma J, Kaito M, Imoto M, *et al*. Current State of Wilson disease patients in central Japan. *Inter Med* 2010;49:809–815. doi: 10.2169/internalmedicine.49.2931.
- [18] Czlonkowska A. A study of haemolysis in Wilson's disease. *J Neurol Sci* 1972;16:303–314. doi: 10.1016/0022-510X(72)90194-3.
- [19] Dhawan A, Taylor RM, Cheeseman P, De Silva P, Katsiyiannakis L, Mieli-Vergani G. Wilson's disease in children: 37-year experience and revised King's score for liver transplantation. *Liver Transpl* 2005;11:441–448. doi: 10.1002/lt.20352.
- [20] Kato S, Arao M, Kuriki J, Tagaya T, Takiya S, Kato K, *et al*. Biochemical improvement of chronic hepatitis C after gastrointestinal bleeding. *Nagoya J Med Sci* 1994;57:153–157.
- [21] Britton RS. Metal-induced hepatotoxicity. *Semin Liver Dis* 1996;16:3–12. doi: 10.1055/s-2007-1007214.
- [22] Bonkovsky HL. Therapy of hepatitis C: other options. *Hepatology* 1997;26:143S–151S. doi: 10.1002/hep.510260725.