

Percutaneous Cryoablation for Liver Cancer

Li-Zhi Niu^{1,2}, Jia-Liang Li² and Ke-Cheng Xu^{*1,2}

¹Fuda Cancer Hospital, Jinan University School of Medicine, Tianhe District, Guangzhou, China; ²Guangzhou Fuda Cancer Institute, Tianhe District, Guangzhou, China

Abstract

Based on the primary tumor site, liver cancer can be divided into two categories: (1) primary liver cancer and (2) metastatic cancer to the liver from a distant primary site. Guided cryoablation via many imaging methods induces iceball formation and tumor necrosis and is an attractive option for treating unresectable hepatocellular carcinoma (HCC) and metastatic liver cancer. There are several advantages to using cryoablation for the treatment of liver cancer: it can be performed percutaneously, intraoperatively, and laparoscopically; iceball formation can be monitored; it has little impact on nearby large blood vessels; and it induces a cryo-immunological response *in situ*. Clinically, primary research has shown that percutaneous cryoablation of liver cancer is relatively safe and efficient, and it can be combined with other methods, such as radiation therapy, chemotherapy, and immunology, to control disease. Although research is preliminary, cryosurgery is fast becoming an alternative treatment method for HCC or liver tumors. Here, we review the mechanisms of liver tumor cryoablation, cryoablation program selection, clinical efficiency, and complications following treatment.

© 2014 The Second Affiliated Hospital of Chongqing Medical University. Published by XIA & HE Publishing Ltd. All rights reserved.

Introduction

Liver cancer can be divided into two groups based on the primary tumor site: (1) primary liver cancer (including hepatocellular carcinoma [HCC] and cholangiocarcinoma) and (2) metastatic cancer to the liver from a distant primary site. The most common type of adult primary liver cancer is HCC, which is usually discovered late in the disease course and generally has poor prognosis.¹ Although surgical resection (SR) is the best option for patients with HCC, only about 20–30% of patients are eligible for tumor resection at the time of diagnosis.^{2,3} Systemic chemotherapy does not significantly increase survival in patients with advanced

HCC.^{4,5} Some cancers; such as colorectal, breast, carcinoid, and pancreatic cancer, melanoma, and renal cell carcinoma, that can metastasize to the liver are generally associated with poor prognosis as well. Given the lack of treatment options for these patients, new locoregional and systemic therapies are needed. Cryoablation under the guidance of many imaging methods can induce iceball formation and tumor necrosis and is an attractive option for treating unresectable HCC and metastatic liver cancer. Cryoablation has many advantages, including ability to visualize the iceball,^{6,7} activation of cryo-immunology in cancer,⁸ lack of severe damage to large blood vessels,⁹ and no causation of severe pain.¹⁰ With the emergence of argon–helium cryoablation units, percutaneous cryosurgery (PC) is becoming a main treatment method in the field of cancer cryosurgery. The present review describes the mechanisms of liver tumor cryoablation, percutaneous cryoablation program selection, clinical efficiency, and the side effects associated with treatment.

Mechanisms of tissue injury

Currently, two different argon-based cryoablation units are used in the clinical setting: the CRYO care System (EndoCare, Irvine, CA, USA) and Cryohit (Galil Medical, Yokneam, Israel). When high-pressure argon gas is circulated through the lumen of a cryoprobe, the temperature drops to $-160\text{ }^{\circ}\text{C}$ and an iceball forms at the tip of the probe. The iceball is thawed when helium gas is circulated through the probe lumen. This freezing and thawing process induces direct and indirect cell damage, causing tumor cell death. When the temperature drops during the freezing process, ice crystals form inside and outside the cell, osmotic pressure increases inside the cell, cell dehydration occurs, and the cell membrane is damaged.¹¹ Organelles, such as the mitochondria and endoplasmic reticulum, are irreversibly damaged, eventually leading to cell death. During the thawing process, recrystallization or the mutual confluence of tiny ice crystals leads to the formation of large ice crystals, which induce more damage to the cell. Extracellular water re-enters the cell at this stage, causing the cell to swell, eventually leading to more cell membrane damage. If the temperature of the frozen tissue is not sufficiently decreased, not all tumor cells will be killed despite apoptosis as the main form of cell death.¹² Since apoptosis does not guarantee the elimination of all target cells, incomplete tumor cell death will likely lead to tumor recurrence.

Cryosurgery is indirectly linked to tumor cell death by promoting arteriovenous injury via the formation of micro- and small arteriovenous ice crystals that cause vascular endothelial damage, increased vascular wall permeability,

Keywords: Cryosurgery; Hepatocellular carcinoma; Metastatic disease; Efficacy.
Abbreviations: AFP, alpha-fetoprotein; CIK, cytokine-induced killer; CT, computed tomography; DCH, dendritic cells; HCC, hepatocellular carcinoma; MRI, magnetic resonance imaging; OS, overall survival; PC, percutaneous cryosurgery; SR, surgical resection; TACE, transarterial chemoembolization; US, ultrasound.

Received: 22 May 2014; Revised: 15 June 2014; Accepted: 27 June 2014

* DOI: 10.14218/JCTH.2014.00017.

*Correspondence to: Kecheng Xu, No.2 of Tangde West Rd, Tianhe District, Guangzhou, China. Tel: +86-020-38993994-8700, Fax: +86-020-38993994-8700, Email: fudaclab@gmail.com

intravascular fluid extravasation, and interstitial edema.¹³ Platelet aggregation, thrombosis, and eventual occlusion of blood flow also cause tumor tissue ischemia and hypoxia, which induces tumor cell death. The flow of blood in micro- and small arteries is three times faster than that of intravenous blood, and blood flow influences ice crystal formation. In the first freezing cycle, circulation of micro- and small arteries of the frozen area recovers 10~20 min after thawing. In the second freezing cycle, micro- and small artery blood flow does not recover, whereas the circulation in large arteries recovers within 24 hours after cryosurgery.¹⁴⁻¹⁷ After repeated freezing and thawing, cell rupture, cell membrane dissolution, and cell antigen release, the cryo-immunological response is triggered^{8,18} and the anti-tumor immune response that targets additional tumor cells is induced.¹⁹

Cryoablation program selection

Several factors influence the effect of freezing, including freezing temperature, freezing time, thawing, and freezing time cycle number.²⁰ First, the freezing time controls the size of the iceball, which increases as freezing time increases until a dynamic balance of cold/heat exchange is achieved. As iceball formation can be visualized with ultrasound (US), computed tomography (CT), and magnetic resonance imaging (MRI),²⁰⁻²² it can be monitored accurately to ensure complete ablation. Second, the freezing temperature influences the effect of the cryosurgery. The temperature at the margin of the iceball is 0 °C, a temperature at which tumor cells can survive. Five mm inside the edge of the iceball, the temperature is approximately -20 °C to -50 °C, and tumor cells can be killed. Therefore, in order to achieve complete ablation of tumor tissue, the edge of the iceball must exceed that of the tumor by 1 cm.²³ Third, thawing and cycle times will affect the degree of necrosis,¹² where a longer thawing time leads to more tissue necrosis.¹¹ Whittaker²⁴ noted that thawing time will affect iceball formation, where large-scale intracellular ice crystals will form after the second freeze cycle. Repeated freezing cycles will increase the size of the iceball,^{14,25,26} and the degree and area of permanent tissue

necrosis caused by the iceball spreads outward as freezing cycles increase, thereby increasing the area of frozen necrosis.^{27,28} Since their freezing times are the same (20 min), the triple-freeze protocol may be a more powerful liver ablation method than the dual-freeze protocol demonstrated in a Tibetan pig model.²⁸

As a single probe causes a smaller range of damage, more than two freezing probes are used for tumors exceeding 3 cm to increase the effective freezing range.²⁹ Hinshaw and Lee²³ reported that if there are no great vessels around the tumor, the best cryoprobe placement is two needles not greater than 2 cm apart within 1 cm of the edge of the tumor. If there is a large vessel adjacent to one of the tumor borders, the cryoprobes should be positioned closer to the vessel and more closely apposed, as "heat sink" has a critically important effect on isotherm size and shape. If there are multiple large blood vessels around the tumor, it is best to place the two cryoprobes less than 1 cm apart, 5 mm from the edge of the tumor.²³

Altogether, the efficacy of cryosurgery is affected by argon flow to specific probes, the cryoablation program, and multiple probe selection. For liver cryosurgery, different cryoablation programs are carried out to ablate different lesions or lesions in different locations.

Clinical research (summarized in Table 1)

In this decade, PC is the main therapeutic intervention for the treatment of unresectable HCC. In 2003, Xu *et al.*⁴⁴ reported the use of PC in 105 masses from 65 patients with HCC. Among 41 patients who were followed for more than 1 year; 32 (78%) were alive despite tumor recurrence, seven patients (10.8%) died due to disease recurrence, and three patients (5%) died of non-cancer-related diseases (Fig. 1). In a study of four patients with small HCC who underwent one PC with multiple 17-G cryoprobes, it was determined that this percutaneous technique, and not the laparotomic approach, should be applied for unresectable HCC.³⁰ In 300 cases of HCC, the therapeutic effect, safety, and complications of PC were evaluated, and the mean survival (months) of early-, intermediate-, and advanced-stage patients was 38.7 ± 3.8,

Table 1. Survival rates of patients after cryosurgery of hepatic tumors

	Tumor type	Therapy type	Patients	1 year survival rate (%)	2 year survival rate (%)	3 year survival rate (%)	4 year survival rate (%)	5 year survival rate (%)
Zhou <i>et al.</i> ³²⁻³³	HCC	CRY	48	81.3	62.1	47.6	44.4	-
Chen <i>et al.</i> ²⁰	HCC	CRY	-	81.4	-	60.3	-	-
Li <i>et al.</i> ³⁶	SHCC	CRY	-	100.0	-	77.6	70.7	-
Xu <i>et al.</i> ³⁷	Colorectal liver metastases	CRY	326	78.0	62.0	41.0	34.0	23.0
Qian <i>et al.</i> ³⁸	Metastatic liver malignancy	CRY	22	81.8	22.7	-	-	-
Chen <i>et al.</i> ³⁹	Secondary Liver cancer	CRY	-	80.2	-	-	-	-
	Recurrent liver cancer	CRY	-	46.2	-	-	-	-
Han <i>et al.</i> ⁴⁰	HCC	CRY	116	85.7	64.3	32.1	-	-
Xu <i>et al.</i> ⁴²	HCC	CRY	420	73.0	54.0	-	49.0	39.0
	HCC	TACE+CRY	-	71.0	61.0	-	29.0	23.0

Note: SHCC, small HCC; CRY, cryotherapy

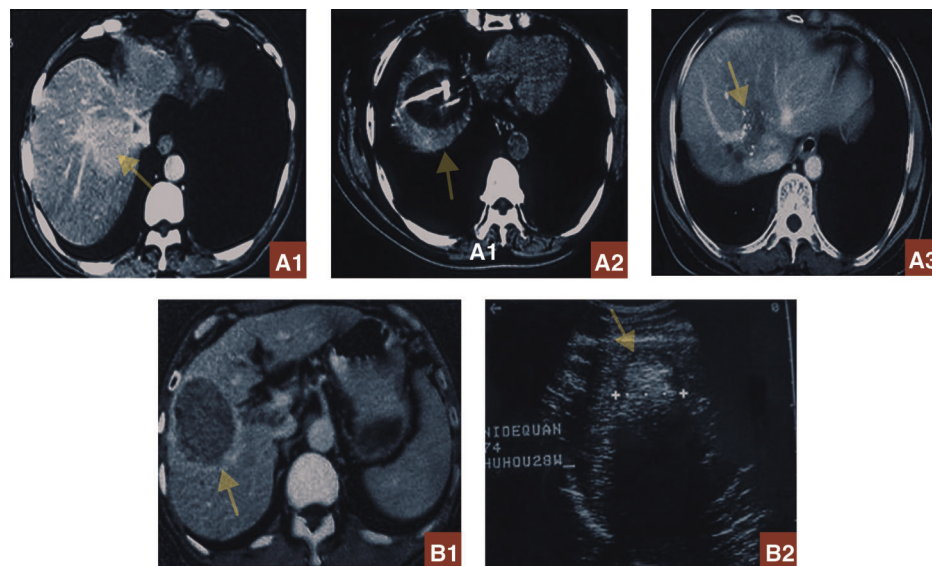


Fig. 1. CT images of two patients (A and B) with HCC who underwent PC. (A1) Space-occupying lesion in the upper right part of the liver. (A2) Cryoprobe placement and resultant iceball formation. (A3) No lesion five years after treatment. (B1) Space-occupying lesion measuring 73 × 62 mm before treatment. (B2) Ultrasonography showing shrinkage of the tumor to 42 × 40 mm. Arrows indicate the tumor site.

26.5 ± 4.2, and 16.9 ± 1.4, respectively.³¹ There were serious complications in 17 patients (6%), including six with cold shock (2%), five with bleeding due to tumor rupture (2%), four with bleeding from stress gastric ulcer (1%), and two with liver failure (1%). In another study, the clinical effectiveness of percutaneous cryosurgical ablation for treating 48 patients with early-stage HCC was evaluated, and it was found that the 1, 2, 3, and 4 year survival rates were 81%, 62%, 48%, and 44%, respectively.^{32,33} In a series of 124 unresectable HCC cases, serum alpha-fetoprotein (AFP) levels were reduced in 76 patients (83%), and 205 of the 222 tumors (92%) diminished or were unchanged after cryoablation. The median survival time was 31.3, 17.4, and 6.8 months in the early-, intermediate-, and advanced-stage groups, respectively. In eight patients with primary or secondary small HCC (≤5 cm) after PC, six patients became AFP negative with a coagulation necrosis rate of 63%, and the 6 month and 1 year local recurrence-free survival rates were 100% and 88%, respectively.³⁴ Zhang investigated 227 patients with different stages of HCC treated with PC and found that advanced HCC was most sensitive to cryosurgery and that survival was significantly prolonged.³⁵ Using PC to treat patients with unresectable HCC, Chen *et al.*²⁰ found that the 1 and 3 year overall survival (OS) rates were 81%, and 60%, respectively, while the 1 and 3 year disease-free survival rates were 68% and 21%, respectively. The 1 and 3 year OS rates of patients with recurrent HCC were 70% and 29%, respectively, while the 1 and 3 year disease-free survival rates were 54% and 8%, respectively. When the therapeutic effect of PC and SR of small HCC were compared, it was found that the respective 1, 3, and 5 year OS rates of the PC and SR groups were 100%, 75%, and 67%, and 100%, 78%, and 71%.³⁶ The respective 1, 3, and 5 year recurrence-free survival rates of the PC and SR group were 83%, 46%, and 29%, and 84%, 48%, and 33%. These results suggested that PC is as effective as SR for treating solitary small HCC even though it is less invasive, requires a

shorter hospitalization time, and less expensive than SR. Overall, these data demonstrate that PC is a viable treatment option for HCC.

Similar to its use in primary liver cancer, cryosurgery also is advantageous for the treatment of metastatic liver cancer. In 326 patients with non-resectable hepatic colorectal metastases, 526 procedures of cryosurgery under US or CT guidance were performed.³⁷ Three months after cryosurgery, the elevated carcinoembryonic antigen levels in 78% of patients were restored to normal levels. Postoperative CT scan of the cryotreated lesions showed complete response in 15% of patients, partial response in 41% of patients, and stable disease in 24% of patients. The 1, 2, 3, 4, and 5 year OS rates after the treatment were 78%, 62%, 41%, 34%, and 23%, respectively (Fig. 2). In 2005, Qian and colleagues³⁸ reported survival rates of 22 patients with histologically or clinically confirmed metastatic liver malignancy treated with PC. The 12, 18, and 24 month survival rates were 82%, 64%, and 23%, respectively. Chen *et al.*³⁹ reported that the 1 year survival rates of secondary and recurrent liver cancer patients treated with cryosurgery were 80% and 46%, respectively. In another study, 116 patients with unresectable HCC were divided into three groups: (A) interventional therapy, (B) 3-dimensional conformal radiotherapy, and (C) cryoablation therapy. The respective 1, 2, and 3 year survival rates in the A, B, and C groups were 15%, 64%, and 86%; 11%, 32%, and 64%; and 0%, 0%, and 32%. Taken together, these data suggest that PC is an acceptable new locoregional therapy for metastatic liver cancer.

In order to optimize treatment strategies for liver cancer, cryoablation is often combined with other therapies, such as transarterial chemoembolization (TACE). Between July 2001 and June 2002, Qian *et al.*⁴¹ assessed the indications, efficacy, and clinical significance of PC following TACE in 34 patients with histologically or clinically confirmed primary or metastatic carcinoma. During the 3–15 month follow-up

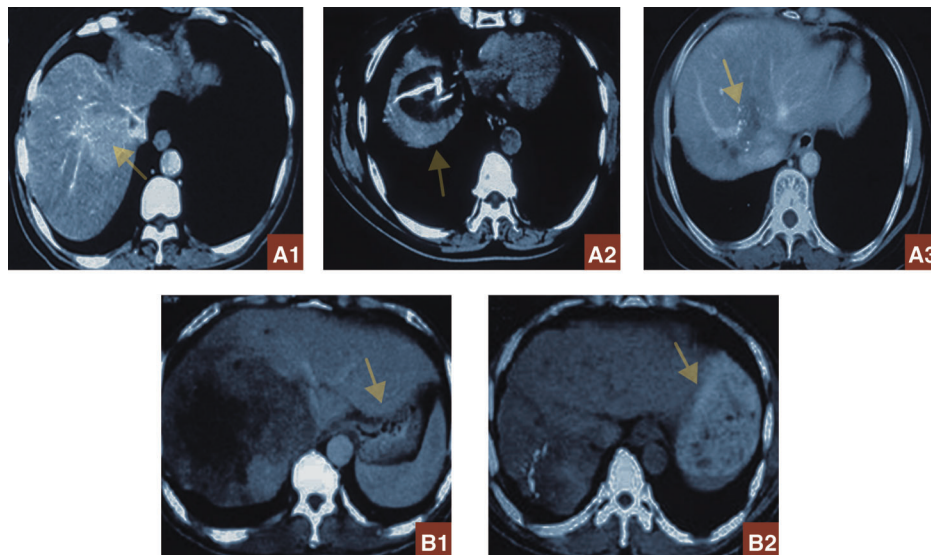


Fig. 2. Liver imaging in two patients (A and B) with hepatic colorectal metastases. Complete ablation of histologically proven tumor was achieved after PC. (A1) MRI before cryosurgery. (A2) MRI during CT-guided PC. (A3) MRI at 12 months after cryosurgery. In the second patient, the massive lesion regressed completely in comparison to its size before cryosurgery (B1). (B2) Eight months after cryosurgery and TACE. Arrows indicate the tumor site.

period, 41% of patients were classified as clinically cured or effectively treated because their serum tumor markers were normal, or CT and MRI images revealed that the lesion had become completely necrotic. In a study on the use of sequential TACE and PC for treatment of unresectable HCC, the 1 and 2 year survival rates in the sequential group (71% and 61%, respectively) were similar to that of the cryo-alone group (73% and 54%, respectively). The 4 and 5 year survival rates of the sequential group were 49% and 39%, respectively, which were higher than that of the cryo-alone group (29% and 23%, respectively). While 18 patients with large HCC (>5 cm diameter) survived for more than 5 years after sequential TACE and cryosurgery, no patient in this category survived more than five years with cryosurgery alone. The authors suggested that pre-cryosurgical TACE may increase the efficacy of cryoablation and decrease its adverse effects, especially bleeding. Therefore, sequential TACE and cryosurgery may be a better therapeutic option for unresectable HCC, especially large HCC. In another study comparing PC followed by TACE with TACE alone for advanced liver cancer, the rate of effectiveness of the combined group was 100% and only 47% in the TACE alone group.⁴³ When determining the effect of order for combination cryosurgery and TACE in 40 patients with advanced primary hepatic carcinoma, about half of patients exhibited complete tumor necrosis, and there was no significant difference between the TACE/sequential cryosurgery and cryosurgery/sequential TACE groups.⁴⁴ However, progression-free survival in the TACE/sequential cryosurgery group was significantly longer than that of the cryosurgery/sequential TACE group. Regarding combining cryoablation with gemcitabine + oxaliplatin for the treatment of advanced liver cancer, combination therapy was found to be more efficacious, reliable and safe than monotherapy.⁴⁵

In a study with combination hepatic PC and percutaneous ethanol injection for unresectable HCC, 33 patients (51%) were tumor-free and 22 patients (34%) were alive with tumor

recurrence during a mean follow-up period of 14 months (range 5–21 months). As cryoablation of tumors in multiple organs (i.e., liver, lung, kidney, breast, pancreas, and prostate⁴⁷) has been demonstrated to be safe and effective, comprehensive cryoablation (simultaneous cryoablation of intrahepatic and extrahepatic tumors) significantly improves the survival of metastatic hepatocellular cancer, and timely or multiple treatments may both contribute more towards the therapeutic effects than delayed or single treatment.⁴⁸ Although cryosurgery can induce a cryo-immunological response,^{8,19} the anti-tumor immune response is insufficiently strong to prolong patient life. At the same time, immunotherapy mediated by autologous dendritic cells (DCs) is a promising treatment option for the long-lasting control of unresectable HCC.^{49–51} Increased knowledge of vaccination using DCs co-cultured with cytokine-induced killer (CIK) cells has led to the formulation of better strategies in the clinical treatment of hepatic cancer.⁵² Combining these approaches, Niu *et al.*⁵³ evaluated whether combination PC and DC-CIK immunotherapy can improve the therapeutic effect of cryosurgery for patients with metastatic hepatocellular cancer. To stimulate DC recognition of tumor antigens *in vivo*, harvested DC-CIKs were transfused into patients one week after cryosurgery. The median OS of the cryo-DC-CIK immunotherapy group (32 months) was higher than that of the cryotherapy group (18 months) and the untreated group (3 months), and multiple cryo-immunotherapy was associated with better prognosis than single cryo-immunotherapy.⁵³ Perhaps cryosurgery induces continuous antigen release *in vivo*, and the adoptive transfer of CIK cells along with DCs can present tumor antigens and destroy tumor cells in the body. Another advantage of cryosurgery is the destruction of the organ-like structural environment of a tumor, which is considered hostile toward immune cells. Altogether, it appears that PC and DC-CIK immunotherapy may be an alternative therapeutic option for improving survival in metastatic hepatocellular cancer.

Table 2. Serious complications after hepatic cryoablation

Tumor type	Yang <i>et al.</i> ⁵⁶	Xu <i>et al.</i> ³⁷	Mu <i>et al.</i> ⁴⁸
	HCC	Colorectal liver metastases	Metastatic hepatocellular cancer
Number of patients	300	326	33
Cryoshock syndrome	6 (2.0%)	1 (0.3%)	-
Bleeding	5 (1.6%)	5 (1.5%)	6 (18.0%)
Liver abscess	2 (0.6%)	3 (0.9%)	2 (6.0%)
Liver failure	2 (0.6%)	1 (0.3%)	-
Liver dysfunction	7 (2.3%)	-	-
Biliary fistulas	-	3 (0.9%)	-
Intestinal fistulas	1 (0.3%)	-	-
Renal insufficiency	-	5 (1.5%)	-
Acute myocardial infarction and severe arrhythmia	6 (2%)	2 (0.6%)	-
Pain	-	103 (31.6%)	13 (76.0%)
Fever	6 (2%)	108 (33.1%)	-
Increased liver enzymes	-	124 (38.0%)	-
Thrombocytopenia	-	58 (17.8%)	7 (21.0%)
Pleural effusion	-	20 (6.1%)	2 (6.0%)
Liver capsular cracking	1 (0.3%)	-	1 (3.0%)
Gastric mucosal lesion-induced hemorrhage	4 (1.3%)	-	-

Adverse effects (summarized in Table 2)

Adverse effects of varying degrees of severity during and after hepatic cryoablation have been documented. In liquid nitrogen ablation, the frequency of adverse effects may be as high as 40% and include liver parenchyma fracture, cryoshock, acute myocardial infarction, biliary fistula, hemorrhage, cold-induced lesions in nearby structures, thrombocytopenia, and coagulopathy.^{54,55} Hepatic cryoablation-related mortality is 1.5%,⁵⁶ almost the same as that for liver resection. There are relatively fewer and milder adverse effects associated with percutaneous cryoablation than liquid nitrogen cryoablation. Serious complications, including hepatic failure, rupture, and cold shock, are occasionally observed after the procedure.^{37,48}

In one study of 300 HCC patients who underwent US-guided PC, 6% developed serious complications, including cryoshock syndrome in six patients, hepatic bleeding in five, stress-induced gastric bleeding in four, liver abscess in one, intestinal fistulas in one, and death due to liver failure in two.⁵⁷ Cold shock, a rare and serious complication of hepatic cryoablation, has garnered much attention from clinical researchers. The clinical features of cold shock include varying degrees of renal failure, disseminated intravascular coagulation, and adult respiratory distress syndrome. Its occurrence is proportional to the size of the frozen tissue, and often happens when the diameter of the area frozen exceeds 6 cm.⁵⁸

Alternatively, freezing time rather than frozen area may be much more important for the occurrence of cold shock.⁵⁹ Another potentially serious complication that can lead to death is an argon-helium gas embolism.⁶⁰ Minor complications due to PC are chills, fever, hepatic region pain, and elevated serum enzymes, which can be efficiently controlled with symptomatic treatment.^{37,48} Coagulopathy, another

complication of hepatic cryoablation, occurs due to the trapping and destruction of local platelets within the margin of the cryolesion.⁶¹⁻⁶³ The development of thrombocytopenia is associated with increased length of stay and mortality.⁶⁴⁻⁶⁶ Although thrombocytopenia is considered relative to the volume of frozen tissue,^{63,67} the number of freeze-thaw cycles, and the number of cryoprobes,⁶⁸ Shi *et al.*⁶⁹ showed that the diameter of the ablation does not limit the tendency of platelets to change. Slight coagulopathy (platelet count $[70-100] \times 10^9/L$) can recover naturally within a week, and recombinant human interleukin-11 can assist recovery from severe coagulopathy (platelet count $< 70 \times 10^9/L$).⁶⁹ At the same time, PC of hepatic tumors may cause short-term pain in some patients, which disappears within 15 days, and the effect of alleviating cancer pain is sustained for >8 weeks without severe side effects.⁷⁰ Tumor seeding can be detected in 0.8% of patients at 1-24 months (median, 6 months) after cryoablation.^{71,72}

Therefore, monitoring liver function and detecting blood coagulation and renal function are very important before or after hepatic cryoablation. Cryosurgery program selection, accuracy of preoperative localization, and the frozen range all can affect the occurrence of complications. To avoid serious complications, all patients should be given diuretics and mannitol, and their urine alkalized to prevent myoglobinuria and renal injury.

Conclusions

Experimental and clinical applications have shown that hepatic cryosurgery is safe and efficacious. Iceball formation can be monitored visually, and cryoablation has little impact on nearby large blood vessels. Cryosurgery can be performed on its own or in combination with other methods, such as radiation therapy, chemotherapy, immunology, or surgery, to

control disease. In the future, the safety and efficacy of hepatic cryosurgery in specific areas of the liver lobe close to the diaphragm and gall bladder should be examined. Presently, there are several ablation techniques available for hepatic cancer, such as radiofrequency, microwave, irreversible electroporation, and cryosurgery. The ability to compare these techniques and to know which patients are the best candidates for each technique is of great importance. Simultaneously, optimizing therapeutic conditions to enhance the efficacy and safety of combination cryosurgery with other therapies requires further investigation.

Conflict of interest

None

Author contributions

Performing all the cryosurgeries (LZN), Writing the paper (JLL), Conducting and reviewing the article (KCX).

References

[1] Jemal A, Bray F, Center MM, Ferlay J, Ward E, Forman D. Global cancer statistics. *CA Cancer J Clin* 2011;61:69–90. doi: 10.3322/caac.20107.

[2] Hodgson HJ. Primary hepatocellular carcinoma. *Br J Hosp Med* 1983;29:240, 246, 250 passim.

[3] Dusheiko GM, Hobbs KE, Dick R, Burroughs AK. Treatment of small hepatocellular carcinomas. *Lancet* 1992;340:285–288. doi: 10.1016/0140-6736(92)92367-0.

[4] Burroughs A, Hochhauser D, Meyer T. Systemic treatment and liver transplantation for hepatocellular carcinoma: two ends of the therapeutic spectrum. *Lancet Oncol* 2004;5:409–418. doi: 10.1016/S1470-2045(04)01508-6.

[5] Llovet JM, Ricci S, Mazzaferro V, Hilgard P, Gane E, Blanc JF, *et al*. Sorafenib in advanced hepatocellular carcinoma. *N Engl J Med* 2008;359:378–390. doi: 10.1056/NEJMoa0708857.

[6] Littrup PJ, Ahmed A, Aoun HD, Noujaim DL, Harb T, Nakat S, *et al*. CT-guided percutaneous cryotherapy of renal masses. *J Vasc Interv Radiol* 2007;18:383–392. doi: 10.1016/j.jvir.2006.12.007.

[7] Littrup PJ, Freeman-Gibb L, Andea A, White M, Amerikia KC, Bouwman D, *et al*. Cryotherapy for breast fibroadenomas. *Radiology* 2005;234:63–72. doi: 10.1148/radiol.2341030931.

[8] Sabel MS. Cryo-immunology: a review of the literature and proposed mechanisms for stimulatory versus suppressive immune responses. *Cryobiology* 2009;58:1–11. doi: 10.1016/j.cryobiol.2008.10.126.

[9] Ladd AP, Rescorla FJ, Baust JG, Callahan M, Davis M, Grosfeld JL. Cryosurgical effects on growing vessels. *Am Surg* 1999;65:677–682.

[10] Arciero CA, Sigurdson ER. Liver-directed therapies for patients with primary liver cancer and hepatic metastases. *Curr Treat Options Oncol* 2006;7:399–409. doi: 10.1007/s11864-006-0008-7.

[11] Gage AA, Baust J. Mechanisms of tissue injury in cryosurgery. *Cryobiology* 1998;37:171–186. doi: 10.1006/cryo.1998.2115.

[12] Hanai A, Yang WL, Ravikummar TS. Induction of apoptosis in human colon carcinoma cells HT29 by sublethal cryo-injury: mediation by cytochrome c release. *Int J Cancer* 2001;93:526–533. doi: 10.1002/ijc.1359.

[13] Mazur P. Freezing of living cells: mechanisms and implications. *Am J Physiol* 1984;247:C125–142.

[14] Hoffmann NE, Bischof JC. The cryobiology of cryosurgical injury. *Urology* 2002;60:40–49. doi: 10.1016/S0090-4295(02)01683-7.

[15] Irimia D, Karlsson JO. Kinetics of intracellular ice formation in one-dimensional arrays of interacting biological cells. *Biophys J* 2005;88:647–660. doi: 10.1529/biophysj.104.048355.

[16] Eggstein S, Neeff H, Szarzynski M, Jungraithmayr W, Haberstroh J, Kirste G, *et al*. Hepatic cryotherapy involving the vena cava. Experimental study in a pig liver model. *Eur Surg Res* 2003;35:67–74. doi: 10.1159/000069398.

[17] Gage AA, Fazekas G, Riley EE Jr. Freezing injury to large blood vessels in dogs. With comments on the effect of experimental freezing of bile ducts. *Surgery* 1967;61:748–754.

[18] Hoffmann NE, Coad JE, Huot CS, Swanlund DJ, Bischof JC. Investigation of the mechanism and the effect of cryoimmunology in the Copenhagen rat. *Cryobiology* 2001;42:59–68. doi: 10.1006/cryo.2001.2305.

[19] Rovere-Querini P, Manfredi AA. Tumor destruction and in situ delivery of antigen presenting cells promote anti-neoplastic immune responses: implications for the immunotherapy of pancreatic cancer. *JOP* 2004;5:308–314.

[20] Chen HW, Lai EC, Zhen ZJ, Cui WZ, Liao S, Lau WY. Ultrasound-guided percutaneous cryotherapy of hepatocellular carcinoma. *Int J Surg* 2011;9:188–191. doi: 10.1016/j.ijssu.2010.11.008.

[21] Lee FT Jr, Chosy SG, Littrup PJ, Warner TF, Kuhlman JE, Mahvi DM. CT-monitored percutaneous cryoablation in a pig liver model: pilot study. *Radiology* 1999;211:687–692. doi: 10.1148/radiology.211.3.r99jn29687.

[22] Silverman SG, Sun MR, Tuncali K, Morrison PR, van Sonnenberg E, Shankar S, *et al*. Three-dimensional assessment of MRI-guided percutaneous cryotherapy of liver metastases. *AJR Am J Roentgenol* 2004;183:707–712. doi: 10.2214/ajr.183.3.1830707.

[23] Hinshaw JL, Lee FT Jr. Cryoablation for liver cancer. *Tech Vasc Interv Radiol* 2007;10:47–57. doi: 10.1053/j.tvir.2007.08.005.

[24] Whittaker DK. Repeat freeze cycles in cryosurgery of oral tissues. *Br Dent J* 1975;139:459–465. doi: 10.1038/sj.bdj.4803667.

[25] Mala T, Edwin B, Tillung T, Kristian Hol P, Soreide O, Gladhaug I. Percutaneous cryoablation of colorectal liver metastases: potentiated by two consecutive freeze-thaw cycles. *Cryobiology* 2003;46:99–102. doi: 10.1016/S0011-2240(02)00163-3.

[26] Rubinsky B, Lee CY, Bastacky J, Onik G. The process of freezing and the mechanism of damage during hepatic cryosurgery. *Cryobiology* 1990;27:85–97. doi: 10.1016/0011-2240(90)90055-9.

[27] Dilley AV, Dy DY, Warlters A, Copeland S, Gillies AE, Morris RW, *et al*. Laboratory and animal model evaluation of the Cryotech LCS 2000 in hepatic cryotherapy. *Cryobiology* 1993;30:74–85. doi: 10.1006/cryo.1993.1007.

[28] Li J, Chen J, Zhou L, Zeng J, Yao F, Wu B, *et al*. Comparison of dual- and triple-freeze protocols for hepatic cryoablation in a Tibet pig model. *Cryobiology* 2012;65:68–71. doi: 10.1016/j.cryobiol.2012.04.004.

[29] Bilchik AJ, Wood TF, Allegra D, Tsioulis GJ, Chung M, Rose DM, *et al*. Cryosurgical ablation and radiofrequency ablation for unresectable hepatic malignant neoplasms: a proposed algorithm. *Arch Surg* 2000;135:657–662; discussion 662–654. doi: 10.1001/archsurg.135.6.657.

[30] Orlicchio A, Bazzocchi G, Pastorelli D, Bolacchi F, Angelico M, Almerighi C, *et al*. Percutaneous cryoablation of small hepatocellular carcinoma with US guidance and CT monitoring: initial experience. *Cardiovasc Intervent Radiol* 2008;31:587–594. doi: 10.1007/s00270-008-9293-9.

[31] Wang CP, Lu YY, Wang XZ. Percutaneous argon-helium cryoablation for primary hepatocellular carcinoma: report of 300 cases. *Jie Fang Jun Yi Xue Za Zhi* 2008;33:1413–1417.

[32] Zhou H, Niu L, Zhou L, Mu F, Zhang C, Liang B, *et al*. Cryosurgery combined with Iodine-125 seed implantation in the treatment of unresectable lung cancer. *Zhongguo Fei Ai Za Zhi* 2008;11:780–783.

[33] Zhou L, Yang YP, Feng YY. Efficacy of argon-helium cryosurgical ablation on primary hepatocellular carcinoma: a pilot clinical study. *Ai Zheng* 2009;28:45–48.

[34] Qian GJ, Wang N, Wu SP. Percutaneous cryoablation for liver cancer located in the second hepatic. *Gan Dan Wai Ke Za Zhi* 2008;16:334–336.

[35] Zhang MN, Lu YY, Wang XZ. Clinical study of argon-helium cryosurgical ablation in the treatment for hepatocellular carcinoma. *Zhongguo Zhong Liu* 2009;18:329–331.

[36] Li Z, Zhang C, Lou C, Yan F, Mao Y, Hong X, *et al*. Comparison of percutaneous cryosurgery and surgical resection for the treatment of small hepatocellular carcinoma. *Oncol Lett* 2013;6:239–245. doi: 10.3892/ol.2013.1314.

[37] Chen HW, Cui WZ, Zhang HX. Ultrasound-guided minimally invasive targeting argon-helium cryoablation in the treatment of hepatic carcinoma. *Zhongguo Shi Yong Wai Ke Za Zhi* 2008;28:637–646.

[38] Han L, Wen XP, Wang WL. Clinical study on interventional therapy, three-dimensional conformal radiotherapy and targeted argon-helium cryoablation to primary hepatocellular carcinoma. *Guizhou Yi Yao* 2010;34:687–690.

[39] Qian GJ, Chen H, Wu MC. Percutaneous cryoablation after chemoembolization of liver carcinoma: report of 34 cases. *Hepatobiliary Pancreat Dis Int* 2003;2:520–524.

[40] Xu KC, Niu LZ, Zhou Q, Hu YZ, Guo DH, Liu ZP, *et al*. Sequential use of transarterial chemoembolization and percutaneous cryosurgery for hepatocellular carcinoma. *World J Gastroenterol* 2009;15:3664–3669.

[41] Shen XW, Feng J, Sun XG. Argon-helium cryosurgery combined with transcatheter arterial chemoembolization for treatment of liver metastatic tumors: an analysis of therapeutic results. *Jie Ru Fang She Xue Za Zhi* 2010;19:35–37.

[42] Cao Y, Zhao D, Wang Y. Clinical observation of cryosurgery with TACE by different order on the survival of advanced primary hepatic carcinoma. *Chin J Mod Drug Appl* 2013;7:9–11.

[43] Bai GD, Lian ZP, Huang DP. Cryoablation combined with chemotherapy in the treatment of advanced primary liver cancer. *Dang Dai Yi Xue* 2010;16:293–295.

[44] Xu KC, Niu LZ, He WB, Guo ZQ, Hu YZ, Zuo JS. Percutaneous cryoablation in combination with ethanol injection for unresectable hepatocellular carcinoma. *World J Gastroenterol* 2003;9:2686–2689.

- [45] Gage AA, Baust JM, Baust JG. Experimental cryosurgery investigations in vivo. *Cryobiology* 2009;59:229–243. doi: 10.1016/j.cryobiol.2009.10.001.
- [46] Mu F, Niu L, Li H, Liao M, Li L, Liu C, *et al*. Percutaneous comprehensive cryoablation for metastatic hepatocellular cancer. *Cryobiology* 2013;66:76–80. doi: 10.1016/j.cryobiol.2012.11.008.
- [47] Palmer DH, Midgley RS, Mirza N, Torr EE, Ahmed F, Steele JC, *et al*. A phase II study of adoptive immunotherapy using dendritic cells pulsed with tumor lysate in patients with hepatocellular carcinoma. *Hepatology* 2009;49:124–132. doi: 10.1002/hep.22626.
- [48] Lee WC, Wang HC, Hung CF, Huang PF, Lia CR, Chen MF. Vaccination of advanced hepatocellular carcinoma patients with tumor lysate-pulsed dendritic cells: a clinical trial. *J Immunother* 2005;28:496–504. doi: 10.1097/01.cji.0000171291.72039.e2.
- [49] Iwashita Y, Tahara K, Goto S, Sasaki A, Kai S, Seike M, *et al*. A phase I study of autologous dendritic cell-based immunotherapy for patients with unresectable primary liver cancer. *Cancer Immunol Immunother* 2003;52:155–161. doi: 10.1007/s00262-002-0360-9.
- [50] Thanendrarajan S, Nowak M, Abken H, Schmidt-Wolf IG. Combining cytokine-induced killer cells with vaccination in cancer immunotherapy: more than one plus one? *Leuk Res* 2011;35:1136–1142. doi: 10.1016/j.leukres.2011.05.005.
- [51] Niu LZ, Li JL, Zeng JY, Mu F, Liao MT, Yao F, *et al*. Combination treatment with comprehensive cryoablation and immunotherapy in metastatic hepatocellular cancer. *World J Gastroenterol* 2013;19:3473–3480. doi: 10.1097/MPA.0b013e3182965dde.
- [52] Mu F, Niu LZ, Li HB, Liao MQ, Li L, Liu Cy, *et al*. Percutaneous comprehensive cryoablation for metastatic hepatocellular cancer. *Cryobiology* 2013;66:76–80. doi: 10.1016/j.cryobiol.2012.11.008.
- [53] Niu LZ, Li JL, Zeng JY, Mu F, Liao MT, Yao F, *et al*. Combination treatment with comprehensive cryoablation and immunotherapy in metastatic hepatocellular cancer. *World J Gastroenterol* 2013;19:3473–3480.
- [54] Pearson AS, Izzo F, Fleming RY, Ellis LM, Delrio P, Roh MS, *et al*. Intraoperative radiofrequency ablation or cryoablation for hepatic malignancies. *Am J Surg* 1999;178:592–599.
- [55] Xu KC, Niu LZ, He WB, Hu YZ, Zuo JS. Percutaneous cryosurgery for the treatment of hepatic colorectal metastases. *World J Gastroenterol* 2008;14:1430–1436.
- [56] Yang Y, Wang C, Lu Y, Bai W, An L, Qu J, *et al*. Outcomes of ultrasound-guided percutaneous argon-helium cryoablation of hepatocellular carcinoma. *J Hepatobiliary Pancreat Sci* 2012;19:674–684. doi: 10.1007/s00534-011-0490-6.
- [57] Shafir M, Shapiro R, Sung M, Warner R, Sicular A, Klipfel A. Cryoablation of unresectable malignant liver tumors. *Am J Surg* 1996;171:27–31.
- [58] Wong WS, Patel SC, Cruz FS, Gala KV, Turner AF. Cryosurgery as a treatment for advanced stage hepatocellular carcinoma: results, complications, and alcohol ablation. *Cancer* 1998;82:1268–1278. doi: 10.1002/(SICI)1097-0142(19980401)82:7<1268::AID-CNCR9>3.0.CO;2-B.
- [59] Sandomirsky M, Crifasi JA, Long C, Mitchell EK. Case report of fatal complication in prostatic cryotherapy. First reported death due to argon gas emboli. *Am J Forensic Med Pathol* 2012;33:68–72. doi: 10.1097/PAF.0b013e3181dd5b8c.
- [60] Hamad GG, Neifeld JP. Biochemical, hematologic, and immunologic alterations following hepatic cryotherapy. *Semin Surg Oncol* 1998;14:122–128. doi: 10.1002/(SICI)1098-2388(199803)14:2<122::AID-SSU5>3.0.CO;2-7.
- [61] Kollmar O, Richter S, Czyborra J, Menger MD, Dietrich S, Schilling MK, *et al*. Aprotinin inhibits local platelet trapping and improves tissue destruction in hepatic cryosurgery. *Surgery* 2004;136:624–632. doi: 10.1016/j.surg.2004.02.004.
- [62] Pistorius GA, Alexander C, Krisch CM, Feifel G, Schilling MK, Menger MD. Local platelet trapping as the cause of thrombocytopenia after hepatic cryotherapy. *World J Surg* 2005;29:657–660; discussion 661. doi: 10.1007/s00268-005-7543-4.
- [63] Hui P, Cook DJ, Lim W, Fraser GA, Arnold DM. The frequency and clinical significance of thrombocytopenia complicating critical illness: a systematic review. *Chest* 2011;139:271–278. doi: 10.1378/chest.10-2243.
- [64] Nydam TL, Kashuk JL, Moore EE, Johnson JL, Burlew CC, Biffl WL, *et al*. Refractory postinjury thrombocytopenia is associated with multiple organ failure and adverse outcomes. *J Trauma* 2011;70:401–406; discussion 406–407. doi: 10.1097/TA.0b013e31820b5c85.
- [65] Olmez I, Zafar M, Shahid M, Amarillo S, Mansfield R. Analysis of significant decrease in platelet count and thrombocytopenia, graded according to NCI-CTC, as prognostic risk markers for mortality and morbidity. *J Pediatr Hematol Oncol* 2011;33:585–588. doi: 10.1097/MPH.0b013e318234622f.
- [66] Cozzi PJ, Stewart GJ, Morris DL. Thrombocytopenia after hepatic cryotherapy for colorectal metastases: correlates with hepatocellular injury. *World J Surg* 1994;18:774–776; discussion 777. doi: 10.1007/BF00298929.
- [67] Sarantou T, Bilchik A, Ramming KP. Complications of hepatic cryosurgery. *Semin Surg Oncol* 1998;14:156–162. doi: 10.1002/(SICI)1098-2388(199803)14:2<156::AID-SSU7>3.0.CO;2-4.
- [68] Shi J, Niu L, Huang Z, Mu F, Chen J, Li J, *et al*. Diagnosis and treatment of coagulopathy following percutaneous cryoablation of liver tumors: experience in 372 patients. *Cryobiology* 2013;67:146–150. doi: 10.1016/j.cryobiol.2013.06.004.
- [69] Long XA, Zeng JY, Niu LZ, Yao F, Wang XH, Chen JB, *et al*. Alleviating the pain of unresectable hepatic tumors by percutaneous cryoablation: Experience in 73 patients. *Cryobiology* 2013;67:369–373. doi: 10.1016/j.cryobiol.2013.10.005.
- [70] Wang CP, Wang H, Qu JH, Lu YY, Bai WL, Dong Z, *et al*. Tumour seeding after percutaneous cryoablation for hepatocellular carcinoma. *World J Gastroenterol* 2012;18:6587–6596.
- [71] Connors D, Rilling W. Pleural tumor seeding following percutaneous cryoablation of hepatocellular carcinoma. *Semin Intervent Radiol* 2011;28:258–260. doi: 10.1055/s-0031-1280677.